



ISSN: 0975-833X

RESEARCH ARTICLE

TOXIC POTENTIAL OF INHALATIONAL TRANSLUTHRIN INSECTICIDE ON DIFFERENT TISSUES IN ANIMAL MODEL

^{*}¹Himangshu Mahato, ²Vaswati Das, ¹Tanima Saha, ¹Swapan Kumar Dutta,
³Swati Bhattacharyya and ¹Supreeti Biswas

¹Department of Pharmacology, Burdwan Medical College & Hospital, India

²Department of Pathology, North Bengal Medical College, West Bengal, India

³Department of Pharmacology, R.G.Kar Medical College & Hospital, West Bengal, India

ARTICLE INFO

Article History:

Received 29th August, 2015

Received in revised form

26th September, 2015

Accepted 14th October, 2015

Published online 30th November, 2015

Key words:

Transfluthrin,
Inhalational mosquito repellent,
Pyrethroid insecticide,
Animal experiment.

ABSTRACT

Objective: Transfluthrin, an inhalational pyrethroid insecticide, commonly used in different kinds of mosquito repellents, (also acts against flying insects & various pests) has toxic potential. This study thus aimed at assessing the histopathological effects of transfluthrin exposure using the rat model.

Materials and Methods: Healthy adult male rats, 5 groups of 6 rats each were exposed to transfluthrin 0.88% w/w by inhalation at a rate of 8hours/day, for different durations, through common electronic mosquito repellent machine in a large stainless steel cage maintaining standard conditions. Trachea, lungs, liver, brain and kidney were dissected out at Day 2, 8, 15 and 22 and sent for histopathological examinations.

Results: Significant ballooning degeneration in hepatocytes and micro vesicular periportal fatty changes with inflammatory sparse were seen. Desquamative interstitial pneumonia found in lungs with mononuclear cell infiltration and peribroncheolar brown pigmentary deposits. Trachea shows loss of cilia, mucosal ulceration and sub mucosal lymphoid aggregations. Vascular congestion and haemorrhages were found in kidney with gliosis in brain tissue.

Conclusion: Transfluthrin have toxicological potential on liver, lung, trachea and kidney even after the use as per the directions given in package inserts. Government should re-evaluate the permissible dose of transfluthrin after consultation with proper authority.

Copyright © 2015 Himangshu Mahato et al. This is an open access article distributed under the Creative Commons Attribution License, which permits unrestricted use, distribution, and reproduction in any medium, provided the original work is properly cited.

Citation: Himangshu Mahato, Vaswati Das, Tanima Saha, Swapan Kumar Dutta, Swati Bhattacharyya and Supreeti Biswas, 2015. "Toxic potential of inhalational Transfluthrin insecticide on different tissues in animal model", *International Journal of Current Research*, 7, (11), 22554-22559.

INTRODUCTION

World Health Day on 7 April, 2014 called for greater vigilance and action in tackle a range of vector-borne diseases such as malaria, dengue, chikungunya, lymphatic filariasis and schistosomiasis. Vectors such as mosquitoes, ticks, mites, fleas, sand flies and freshwater snails are organisms that transmit dangerous parasites, viruses or bacteria from one infected animal or person to another, causing serious diseases in humans. In this 21st century era human beings are dealing with the deadliest vector born disease, none other than malaria and presently dengue, the world's fastest growing vector-borne disease, which also are spread by mosquitoes (WPRO (2014). Interesting fact is, the entire above diseases are related to a tiny 16mm insect, mosquito (Mosquito - Kill Mosquito Machine,

Attract mosquito for killed. Virginia (2007), the gift of rapid urbanisation, population outburst and high rise sky crappers to fulfil the increasing need of human beings.

Pyrethroids or synthetic pyrethroids are insecticides chemically similar to pyrethrins extracted from the flowers of chrysanthemum, known for centuries for their insecticidal activity (World health organization, 2005). Inhalational electronic mosquito repellent containing transfluthrin is a synthetic pyrethroid pesticide, widely used domestically to get rid of mosquitos, pests and various insects. Thereby its use has been increasing day by day due to high malaria burden in the Indian subtropics, resulting various health hazards and undesirable toxicities (World health organization, 2002). No specific antidotes to transfluthrin are still known (Information on the leaflet, (UPC Code: 8901157001143). There are so many researches already had been done upon pyrethroid insecticide and their toxicological evaluation through biochemical and haematological parameters, but still there is

***Corresponding author: Himangshu Mahato,**
Department of Pharmacology, Burdwan Medical College & Hospital,
India.

paucity on data regarding toxicological impact of pyrethroid insecticide specially transfluthrin on various body tissues. So, the present study was carried out to evaluate the extent of damage caused by inhalation of transfluthrin on various tissues of rat model.

MATERIALS AND METHODS

Experimental Animals: Thirty matured healthy albino male rats weighing between 100-150gm were taken from animal house after proper ethical clearance from Institutional Animal Ethics Committee. All rats were handled in accordance with the CPCSEA guidelines for care and use of laboratory animals. They were kept maintained under standard conditions with 12hour day/light cycle and allowed to acclimatize for two weeks before the commencement of the experiment (India. CPCSEA guidelines for laboratory animal facility, 2005). Rats were given food and water ad libitum.

Materials: Inhalational mosquito repellent (Transfluthrin 0.88% w/w) and its machine were purchased from local market nearby the institution. Large stainless steel cage were ordered from nearby hardware shop.

Experimental design: Thirty healthy male albino rats were randomly distributed into 5 groups of 6 rats each. All the rats were fed with ordinary food in standard quantity and ample water. Group-I represented the Control group (n=6): which inhaled atmospheric air. Rest four groups comprised of Treatment groups: which inhaled transfluthrin. Treatment groups were introduced to inhalational transfluthrin 0.88% w/w through common available electronic mosquito repellent machine at a rate of 8hours / day for a period of 24 hours for Group-II (n=6), 7 days for Group-III (n=6), 14 days for Group-IV (n=6) and 21 days for Group-V (n=6). Large stainless steel cage as per CPCSEA guidelines has been used for each five group separately (India. CPCSEA guidelines for laboratory animal facility, 2005). Control group inhaled only atmospheric air for 21 days following the same procedure as in Group-V; no inhalational mosquito repellent was used to them. Rats were sacrificed after above duration of exposure i.e. at day 2 after 24 hours of exposure, Day 8 after 1 week of exposure, Day 15 after 2 weeks of exposure, Day 22 after 3 weeks of exposure. Trachea, lungs, liver, kidney and brain were dissected out and formalin preserved tissues were sent to the Dept. of Pathology for histopathological examinations.

Preparation of histopathological slide

After completion of treatment period according to experimental design, the animals were anesthetized using Pentothal Sodium and sacrificed for tissue collection (Ghosh 2011). Trachea, lungs, liver, brain and kidney were dissected out and collected carefully from the rat using standard procedure. Fat tissues adhered to the organs were also removed carefully and organs were then fixed in 10% neutral buffer formalin for 24 hour and grossing had been done (Bancroft 2008). Followed by fixation, dehydration of the tissues was conducted by immersing the tissue in a series of gradually increasing concentrations of alcohol (50%, 70%, 80%, 95% and absolute alcohol) and embedded into paraffin wax for

making blocks. The block was trimmed by removing of wax from the surface of block to expose the tissue. Sectioning of the tissue was performed by using a microtome. The microtome was pre-set to cut the tissue as thicknesses around 5 microns (Bancroft 2008). Small ribbons of tissue sections were placed on microscopic slide with help of warm distil water containing few drops of Mayer's albumin and deparaffinised with xylene solution. Staining had been done by Harris haematoxylin & eosin yellow solution using standard procedure for preparing permanent slide (Bancroft 2008). Histopathological changes were observed and interpreted under 20x of a light microscope and representative sections were photographed.

RESULTS

Significant Histopathological observation under light microscopy showed the following results:

DAY 2

Group	Trachea	Lung	Liver	Kidney	Brain
1 (control)					
2	NO SIGNIFICANT CHANGES OBSERVED				
3					
4					
5					

DAY 8

Group	Trachea	Lung	Liver	Kidney	Brain
1 (control)		NO SIGNIFICANT CHANGES			
2	Mild surface ulceration (Fig.1&2)		Centrilobular congestion (Fig.3)		
3	Mild surface ulceration (Fig.1&2)				
4	Mild surface ulceration (Fig.1&2)		Centrilobular congestion (Fig.3)		
5	Mild surface ulceration (Fig.1&2)				

DAY 8

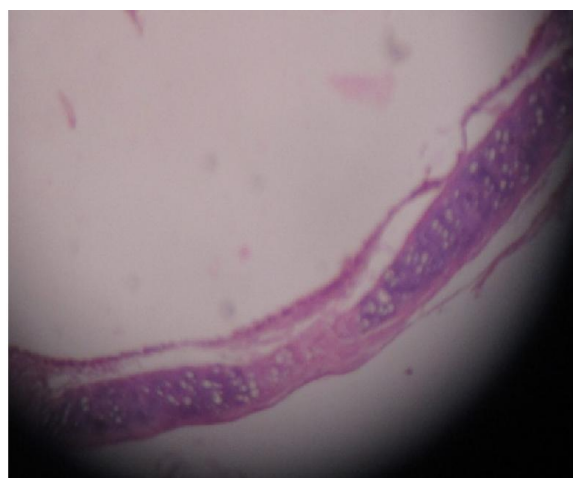


Fig.1 (Gr.III). Tracheal ulceration and denudation under light microscope (Harris haematoxylin & eosin stain)

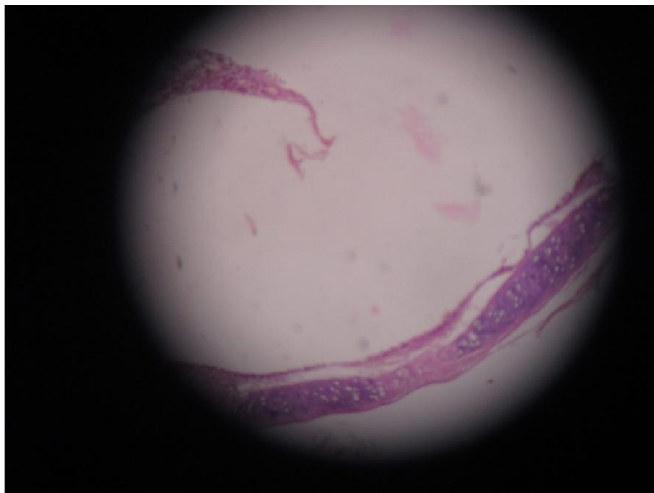


Fig.2 (Gr.III). Tracheal ulceration and denudation under light microscope (Harris haematoxylin & eosinstain)

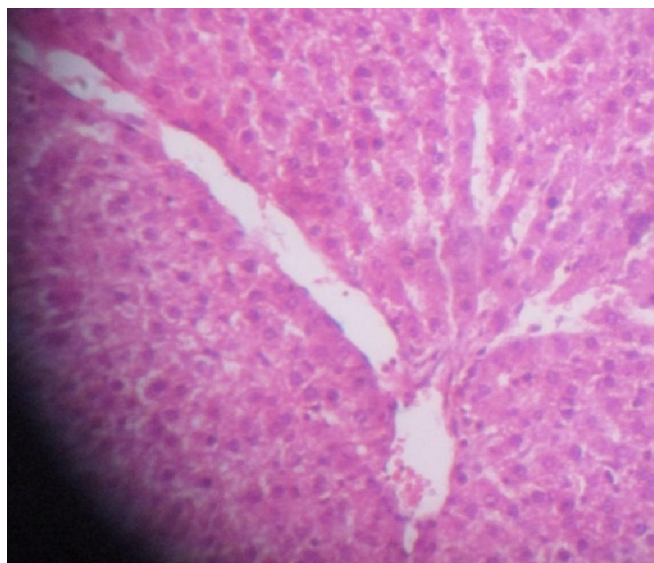


Fig.3 (Gr.III). Liver section shows centrilobular congestion on histopathology (Harris haematoxylin & eosinstain)

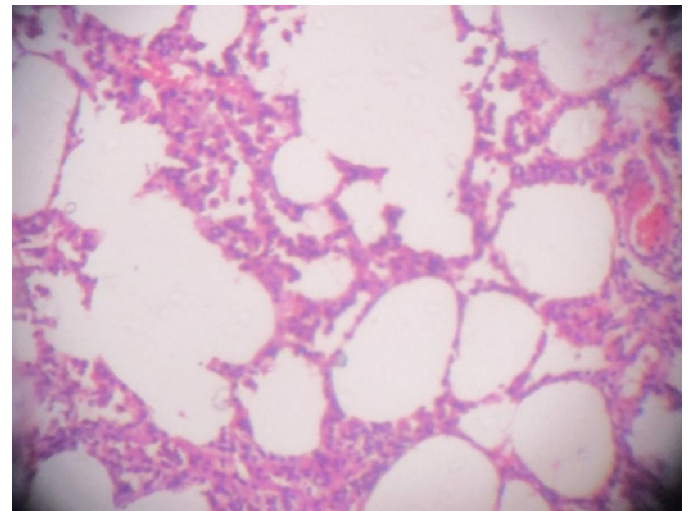


Fig.4. (Gr.IV): Lung section shows desquamated lung disease – patchy involvement on histopathology after 2nd week of inhalational transfluthrin exposure. (Harris haematoxylin & eosin stain under 20x)

DAY 22

Group	Trachea	Lung	Liver	Kidney	Brain
1 (control)	NO SIGNIFICANT CHANGES				
2	Sub-epithelial lymphoid aggregates (Fig.5&6)	Peri-bronchial intense chronic inflammatory infiltrate (Fig.7)	Extensive centrilobular congestion (Fig.11)		
3	Sub-epithelial lymphoid aggregates (Fig.5&6)	Desquamated Lung Disease – Patchy involvement (Fig.9)	Periportal micro vesicular steatosis (Fig.12)		
4	Sub-epithelial lymphoid aggregates (Fig.5&6)	Desquamation with pigmentation (Fig.10)	Centrilobular congestion (Fig.11)	Congestive changes (Fig.13)	Gliosis (Fig.14)
5	Sub-epithelial lymphoid aggregates (Fig.5&6)	Peri-bronchial intense chronic inflammatory infiltrate (Fig.8)			

DAY 15

Group	Trachea	Lung	Liver	Kidney	Brain
1 (control)	NO SIGNIFICANT CHANGES				
2	Mild surface ulceration (Fig. 1&2)	Desquamated Lung Disease – Patchy involvement (Fig. 4)	Centrilobular congestion (Fig.3)		
3	Mild surface ulceration (Fig. 1&2)				
4	Mild surface ulceration (Fig. 1&2)	Desquamated Lung Disease – Patchy involvement (Fig.4)	Centrilobular congestion (Fig.3)		
5	Mild surface ulceration (Fig. 1&2)	Desquamated Lung Disease – Patchy involvement (Fig. 4)			

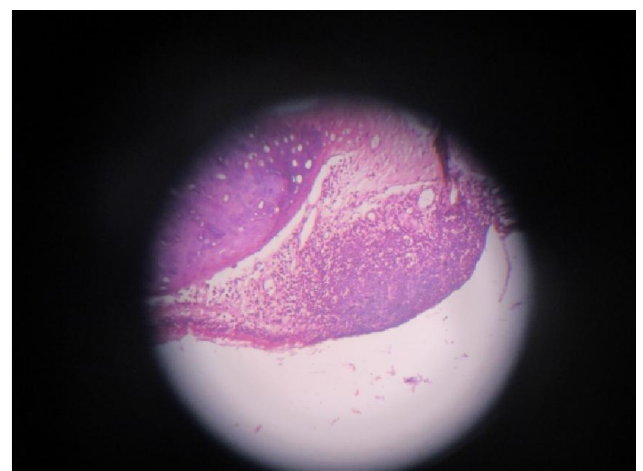


Fig. 5

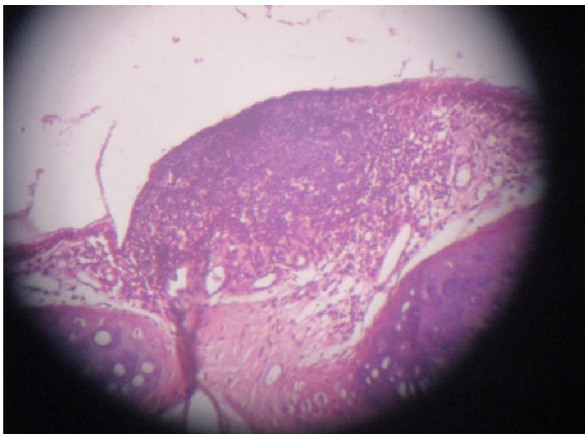


Fig. 6.

Fig.5 & Fig.6 (Gr.V). Trachea section shows sub-epithelial lymphoid aggregates under light microscope after 3rd week of transfluthrin inhalation. (Harris haematoxylin & eosin stain under 20x)

DAY 22

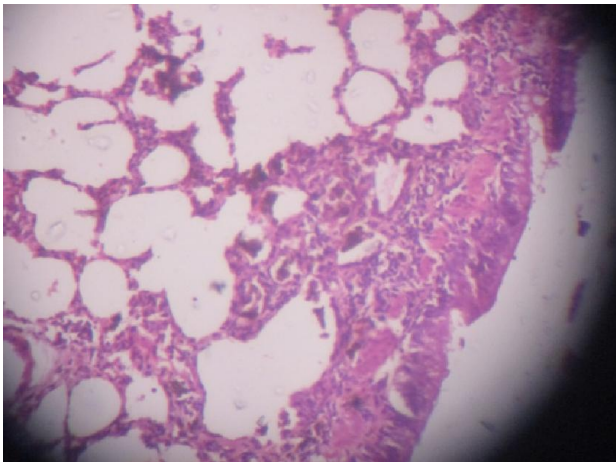


Fig.7 (Gr.V): Lung section shows peri-bronchial pigment deposition, after 3rd week of transfluthrin inhalation. Harris haematoxylin & eosin stain under 20x

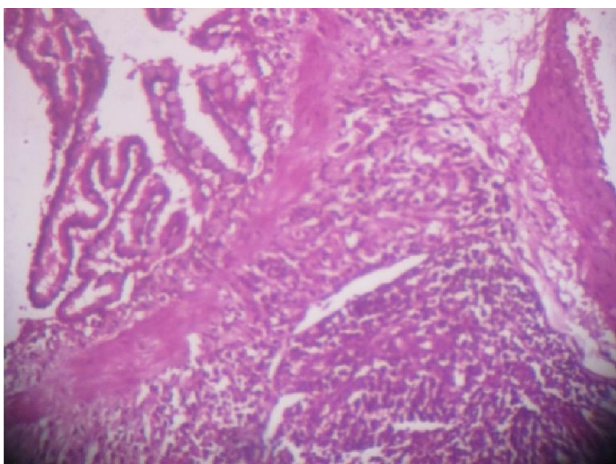


Fig.8 (Gr.V): Lung section shows peri-bronchial intense chronic inflammatory infiltrate, after 3rd week of transfluthrin inhalation. Harris haematoxylin & eosin stain under 20x

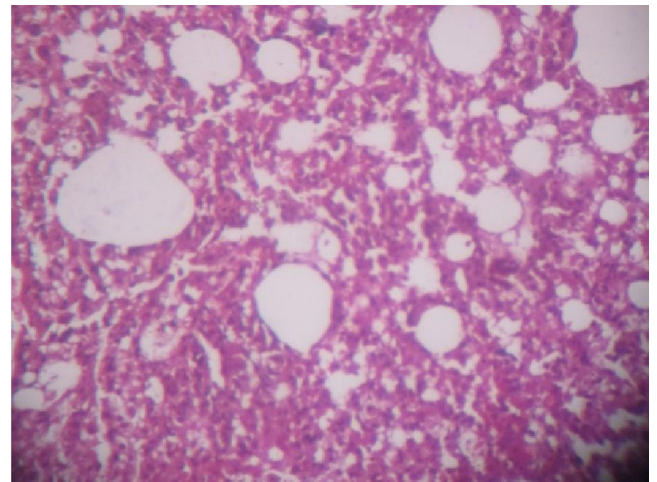


Fig.9 (Gr.V): Lung section shows desquamated lung disease, after 3rd week of transfluthrin inhalation. Harris haematoxylin & eosin stain under 20x

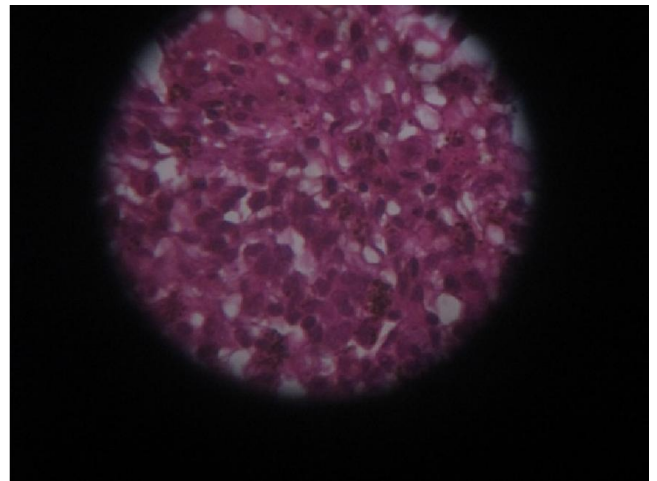


Fig.10 (Gr.V): Lung section shows desquamation with pigmentation, after 3rd week of transfluthrin inhalation. Harris haematoxylin & eosin stain under 20x

DAY 22

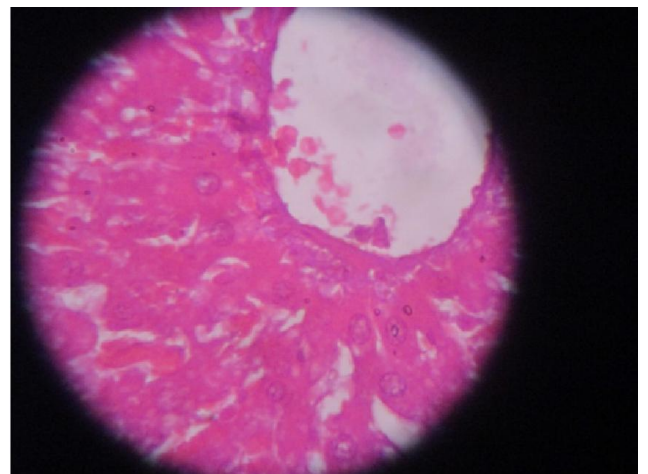


Fig.11(Gr.V): Liver section shows extensive centrilobular congestion after 3rd week of transfluthrin inhalation. (Harris haematoxylin & eosin stain under 20x)

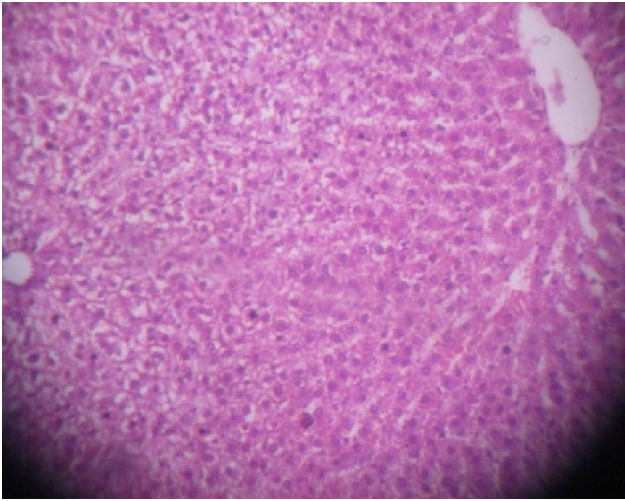


Fig.11(Gr.V): Liver section shows extensive centrilobular congestion after 3rd week of transfluthrin inhalation. (Harris haematoxylin & eosin stain under 20x)

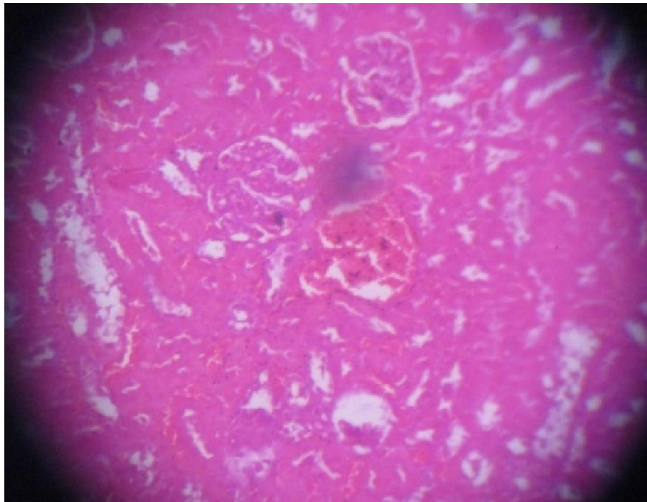


Fig.13 (Gr.V): Kidney tissue section shows congestive changes after 3rd week of inhalational transfluthrin exposure. (Harris haematoxylin & eosin stain under 20x)

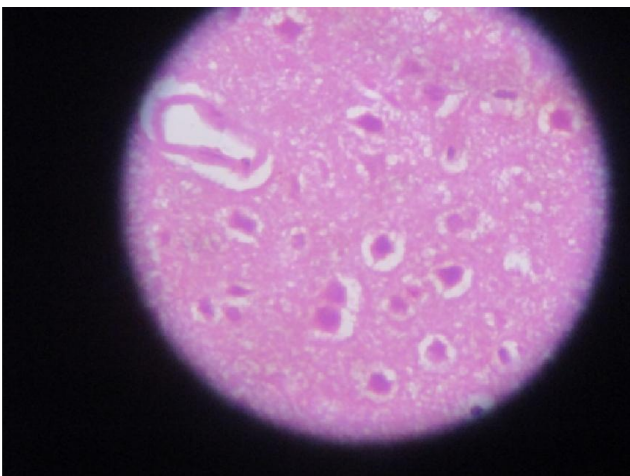


Fig.14 (Gr.V): Brain tissue section shows gliosis after 3rd week of inhalational transfluthrin exposure. (Harris haematoxylin & eosin stain under 20x)

DISCUSSION

One-sixth of the illness and disability suffered worldwide is due to vector-borne diseases, with more than half the world's population currently estimated to be at risk of these diseases. It already estimated to have caused about 207 million infections globally in 2012 and to have claimed 627 000 lives (WPRO, 2014), also, with a 30-fold increase in incidence over the past 50 years, topping 100 million cases across 100 countries in 2012. An estimated 500,000 people with severe dengue require hospitalization each year, a large proportion of whom are children; about 2.5% of those infected die. The Asia-Pacific region reports about 75% of the global dengue burden (WPRO, 2014).

We all know the famous Darwin's theory," the struggle for existence", struggle against those tiny little insects thus started in the late 1900s by a team of Rothamsted research scientists. First developed in 1973, pyrethroids are more stable to light than natural pyrethrum and possess very good insecticidal activity. Fenvalerate, the first pyrethroid was commercialized in 1978. The class of pyrethroids includes 42 active ingredients, differing in chemical structure or in relative stereoisomer composition (World health organization, 2005). Transfluthrin is a fast-acting pyrethroid insecticide with the molecular formula $C_{15}H_{12}C_{12}F_4O_2$ (World health organization, 2005). It is a relatively volatile substance and acts as a contact and inhalation agent (Information on the leaflet, UPC Code: 8901157001143).

We intentionally had chosen histopathology for toxicity evaluation rather than biochemical and haematological study, as we all know that histopathology is always the direct measure of toxicity.

So many studies on pyrethroid insecticide has already been done on different animal (mice, rats, bird, fish and hamsters etc.) about the deleterious effects of this chemical through inhalation, dermal and oral administration and results indicated irritation of the eyes, nose, and skin, abnormal facial sensations, dizziness, headache, nausea, anorexia, fatigue and vomiting (Nagarjuna 2009, Righi 2003). The histopathological data on inhalational transfluthrin toxicity on various body tissues are still not much available. In our study, Trachea shows loss of cilia, surface mucosal ulceration and sub mucosal lymphoid aggregations. Desquamative interstitial pneumonia found in lungs with mononuclear cell infiltration and peribroncheolar brown pigmentary deposits. Histological observation from liver tissue showed Significant ballooning degeneration in hepatocytes and micro vesicular periportal fatty changes with inflammatory sparse. Vascular congestion and haemorrhages were found in kidney. The current observation clearly indicate that 8hours inhalation a day through common electronic mosquito repellent machine as per the instruction printed on package inserts of the manufacturing company is enough even to cause injurious effects. Almost similar results are reported for malathion, endosulphon and other pesticides indicating exposure of these pesticides leading to histopathological disturbances in experimental animals (Ahmed 2009, Yousef *et al.*, 2003, Adeniran *et al.*, 2006), though none of those studies included transfluthrin as

experimental chemical. Still there is no antidote available to combat these toxicities; therefore further examination is needed to carry out for the development of novel therapeutic agent which totally detoxifies this toxic substance and finding out probable safe insecticide to use.

Limitations of study: Not studied with detoxifying agent

Conclusion

Transfluthrin have toxicological potential on liver, lung, trachea and kidney even if it is used as per the directions given in package inserts. Government should re-evaluate the permissible dose of transfluthrin after consultation with proper authority. The manufacturing company and research organisation should search for novel biological method to combat with insect and pest, and also novel molecule to detoxify the hazardous effects of transfluthrin.

Acknowledgement

Department of Pharmacology Burdwan Medical College & Hospital, West Bengal, India
 Department of Pharmacology, R.G.KAR Medical College & Hospital, West Bengal, India
 Department of Pathology, North Bengal Medical College & Hospital, West Bengal, India

REFERENCES

- Adeniran OY, Fafunso MA, Adeyemi O, Lawal AO, Ologundudu A, Omonkhua AA. Biochemical effects of pesticides on serum and urinological system of rats. *J Applied Sci.*, 2006; 6: 668-72.
- Ahmed M & Nasir HM. Dimethoate-induced changes in biochemical parameters of experimental rat serum and its neutralization by black seed (*Nigella sativa* L) oil. *Slovak J Anim Sci.*, 2009; 42: 87-94.
- Bancroft JD, Gamble M. Theory and practice of histological techniques: Fixation of tissues. 6th ed. Philadelphia: Elsevier, 2008.
- Bancroft JD, Gamble M. Theory and practice of histological techniques: Microtomy: paraffin and frozen. 6th ed. Philadelphia: Elsevier, 2008.
- Bancroft JD, Gamble M. Theory and practice of histological techniques: The hematoxylin and eosin. 6th ed. Philadelphia: Elsevier, 2008.
- Ghosh MN. Fundamentals of experimental pharmacology: Anaesthetics used in laboratory animals. 5th ed. Kolkata: Hilton & company; 2011.
- India. Committee for the purpose of control and supervision of experiments on animals. CPCSEA guidelines for laboratory animal facility. Annexure 3A-C: Ministry of environment & forests; 2005.
- Information on the leaflet supplied with the product: Good Knight Advanced (ACTIV+ System) Mosquito Repellent Vaporizer cartridge (UPC Code: 8901157001143).
- Mosquito - Kill Mosquito Machine, Attract mosquito for killed. Virginia: Virginia tech; 19th May 2007. Available from: www.qm.com.hk/ENG/mosquito/mosquito.htm.
- Nagarjuna A & Doss PJ. Acute oral Toxicity and Histopathological studies of Cypermethrin in rats. *Indian J Anim Res.*, 2009; 43: 235-40.
- Righi DA & Palmermo NJ. Behavioral effects of type II pyrethroid cyhalothrin in rats. *ToxicolApplPharmacol.*, 2003; 191: 76-167.
- World Health Organisation. Safety of pyrethroids for public health use. Pyrethroids – structure and insecticidal activity. Geneva: World health organisation; 2005.
- World Health Organisation. Who specifications and evaluation for public health pesticides: Transfluthrin. Geneva: World health organisation; 2002.
- WPRO | World Health Day 2014: “Small bite, big threat”. Manila: World health organisation; 4th April 2014. Available from: www.wpro.who.int/mediacentre/releases/2014/20140404/en/.
- Yousef MI, Demerdash FM, Kamel KI & Al-Salhen KS. Changes in some hematological and biochemical indices of rabbits induced by isoflavones and cypermethrin. *Toxicology.*, 2003; 189(3):223-34.
