



ISSN: 0975-833X

Available online at <http://www.journalcra.com>

International Journal of Current Research
Vol. 8, Issue, 02, pp.26912-26920, February, 2016

INTERNATIONAL JOURNAL
OF CURRENT RESEARCH

RESEARCH ARTICLE

TRABECULAR PATTERN IN THE MANDIBLE AS AN INDICATOR OF OSTEOPOROSIS IN POST MENOPAUSAL WOMEN - A RADIOLOGICAL STUDY

*Dr. Chaitra H. Ramprakash, Dr. S. Padmashree and Dr. Rema, J.

Department of Oral Medicine & Radiology, Vydehi Institute of Dental Sciences & Research Centre # 82, E.P.I.P Area, Whitefield, Bangalore - 560 066

ARTICLE INFO

Article History:

Received 07th November, 2015
Received in revised form
25th December, 2015
Accepted 19th January, 2016
Published online 27th February, 2016

Key words:

Trabecular patterns,
BMD,
DXA,
Intraoral direct digital radiograph,
Fractal box analysis,
ImageJ.

ABSTRACT

Objectives: To detect the changes in the trabecular pattern of the mandible in the post menopausal women using direct digital radiography (DDR) system & their correlation with the bone mineral density (BMD) measured at the femoral neck. The study also explored the possibility of using trabecular pattern on the mandibular intraoral periapical direct digital radiograph as a diagnostic tool to identify individuals at risk of osteoporosis.

Study design: 40 healthy dentate post menopausal women, between the age group of 40-60 years were included. The detailed case history was recorded followed by oral examination. Intraoral digital radiograph of the mandibular premolar region was done. BMD evaluation was done at the hip region using Dual energy X-ray absorptiometry (DXA). The digital radiographs were evaluated by three observers and classified into sparse, heterogenous & dense trabecular patterns. The intra and inter observer variation was evaluated. The fractal dimension (D-value) was analysed in the region of interest (ROI) selected between the premolars using ImageJ software.

Results: Statistical suggestive significance was observed when age was correlated with the T-score. The D-value obtained in our study showed statistical significance when correlated with both the T-score and the assessed trabecular patterns.

Conclusion: The fractal box analysis of the intraoral DDR can act as an identification tool in the diagnosis of the patients with the risk of osteoporosis. Thereby oral diagnosticians are in a pivotal position to screen for osteoporosis and identify patients at the risk of osteoporosis.

Copyright © 2016 Chaitra H. Ramprakash et al. This is an open access article distributed under the Creative Commons Attribution License, which permits unrestricted use, distribution, and reproduction in any medium, provided the original work is properly cited.

Citation: Chaitra H. Ramprakash, S. Padmashree and Rema, 2016. "Trabecular pattern in the mandible as an indicator of osteoporosis in post menopausal women - A radiological study", *International Journal of Current Research*, 8, (01), 26912-26920.

INTRODUCTION

Osteoporosis is a systemic skeletal disease characterized by low bone density and micro-architectural deterioration of bone tissue with a consequent increase in bone fragility. (World Health Organization, 2003) Osteoporosis is three times more common in women than in men, partly because women have a lower peak bone mass and partly because of the hormonal changes that occur at the menopause. (World Health Organization, 2003) The annual incidence rate of osteoporotic fractures in women is greater than the combined incidence rates of heart attack, stroke and breast cancer. One out of eight males and one out of three females in India suffer from osteoporosis, making India one of the largest affected countries in the world. The incidence of hip fracture in the Indian population above the age of 50 years was 105 and 159 per

100,000 among men and women, respectively. It was also observed that the hip fracture incidence was similar in both sexes till age of 55 years. From age of 55 onwards, the rates were significantly higher in women. (Dhanwal et al., 2013) In most Western countries, while the peak incidence of osteoporosis occurs at about 70-80 years of age, in India it may afflict those 10-20 years younger, at age 50-60. (http://www.dolcera.com/wiki/images/Osteoporosis_factsheet.pdf) Bone mineral density (BMD) is expressed as grams of mineral per area or volume and in any given individual is determined by peak bone mass and amount of bone loss (Osteoporosis Prevention, 2000). (++) Numerous studies have shown an inverse relationship between BMD and the incidence of osteoporotic fractures. However, other skeletal components also influence bone strength, including both the macro and micro-architecture of bone. (World Health Organization, 2003) The jawbones are the most frequently imaged bones of the body. Their morphology is altered by local stimuli, systemic diseases, and metabolic disturbances. Digital radiography allows early identification of osteoporosis and other metabolic

*Corresponding author: Dr. Chaitra H. Ramprakash

Department of Oral Medicine & Radiology, Vydehi Institute of Dental Sciences & Research Centre # 82, E.P.I.P Area, Whitefield, Bangalore - 560 066.

diseases of bone. (White *et al.*, 1999) The intra oral periapical radiographs, which are relatively inexpensive and which form a primary diagnostic tool in every dental practice can act as an aid in indicating skeletal osteoporosis. With this background the aim of our study was to detect the changes in the trabecular pattern of the mandible in the post menopausal women using DDR system & their correlation with the BMD measured at the femoral neck. The study also explored the possibility of using trabecular pattern on the mandibular intraoral digital periapical radiographs as a diagnostic tool to identify individuals at risk of osteoporosis. Thereby institution of early therapy for such patients will be beneficial for preventing the morbidity & mortality related to osteoporosis fractures.

MATERIALS AND METHODS

In the present cross sectional study, 40 healthy dentate post menopausal women, within 40-60 years of age, who visited outpatient department of our institution, were included. The study was approved by the ethical committee of our institutional research board. Women with the history of hysterectomy with ovariectomy, osteoporosis, hyperparathyroidism or hyperthyroidism, patients on hormonal replacement therapy, long term steroid medications or any systemic diseases affecting the bone metabolism and patients with previous history of hip fractures were excluded. A written informed consent from each patient was obtained. The case histories of the patients included were recorded. The patient's Body Mass Index (BMI) was calculated followed by oral examination to evaluate the periodontal status of the included patients. The Trophy IRIX 70 X-ray machine (70kv/8mA machine) with Kodak 6100 CCD (Charged coupled device) sensor was used to record the patient's digital intraoral periapical radiograph in the mandibular premolar region using paralleling technique. The bony architecture in the region of mandibular premolars is not influenced by the muscle activity or the occlusal forces. Hence this region, containing periodontally sound premolars was selected for the digital radiographic evaluation. The exposure parameters were kept constant for all the patients, which are 70kVp, 8mA. Prior to the exposure of the patients the exposure time was standardized using an aluminium step wedge with indentations. Multiple exposures were made by changing the exposure time. The exposure time of 0.26sec was ideal to reveal all the indentations and the different densities of the step wedge well without any computer manipulation. Therefore the same exposure time was used for all patients.

The patients were then subjected to BMD evaluation using the Hologic QDR 4500A machine at the hip region. The DDRs (Figure 1) were evaluated by two experienced oral radiologists and one general radiologist. The observers were given the reference radiographs from Lindh's (Lindh *et al.*, 2008) study which were present at all times during the evaluation of each every digital radiograph (Figure 2). The observers were asked to classify the patient radiographs into 3 categories;

- Sparse homogenous (A) - trabecular pattern with large intertrabecular spaces over the entire radiographed area.
- Heterogenous (B) - means dense trabecular pattern cervically and sparse trabecular pattern more apically

- Dense homogenous (C) - when the radiographic intertrabecular spaces between the trabeculae are very small over the entire radiographed area

The process was repeated with an interval of 10 days to assess for intra-observer and inter-observer variation. Fractal dimension analysis was done in the selected ROI (40 X 400 pixels) on the DDRs (Figure 3). When creating ROI great care was taken not to include lamina dura, periodontal ligament space and anatomical structures and thus they were created apically as far as possible from the crestal bone, because it has been stated that beyond 2.5mm there is no effect of bacterial plaque on alveolar process bone. (Southard *et al.*, 2001) The box count method of the ImageJ software was used for the same. The ROI was segmented to binary image and skeletonised as described by White & Rudolph. (White and Rudolph J David, 1999; White, 2002) The fractal box analysis values (D-value) obtained from the patient's digital radiograph was recorded.

Statistical analysis

Descriptive and inferential statistical analysis was carried out in the present study. Significance was defined as $P \leq 0.05$. Kappa statistics was used to find the intra and inter examiner variations. Diagnostic statistics was performed to find the diagnostic potential of trabecular pattern on the intraoral DDR in predicting the patients with osteoporosis. For visualizing the performance of the study ROC (Receiver operating characteristics) curve was done. The area under the curve (AUC) denoted the performance status of the study. The Statistical software namely SAS 9.2, SPSS 15.0, Stata 10.1, MedCalc 9.0.1, Systat 12.0 and R environment ver.2.11.1 were used for the analysis of the data.

RESULTS

Our cross sectional study included forty healthy dentate post-menopausal female patients out of which 19 (47.5%) of them belonged to the age group of 41-50 and 21 (52.5%) patients belonged to 51 – 60 years age group. The distribution of the trabecular patterns as assessed by the three observers using the reference radiographs were as follows: 24 (60%) patients had sparse trabecular pattern (A), 15 (37.5%) patients with heterogenous trabecular pattern (B) and remaining 1 (2.5%) had dense trabecular pattern (C). The reproducibility of the observer's observation both intra-observer and inter-observer was assessed with an interval of 10 days. The strength of intra-observer agreement was fair among observers 1 & 3 (kappa values of 0.453 & 0.390 respectively) and very good with the other observer (kappa values of 0.865). The strength of agreement between the observers (inter-observer) was good between observer 1 & 2 (kappa 0.621), was poor between observer 1 & 3 (kappa 0.151) and was fair between observers 2 & 3 (kappa 0.278). The bone mineral density evaluation using DXA revealed that 14 (35%) patients had their T-score within the normal range, 7 (17.5%) patients were osteoporotic and the remaining 19 (47.5%) of them were osteopenic (Table 1). The distribution of the D-value is as follows: In 21 (52.5%) patients the D-values were in the range of 1.2-1.3 and in 19 (47.5%) patients it was in the range of 1.3-1.4 (Table 2).

Table 1. Distribution of patients based on T score

Diagnosis	Number of patients	%
Normal	14	35.0
Osteopenia	19	47.5
Osteoporosis	7	17.5
Total	40	100.0

Table 2. Distribution of D-value with T-score of the patients studied

D-value	Diagnosis					
	Normal		Osteopenia		Osteoporosis	
	No	%	No	%	No	%
1.2-1.3	10	71.4	10	52.6	1	14.2
1.3-1.4	4	28.5	9	47.3	6	85.7
Total	14	100.0	19	100.0	7	100.0

Table 3: Comparison of age, BMI and D-value with the T-score of the patients studied

Variables	Normal	Osteopenia	Osteoporosis	P value
Age in years	52.21±4.06	51.31±6.09	56.71±6.10	0.092+
BMI kg/m ²	30.47±6.36	28.28±5.51	27.08±6.66	0.417
D-value	1.28±0.03	1.30±0.03	1.32±0.02	0.093+

+ Suggestive significance (P value: 0.05<P<0.10)

Table 4. Association of direct digital intraoral radiographs' assessment of the trabecular pattern by the three observers and diagnosis based on T-score

Trabecular patterns	Diagnosis based on T-score					
	Normal		Osteopenia		Osteoporosis	
	No.	%	No.	%	No.	%
A (Sparse)	8	57.1%	11	57.9%	5	71.4%
B (Heterogenous)	6	42.9%	7	36.8%	2	28.6%
C (Dense)	0	0	1	5.3%	0	0
Total	14	100.0%	19	100.0%	7	100.0%

Table 5. Comparison of age, T-score, BMI and D-value with the three trabecular patterns assessed by three observers of patients studied

Variables	A (Sparse)	B(Heterogenous)	C (Dense)	P value
Age in years	53.58±5.64	51.27±5.68	48.00	0.341
T-score	-1.42±1.07	-1.20±0.91	-0.40	0.537
BMI kg/m ²	29.37±6.41	28.55±5.23	20.46	0.346
D-value	1.31±0.03	1.29±0.03	1.28	0.048*

* Moderately significant (P value: 0.01<P ≤ 0.05)

Table 6. Diagnostic performance of trabecular patterns to predict the osteopenia & Osteoporosis

	Sensitivity	Specificity	PPV	NPV
Osteopenia	68.42	47.62	54.12	65.50
Osteoporosis	85.71	57.58	30.00	95.00
Osteopenia+	69.24	57.14	75.00	50.00
Osteoporosis				

PPV-Positive predictive value, NPV-Negative predictive value

Table 7. ROC curve analysis for predicting osteopenia & Osteoporosis with trabecular pattern based on T-score and D-value

	Sensitivity	Specificity	AUC	P value
T score(<-7)	87.50	31.25	0.575	0.421
D value (>1.27)	95.83	43.75	0.736	0.003**
Inference	D-value is strongly significant with P value of 0.003			

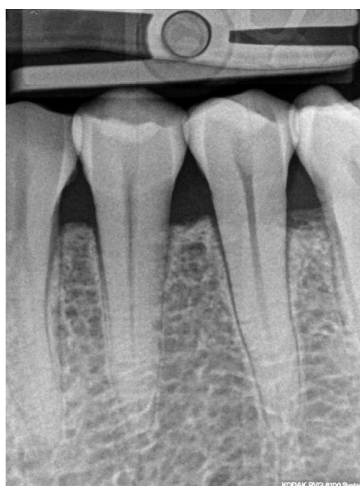

Figure 1. The direct digital intraoral periapical radiograph of the mandibular premolar region of a patient obtained using paralleling technique

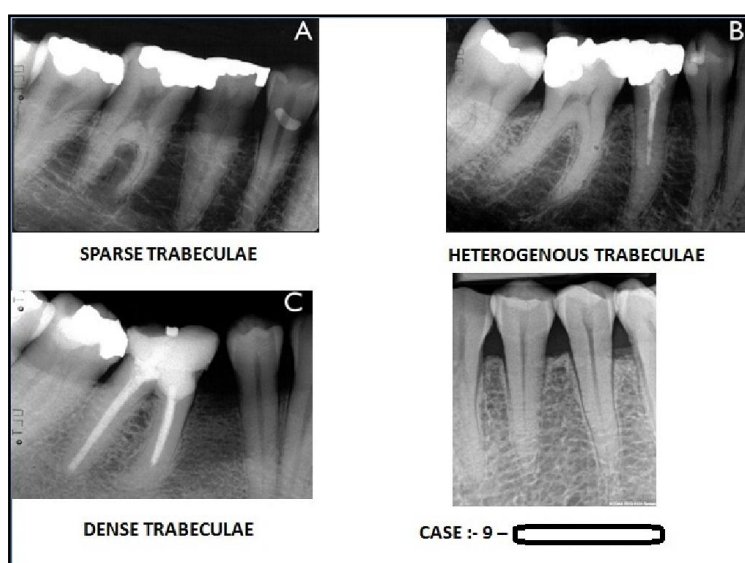


Figure 2. The screenshot showing that the patient direct digital intraoral periapical radiograph is compared with the reference radiographs by the observers to evaluate the different trabecular pattern

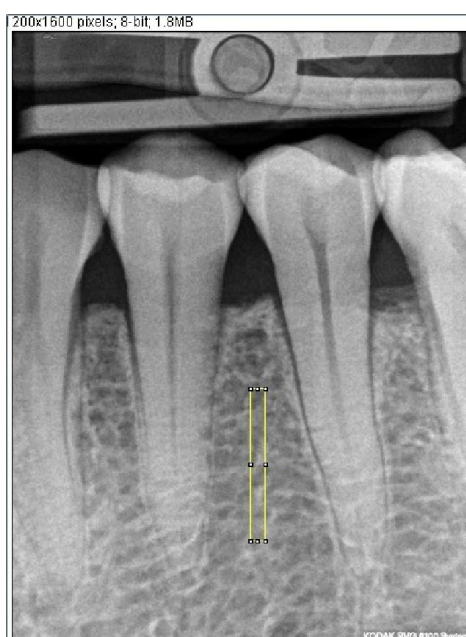

Figure 3. Screen shot of the region of interest measuring about 40 X 400 pixels (the yellow rectangular outline), which is selected on the direct digital intraoral periapical radiograph using ImageJ (1.41v) software




Figure 4. Digital manipulation of the Region of Interest (ROI) A – The region of interest (ROI), B – The result of blurring this region, C – The result of subtracting B from A, D – Subtracted image by adding 128, E – The resultant image made binary, F – The binary image is inverted, G – The inverted image is skeletonised

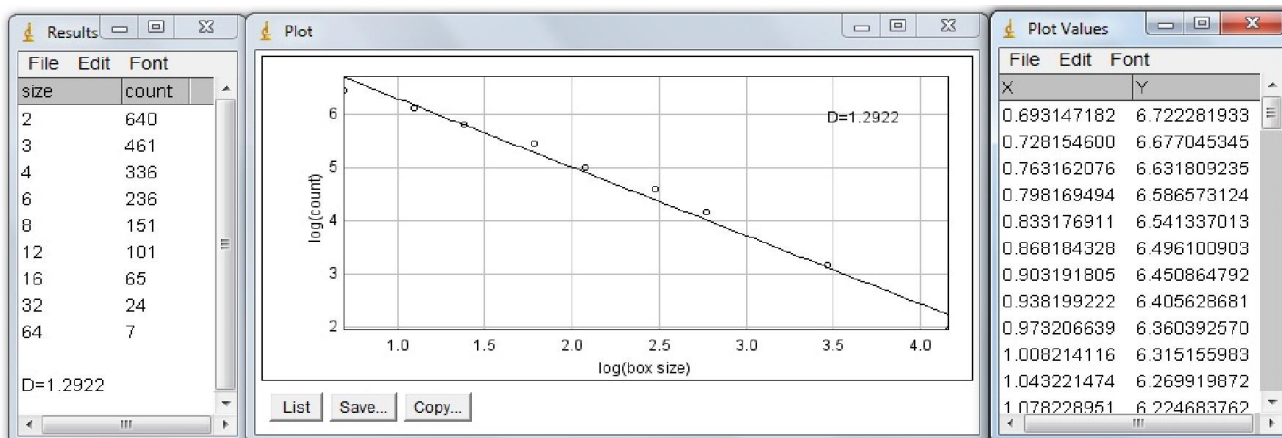
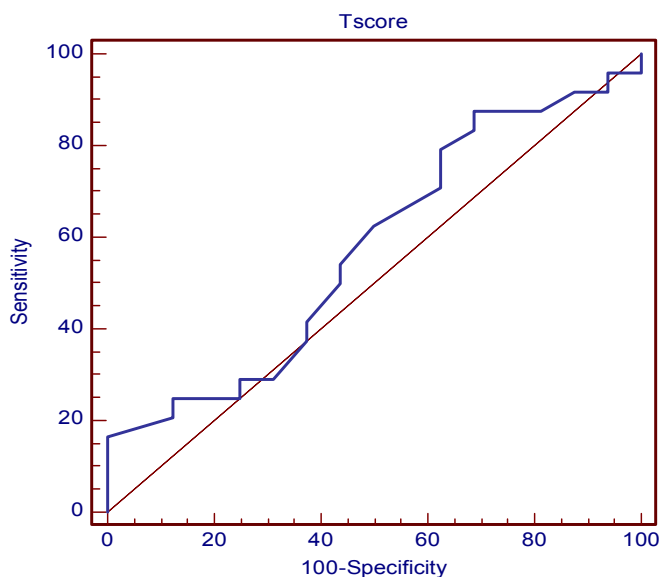
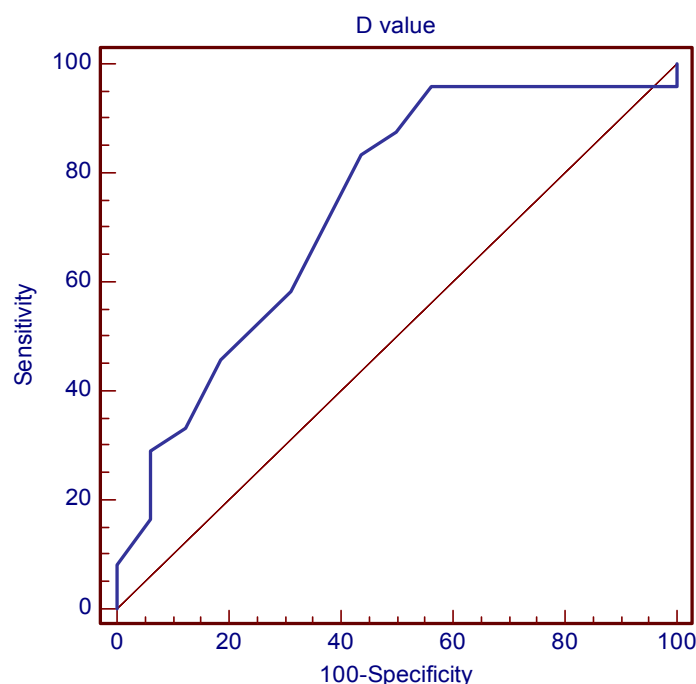


Figure 5. The screenshot of the fractal box analysis of the skeletonised image giving the D – value



Graph 1. ROC curve analysis for predicting osteopenia & osteoporosis with trabecular pattern based on T-score. The area under the curve (AUC) is small (arrow) which is indicative of no statistical significance



Graph 2. ROC curve analysis for predicting osteopenia & osteoporosis with trabecular pattern based on D-value. The area under the curve (AUC) is large (arrow) indicative of statistically significant correlation

The correlation of age, BMI, D-value with the T-score as evaluated by the DXA at the hip region was done. In our study there was statistically suggestive significance with the P value of 0.092 when the age was correlated with T-score. The correlation of the BMI with the T-score revealed no significance in our study with a P value of 0.417. The D-value when correlated with the T-score; it revealed that there was statistical suggestive significance with a P value of 0.093 (Table 3). The distribution of the trabecular pattern on intraoral DDRs as assessed by the three observers was correlated with the T-score, showed that the patients with the Sparse (A) trabecular pattern, 8 out of 14 (57.1%) of them had normal T-score, 11 out of 19 (57.9%) of them had osteopenia and 5 out of 7 (71.4%) of them had osteoporosis. The patients with heterogeneous (B) trabecular pattern, 6 out of 14 (42.9%) of them had normal T-score, 7 out of 19 (36.8%) had osteopenia and 2 out of 7 (28.6%) had osteoporosis. Among the 24 sparse trabecular pattern (as assessed by the observers), 16 of them were having osteopenia or osteoporosis. Among the 15 heterogeneous patterns, 9 of them were having osteoporosis or osteopenia. The patient with Dense (C) trabecular pattern that is 1 (5.3%) of them had osteopenia (Table 4).

The association of trabecular pattern as assessed by the three observers when correlated with the T-score, age and the BMI, it did not show statistical significant correlation. But the D-value showed moderately significant correlation with the three trabecular patterns with a P value of 0.048 (Table 5). The diagnostic performance of the trabecular pattern as observed in the digital intraoral periapical radiographs to predict the osteoporosis presented with sensitivity of 85.71% and a specificity of 57.58% (Table 6). The ROC curve to evaluate

the diagnostic performance of the D-value with the trabecular pattern as assessed by the observers showed an area under the curve (AUC) of 0.736 suggested it to be a fair test with a P value of 0.003 which was statistically strongly significant (Table 7). The sensitivity of predicting osteoporosis with the D-value was 95.83% and the specificity was 43.75% (Graph 1 & 2). The large AUC showed that from our study the D-value was more reliable and specific in assessing osteopenia or osteoporosis in patients with the help of intraoral DDRs than by visual observation of the trabecular pattern alone.

DISCUSSION

Osteoporosis is the term used for diseases of diverse etiology that cause a reduction in the mass of bone per unit volume. It is the most common of the metabolic bone diseases and is an important cause of morbidity in the elderly. (Wilson, 1991) The evaluation of BMD by DXA at the hip region which is the gold standard in assessing the patients for osteoporosis or at the risk of osteoporosis. (World Health Organization, 2003; NIH Consensus Statement, 2000; White, 2002; Jonasson *et al.*, 2006) It is noted that with the onset of menopause, rapid bone loss occurs which is believed to average approximately 2% to 3% over the following 5 to 10 yrs, being greatest in the early postmenopausal years (Indumati *et al.*, 2007). Hence the age range which we have chosen in our study is small that is between 40 – 60 years. This would help in identifying individuals at the risk of osteoporosis and institute early management. All the risk factors associated with osteoporosis were excluded and hence, we were able to screen the apparently healthy individuals to evaluate the silent disease like osteoporosis. None of our patients included in the study had

any habit of smoking or alcohol consumption which are also known risk factors for osteoporosis. Bone remodelling is more extensive in the trabecular bone than in the compact bone and as a consequence the manifestation of osteoporosis is more extensive in the trabecular bone. (Lindh *et al.*, 2008) Visual assessment of the trabecular pattern in intraoral periapical radiographs of premolar regions is a potential method to identify women at risk of having osteoporosis. The bony architecture in the region of mandibular premolars is not influenced by the muscle activity or the occlusal forces (http://www.dolcera.com/wiki/images/Osteoporosis_factsheet.pdf) and would represent the changes in the general skeleton. The intraobserver agreement was fair to good, but the interobserver agreement was poor to fair, which is in accordance with the study done by Lindh *et al.* (2008) One explanation of the low inter-observer agreement could be that, generally, image reading is a matter of identifying a signal (the radiological abnormality) against a noisy background of structures and of combining the features meaningfully to discriminate between 2 alternatives, disease or no disease. This feature is in accordance with the study done by Lindh *et al.* (2008) The maximum differences were experienced in the heterogenous group (B). But the agreement between the observers in identifying the sparse trabecular pattern was good. When the age distribution was correlated with the DXA values at the hip region, it showed statistically suggestive significance with P value of 0.092, which is supported by many other studies. (Von Wöern and Stoltze, 1978; Southard *et al.*, 2000; Lee and White, 2005; Verheij *et al.*, 2009) Therefore it can be concluded that as the age increases, the risk of osteoporosis also increases. This factor alone will not be an indicator, as there are many risk factors for osteoporosis (Jeffcoat, 2005), it is interplay of multiple factors. When the average distribution of the trabecular pattern as assessed by the observers was correlated with the T-score, no statistical significance was noted with the P value of 0.537. This observation is in accordance with the Osteodent project conducted in 2008. (Lindh *et al.*, 2008) However; Johnsson *et al.* (2009) has shown the significant correlation between the trabecular patterns and the T-score obtained from the whole body and in the forearm BMD (Jonasson *et al.*, 2001) evaluation by DXA.

Among the 24 sparse trabecular pattern (as assessed by the observers), 16 of them were having osteopenia or osteoporosis. Among the 15 heterogenous pattern, 9 of them were having osteoporosis or osteopenia. Thereby based on our study we could possibly predict patients with osteoporosis or at the risk of osteoporosis by visual examination of the trabecular pattern on the DDR system in the mandibular premolar region. So a large sample size may reveal a significant statistical association. When the trabecular pattern was correlated with the age and BMI, it showed no statistical significance with the P values of 0.341, 0.346 respectively. This finding is in contradiction to the findings by Johnsson *et al.* (2009) in which the authors have found a significant correlation between the trabecular pattern and the age and BMI and also with the study done by Verheij, *et al.* (2009) in which significant correlation was found with age and the trabecular pattern. The digital radiography has many advantages like reduced patient exposure, facility for image manipulation and viewing the minute details on the image. Bansal (2006) has found that the

direct digital radiography was equivalent to conventional radiography in showing bones, soft tissue, and trabecular detail. Dental radiographs, whether made with film or digital sensors, provide relatively high spatial resolution images of the basal and alveolar bone. The advent of digital radiography offers dentists the means to analyse features of the bone and teeth to detect early or subtle manifestations of disease. (White *et al.*, 2000) The digital images can be stored and shared within the fraternity for the benefit of patient management. The computer softwares also help in evaluating the image, in the region of interest like the pixel intensity (Hedström *et al.*, 2010), photodensitometric analysis (Jonasson *et al.*, 2001), colour histograms (Božić and Ihan Hren, 2005), trabecular patterns classification (Lindh *et al.*, 2008; Jonasson *et al.*, 2009; Jonasson, 2009) fractal dimension analysis (Jolley *et al.*, 2006; ShROUT *et al.*, 1998; Yasar and Akgunlu, 2005; Guilherme *et al.*, 2006; Yasar and Akgunlu, 2006; Yasar and Akgunlu, 2008; Kyung-Hoe Huh *et al.*, 2011). These are all simple applications when applied can aid in identifying and analysing changes at the very early stage of a disease. This can further assist in efficient management of the condition. With respect to the structure of the trabecular pattern on dental radiographs, some studies have explored the use of fractal dimension as a predictive parameter for osteoporosis. (Law *et al.*, 1996; Geraets *et al.*, 2008)

The fractal dimension is relatively independent of technical settings of periapical radiographs. Thus it can be used on existing; non-standardized radiographs would potentially make it a valuable research and diagnostic tool. (Jolley *et al.*, 2006) To overcome the observer bias, which can act as a confounder in our study, we undertook the digital evaluation of the radiographs by fractal box count analysis using ImageJ software. The studies have shown that 2.5mm below the alveolar crest, the alveolar bone is not under the influence of plaque and calculus (Jolley *et al.*, 2006), thus we selected the region of interest (ROI) in the same location. Areas of as small as 0.10cm² of interdental bone on intraoral dental radiographs are large enough to enable prediction of femoral and spinal BMD. (Geraets *et al.*, 2008) Thus the ROI (40X400 pixels) used in our study is large enough to predict the changes in the general skeleton (Figure 3). In our study the regions of interest on the digital radiographs were skeletonised as described by S C White and Rudolph (White and Rudolph J David, 1999) (Figure 4) and the fractal dimension was analysed using the box count method by applying the ImageJ software (Figure 5). We observed increased D-values in the patients with osteopenia and osteoporosis. This suggested that in our study, the D-value had a correlation with the (BMD value at the hip region) T-score (P value of 0.093 – suggestive significance) which is the gold standard in the evaluation of Osteoporosis. There are studies which have reported both increase (Geraets and van der Stelt, 2000) and decrease (Southard *et al.*, 2001) in the fractal dimension values in patients with osteoporosis. Our study is in accordance with the studies conducted by Geraets *et al.* (2000), Law *et al.* (1996), Kaufman *et al.* (1987) However, Southard T *et al.* (2001) in their study have found decrease in D-value in osteoporosis. Each imaging modality may have its own non-linear artefacts such as sampling frequency and noise and this may have an effect on the results of fractal dimension. (Geraets and van der Stelt, 2000)

According to our study the increase in the D-value could be considered as an indicator of osteoporosis. The D-value when correlated with the average distribution of the trabecular pattern as assessed by the observers, showed a statistically moderate significance with a P value of 0.048. Thereby we could infer from our study that the visual assessment of the trabecular pattern when combined with the fractal dimension analysis can identify individuals with osteoporosis. Therefore digital intraoral radiographs with simple computer software can serve as an identification tool in patients who are at the risk of osteoporosis. We have found that dense trabeculation is a reliable sign of normal BMD, whereas sparse trabeculation indicates osteopenia. Alternating dense and sparse trabeculation was found both in patients with low and in those with normal BMD. The probability of detecting osteoporosis by the trabecular pattern in the mandible (sensitivity) was 85.71% and the specificity was 57.58%. This is in accordance with the study done by Lindh *et al.* (2008), Johnsson *et al.* (2006), White (2002), Lee *et al.* (2005) It was observed that the probability of the absence of osteoporosis when the trabecular patterns were dense was as high as 95% (Negative predictive value), which is in accordance with the study done by Johnsson *et al.* (2009), Taguchi *et al.* (2004), Lindh *et al.* (2008). The ROC (Receiver operating characteristics) curve showed an increased area under the curve (AUC) correlating the trabecular patterns and the D-value, in contrast to the trabecular patterns comparison with the gold standard T-score. This is in accordance with the study done by White *et al.* (2005) who found that trabecular changes in the intraoral radiographs with digital manipulation could predict the fracture rate at the hip region. This suggested that in our study the D-value was more specific in assessing osteopenia or osteoporosis using DDRs of these patients rather than by visual assessment of the trabecular pattern alone. Although we didn't find a correlation between the visual assessments of trabecular pattern and the BMD values (T-score) at the hip region, we noted a good correlation between T-score and a simple computer algorithms like fractal dimension analysis (D-value) by digital manipulation of the radiographs which when incorporated can act as an aid in identifying individuals with osteoporosis or at the risk of osteoporosis. In conclusion, the implementation of the cost effective and simple intraoral digital imaging for routine examination at the primary health centres would serve the purpose of screening the individuals for a systemic silent disease like osteoporosis. A simple computer algorithm available with the digital radiography can further improve our diagnosis, thus act as an identification tool in screening the patients for osteoporosis. As our study period was limited and the sample size gathered was small, a prospective long term follow up study would be productive. It would have more significant correlation if perimenopausal women were also included and followed up with periodic evaluation of the trabecular pattern changes (micro-architecture of the jaw bones) using digital intraoral radiographs and correlating the same with the changes in the skeletal BMD. Thereby the oral diagnosticians would be in a pivotal position to screen for osteoporosis. Early identification of the individuals with sparse trabecular pattern can help in referring such patients for investigations like DXA for further treatment and management of osteoporosis.

REFERENCES

- Bansal G J. Digital radiography. A comparison with modern conventional imaging. *Postgrad Med J.*, 2006; 82: 425 – 428.
- Božić M and Ihan Hren N. Osteoporosis and mandibles. *Dentomaxillofac Radiol.*, 2005; 35: 178–184.
- Dhanwal D.K, Siwach R, Dixit V, Mithal A, Jameson K, Cooper C. Incidence of hip fracture in Rohtak district, North India. *Archives of Osteoporosis.* April 2013, 8:135.
- Geraets WG, van der Stelt PF. Fractal properties of bone. *Dentomaxillofac Radiol.*, 2000; 29: 144-53.
- Geraets WG, Verheij JG, Van der Stelt PF, Horner K, Lindh C, Nicopoulou-Karayianni K, *et al.* Selecting regions of interest on intraoral radiographs for the prediction of bone mineral density. *Dentomaxillofac Radiol.*, 2008; 37: 375–379.
- Guilherme T, Tosoni M, Lurie AG, Cowan AE and Burleson JA. Pixel intensity and fractal analyses: detecting osteoporosis in perimenopausal and postmenopausal women by using digital panoramic images. *Oral Surg Oral Med Oral Pathol Oral Radiol Endod.*, 2006; 102: 235-41.
- Hedström L, Baigi A and Bergh H. The relation between bone mineral density in the heel and pixel intensity in the mandibular jaw bone among elderly women. *Dentomaxillofac Radiol.*, 2010; 39: 409–413.
- Indumati V, Patil. S Vidya and Rama Jaikhani. Hospital based preliminary study of Osteoporosis in post menopausal women. *Indian J Clin Biochem.*, 2007; 22(2): 96 – 100.
- International osteoporosis foundation (IOF). Available from: http://www.dolcera.com/wiki/images/Osteoporosis_factsheet.pdf
- Jeffcoat M. The association between osteoporosis and oral bone loss. *J Periodontol.*, 2005; 76: 2125 – 2132.
- Jolley L, Majumdar S and Kapila S. Technical factors in fractal analysis of periapical radiographs. *Dentomaxillofac Radiol.*, 2006; 35: 393–397.
- Jonasson G, Bankvall G, Kiliaridis S. Estimation of skeletal bone mineral density by means of the trabecular pattern of the alveolar bone, its interdental thickness, and the bone mass of the mandible. *Oral Surg Oral Med Oral Pathol Oral Radiol Endod.*, 2001; 92: 346-52.
- Jonasson G, Jonasson Lisa, Stavros Kiliaridis. Changes in the radiographic characteristics of the mandibular alveolar process in dentate women with varying bone mineral density: A 5-year prospective study. *Bone*, 2006; 38: 714–721.
- Jonasson G, Torgny Alstad, Flor Vahedi, Ingvar Bosaeus, Lauren Lissner and Magnus Hakeberg. Trabecular pattern in the mandible as bone fracture predictor. *Oral Surg Oral Med Oral Pathol Oral Radiol Endod.*, 2009; 108: e42-e51.
- Jonasson G. Bone mass and trabecular pattern in the mandible as an indicator of skeletal osteopenia: a 10-year follow-up study. *Oral Surg Oral Med Oral Pathol Oral Radiol Endod.*, 2009; 108: 284-291.
- Kaufman JJ, Hakim N, Nasser P, Mont M, Klion M, Pilla AA *et al.* Application of digital image processing and pattern recognition to diagnosis of osteoporosis. *IEEE Proceedings of the Annual Conference of the Engineering in Medicine and Biology Society*, 1987; 9: 1334 – 1335.

- Kyung-Hoe Huh, Jee-Seon Baik, Won-Jin Yi, Min-Suk Heo, Sam-Sun Lee, Soon-Chul Choi, Sun-Bok Lee, Seung-Pyo Lee. Fractal analysis of mandibular trabecular bone: optimal tile sizes for the tile counting method. *Imaging Sci Dent*, 2011; 41 : 71-8.
- Law AN, Bollen AM, Chen SK. Detecting osteoporosis using dental radiographs: a comparison of four methods. *J Am Dent Assoc.*, 1996; 127: 1734 - 1742.
- Lee BD and White SC. Age and trabecular features of alveolar bone associated with osteoporosis. *Oral Surg Oral Med Oral Pathol Oral Radiol Endod.*, 2005; 100: 92-8.
- Lindh C, Horner K, Jonasson G, Jacobs R, van der Stelt P, Marjanovic E, *et al.* The use of visual assessment of dental radiographs for identifying women at risk of having osteoporosis: the OSTEODENT project. *Oral Surg Oral Med Oral Pathol Oral Radiol Endod.*, 2008; 106(21): 285-93.
- Osteoporosis Prevention, Diagnosis, and Therapy. NIH Consensus Statement 2000 March 27-29; 17(1): 1-45.
- Shrout MK, Roberson B, Potter BJ, Mailhot JM, Hildebolt CF. A comparison of 2 patient populations using fractal analysis. *J Periodontol.*, 1998; 69: 9-13.
- Southard K.A, Southard T.E, Schlechte J.A, Meis P.A. The Relationship between the density of the alveolar processes and that of post-cranial bone. *J Dent Res.*, 2000; 79: 964 – 949.
- Southard TE, Southard KA, Lee A. Alveolar process fractal dimension and postcranial bone density. *Oral Surg Oral Med Oral Pathol Oral Radiol Endod.*, 2001; 91: 486-91.
- Taguchi A, Yoshikazu Sueti, Mitsuhiro Sanada, Masahiko Ohtsuka, *et al.* Validation of Dental Panoramic Radiography Measures for Identifying Postmenopausal Women with Spinal Osteoporosis. *AJR*, 2004; 183: 1755–1760.
- Verheij JGC, Geraets WGM, van der Stelt PF, Horner K, Lindh C, Nicopoulou-Karayianni K, *et al.* Prediction of osteoporosis with dental radiographs and age. *Dentomaxillofac Radiol.*, 2009; 38: 431–437.
- Von Wowern N, Stoltze K. Sex and age differences in bone morphology of mandibles. *Scand J Dent Res.*, 1978; 86(6): 478-85.
- White S. C and Rudolph J David. Alterations of the trabecular pattern of the jaws in patients with osteoporosis. *Oral Surg Oral Med Oral Pathol Oral Radiol Endod.*, 1999; 88: 628-35.
- White SC, Atchison KA, Gornbein JA, Nattiv A, Paganini-Hill A, Service SK and Yoon DC. Change in mandibular trabecular pattern and hip fracture rate in elderly women. *Dentomaxillofac Radiol.*, 2005; 34: 168-174.
- White SC, Cohen JM, Mourshed FA. Digital analysis of trabecular pattern in jaws of patients with sickle cell anemia. *Dentomaxillofac Radiol.*, 2000; 29:119-124.
- White SC, Yoon DC, Tetradis S. Digital radiography in dentistry: what it should do for you. *J Calif Dent Assoc.*, 1999; 27(12):942-52.
- White SC. Oral radiographic predictors of osteoporosis. *Dentomaxillofac Radiol.*, 2002; 31, 84 – 92.
- Wilson JD, Braunwald E, Isselbacher K J, Petersdorf RG, Martin JB, Fauci AS, *et al.* Harrison's Principles of Internal Medicine. 12th ed. McGraw-Hill, Inc; 1991.
- WHO Study Group. Assessment of fracture risk and its application to screening for postmenopausal osteoporosis. WHO Technical Report Series No 843. Geneva: WHO Press, 1994
- World Health Organization. Prevention and management of osteoporosis. Technical Report Series, No. 921. Geneva: WHO, 2003.
- Yasar F and Akgunlu F. Fractal dimension and lacunarity analysis of dental radiographs. *Dentomaxillofac Radiol.*, 2005; 34: 261–267.
- Yasar F and Akgunlu F. The differences in panoramic mandibular indices and fractal dimension between patients with and without spinal osteoporosis. *Dentomaxillofac Radiol.*, 2006; 35: 1–9.
- Yasar F, Akgunlu F. Evaluating Mandibular Cortical Index Quantitatively. *Eur J Dent*, 2008; 2: 283-290.
