



## CASE STUDY

### REHABILITATION OF ATROPHIC MAXILLA WITH BASAL IMPLANT: A CASE REPORT

Dr. Priyanka Thukral, Dr. Shweta Bali, Dr. Nidhi Bhatia and \*Dr. Shobhit Arora

Department of Periodontology, Santosh Dental College, Pratap Vihar, Ghaziabad, Uttar Pradesh, India

#### ARTICLE INFO

##### Article History:

Received 29<sup>th</sup> December, 2015  
Received in revised form  
24<sup>th</sup> January, 2016  
Accepted 17<sup>th</sup> February, 2016  
Published online 31<sup>st</sup> March, 2016

##### Key words:

BCS implants, Immediate loading,  
Atrophic maxilla.

#### ABSTRACT

Implant placement in severely atrophic jaws is specially challenging because of the poor quality and quantity of the future implant bed. (Scortecce *et al.*, 2001) Calvarial or iliac bone grafts, mental nerve displacement, and sinus lift procedures are often used to overcome the initially unfavourable anatomical and mechanical conditions. (Misch *et al.*, 1999) Furthermore, patients are sometimes reluctant to undergo such procedures. Recent studies reported that basal Implants can be installed in which the vertical bone supply is reduced. The present case report highlights the placement of four basal implants (BCS-Basal cortical screw) in atrophic maxillary area with flapless technique. All the implants were immediately loaded and followed up for a period of 1 year.

Copyright © 2016, Priyanka Thukral *et al.* This is an open access article distributed under the Creative Commons Attribution License, which permits unrestricted use, distribution, and reproduction in any medium, provided the original work is properly cited.

Citation: Dr. Priyanka Thukral, Dr. Shweta Bali, Dr. Nidhi Bhatia and Dr. Shobhit Arora, 2016. "Rehabilitation of atrophic maxilla with basal implant: A case report", *International Journal of Current Research*, 8, (03), 28601-28604.

## INTRODUCTION

The conventional crestal implants are indicated in situations when an adequate vertical bone supply is given as they are inserted into the jaw bone coming from the crestal alveoli and whose main load transmitting surfaces are vertical. These crestal implants function well in patients who provide adequate bone when treatment starts, but prognosis is not good as soon as augmentation become part of the treatment plan. Augmentation procedures tend to increase the risks and costs of dental implant treatment as well as the number of necessary operations. Patients who have severely atrophied jaw bones paradoxically receive little or no treatment. (Yadav *et al.*, 2015) Basal implantology also known as bicortical implantology or just cortical implantology is a modern implantology system which utilizes the basal cortical portion of the jaw bones for retention of the dental implants which are uniquely designed to be accommodated in the basal cortical bone areas. (Yadav *et al.*, 2015) The basal bone provides excellent quality cortical bone for retention of these unique and highly advanced implants and is always present throughout life; it is very strong and forms the stress bearing part of our skeleton. These basal implants are also called as lateral implants or disk implants. (German & European Standard: DINEN 31902-1) Dental

implants when placed in this bone can also be loaded with teeth immediately. This science is already proved in orthopedic implants (Hip / Knee replacements). Once the patient is fitted with the artificial joint patient is asked to start using it immediately. (Yadav *et al.*, 2015)

### Case report

A 23 years old patient reported to the Department of Periodontics and Oral Implantology, Santosh Dental College, Ghaziabad with a chief complaint of missing upper teeth for the last 5 years. Clinical examination revealed severely atrophic maxillary arch with missing 12 11 21 22 23 teeth (Fig.1). Radiographic investigation (CBCT) showed generalized vertical and horizontal bone loss in upper alveolar arch (Fig.2). The patient was in good health and had no contraindications to surgical therapy with absence of local inflammation and absence of mucosal disease.

**A written consent from the patients was taken after the whole procedure was explained to them**

### Surgical Treatment

In the anterior segment of the maxilla, we utilized the basal bone which forms the floor of the nose and the lateral wall of the nose as a second cortical. Four BCS implants were inserted using flapless technique in different directions to gain maximum support and anterior anchorage for the bridge (Fig.3).

\*Corresponding author: Dr. Shobhit Arora,

Department of Periodontology, Santosh Dental College, Pratap Vihar, Ghaziabad, Uttar Pradesh, India.

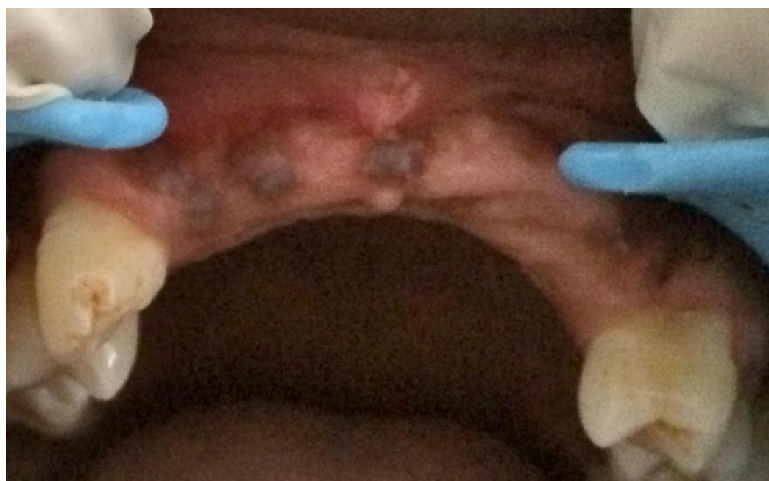

Fig.1. Pre operative view showing atrophic maxilla with missing teeth

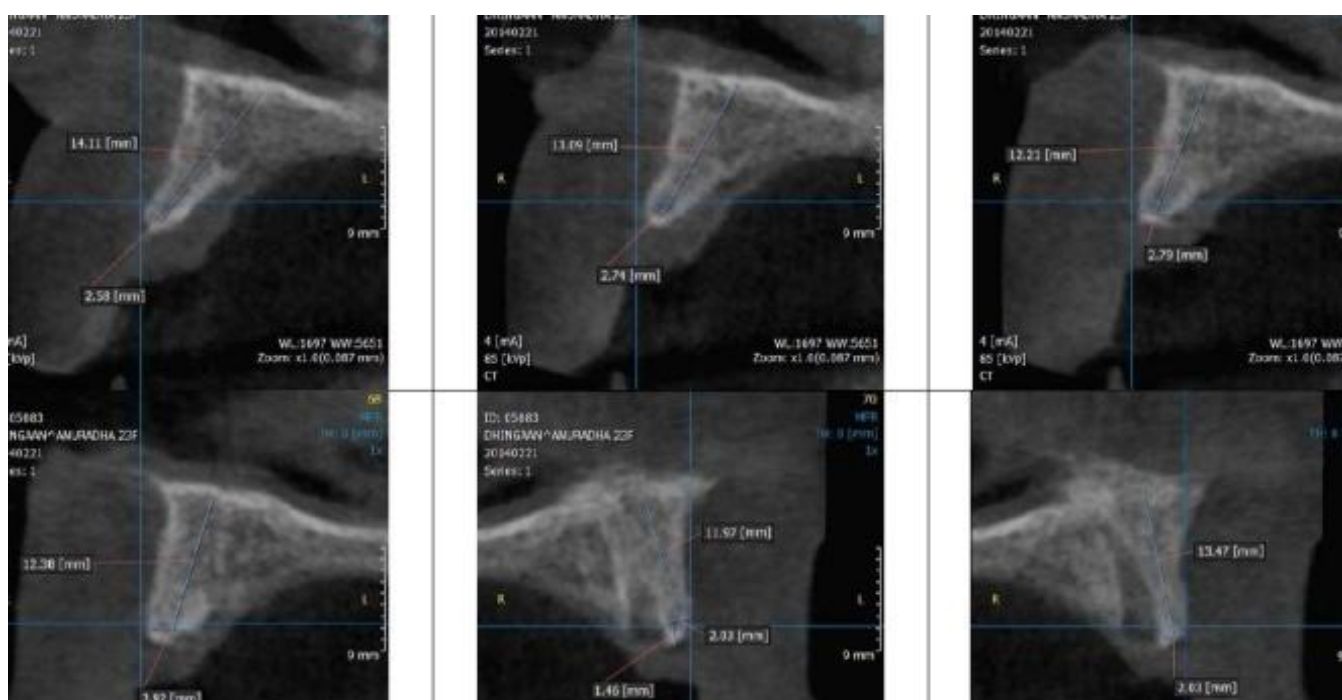


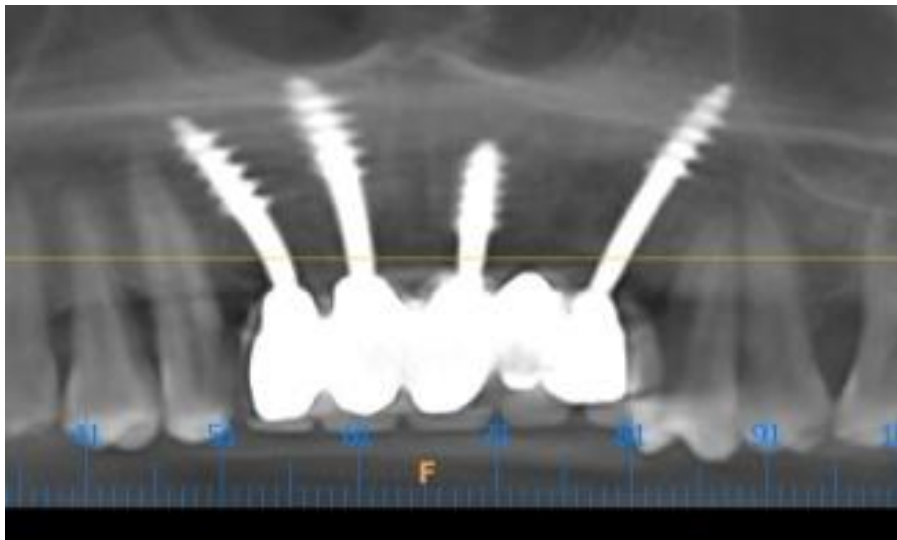
Fig.2. CBCT showing atrophic maxillary arch W.R.T. Anteriors

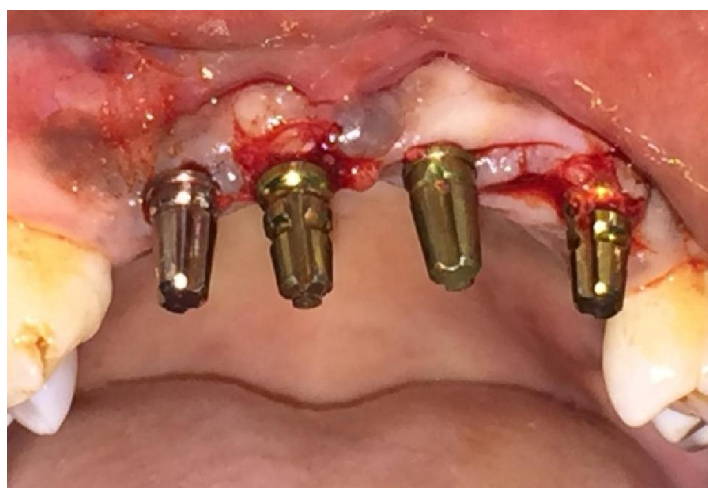
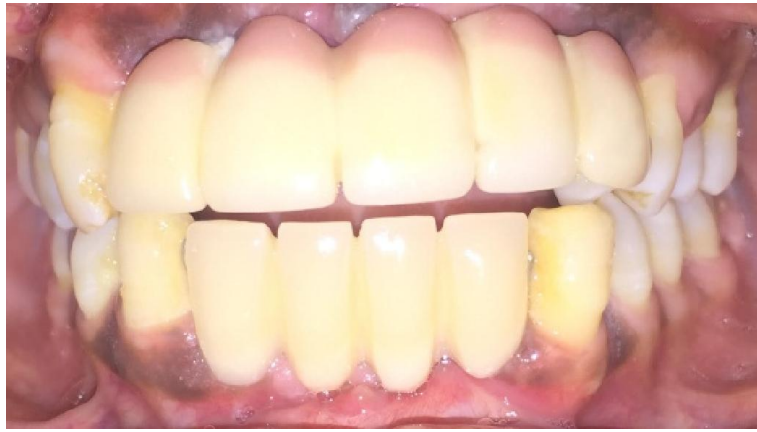
Fig.3. BCS implants placed



**Fig.4. Immediate implant loading**



**Fig.5. Radiographic evaluation after 12 months showing all four implants with good osseointegration**

Impressions were taken immediately after the bending of implants to achieve balanced occlusion. Satisfactory primary stability was achieved with all the four implants and immediate OPG showed good parallelism as well. Then the dental lab started to fabricate the final metal to ceramic prosthesis. The final prosthesis was permanently cemented in the patient's mouth three days after surgery. The fine penetration areas of basal implants showed satisfactory healing of the gingiva after surgery (Fig.4).

#### **Postoperative Care and Evaluation**

The patients were put on an antibiotic regime consisting of amoxicillin 500 mg three times a day for 5 days along with a chlorhexidine mouthrinse. The patients were asked to abstain from brushing on the surgical area for at least 1 week and the operated area was evaluated for healing, infection and any signs of ulceration and necrosis. Patients were reevaluated regularly to maintain stable and adequate occlusion.

#### **RESULTS**

After 1 year of function, the newly regenerated bone had remodeled into functional bone with trabeculae oriented perpendicular to the bone-implant interface. After 1 year,

CBCT imaging revealed that all implants were radiographically and clinically osseointegrated (Fig.5). The gingival tissues around each implant appeared healthy (no bleeding or inflammation).

#### **DISCUSSION**

The immediate loading dental implants are more predictable than before, (Misch, 1998; Del Fabbro *et al.*, 2006) though the chances of crestal bone loss are comparatively higher. (Chang *et al.*, 2006) It can be speculated that early loading may interfere in the formation of new bone in areas of necrotic bone (created by surgical trauma). (Narang *et al.*, 2014) The basal implants provide excellent primary stability along the vertical surface of these implants with no need for corticalization. So, the basal implants are well suited not only for immediate loading but also for immediate placement. (Werner and Thomas, 2005) In anterior maxillary region, four basal implant were placed. The implant offers the advantages of not requiring flap elevation (no open surgical procedure is necessary), can be carried out in a single sitting, and can be immediately loaded as well. (Stefan, 2005; Thomas Fabritius, 2007) The basal implants are single-piece implants with an apical compression thread. The compression screw design facilitates immediate

prosthetic loading, provided surgical placement was carried out correctly (restoration can be placed within 3 days or less). The basal implant procedures are less time consuming. Moreover, being a single-piece implant, the strength provided by the implant is excellent as there is no separate root portion and abutment portion. (Narang *et al.*, 2014) In the present case, basal implants were placed and loaded immediately, which showed promising results at a follow-up of 12 months.

### Conclusion

The installation of basal implants today is a routine procedure. The philosophy of this treatment differs from conventional implantological thinking, since the possibility of mounting prostheses does not depend on the presence of vertical bone, alveolar bone or the presence of bone in the area of the desired tooth. Also bridges made from acrylic mounted on frameworks of CoCr-Alloy which are based in BCS implants are one of the cheapest ways to meet the patients demands for fixed teeth. Since it is task of academic research to investigate and provide achievable means of establishing balanced, healthy oral function, further engagement in the BCS technique seems advisable.

### REFERENCES

- Ahmad Otoum, Thamer Bsoul. Basal screw implantology without sinus lifting. *Pakistan Oral & Dental Journal*, Vol 34, No. 3 (September 2014).p.414-416.
- Chang TL, Raoumanas ED, Klokkevold PR, Beumer J. Biomechanics, Treatment planning and prosthetic considerations. In: Newman MG, Takei HH, Klokkevold PR, Carranza FA, editors. 10th ed. *Clinical Periodontology: Saunders*, Louis 2006. p. 1167-81.
- Del Fabbro M, Testori T, Francetti L, Taschieri S, Weinstein R. Systematic review of survival rates for immediately loaded dental implants. *Int J Periodontics Restorative Dent.*, 2006;16:249-63.
- German & European Standard: DINEN 31902-1.
- Ihde S, Eber M. Case report: restoration of edentulous mandible with 4 BOI implants in an immediate load procedure. *Biomed Pap Med Fac Univ Palacky Olomouc Czech Repub.*, 2004 Dec;148(2):195-8.
- Misch CE, Qu Z, Bidez MW. Mechanical properties of trabecular bone in the human mandible. Implications of dental implant planning and surgical placement. *J Oral Maxillofac Surg.*, 1999;57:700-706.
- Misch CE, Qu Z, Bidez MW. Mechanical properties of trabecular bone in the human mandible. Implications of dental implant planning and surgical placement. *J Oral Maxillofac Surg.*, 1999;57:700-706.
- Misch CE. Non-functional immediate teeth in partially edentulous patients: A pilot study of 10 consecutive cases using the Maestro TM Dental Implant system. *Compendium* 1998;19:25-36.
- Narang S, Narang A, Jain K, Bhatia V. Multiple immediate implants placement with immediate loading. *Journal of Indian Society of Periodontology*, Vol 18, Issue 5, Sep-Oct 2014.p.648-50.
- Odin G, Misch CE, Binderman I, Scortecchi G. Fixed Rehabilitation of Severely Atrophic Jaws Using Immediately Loaded Basal Disk Implants After In Situ Bone Activation. *Journal of Oral Implantology.*, Vol. XXXVIII /No. Five/2012. P. 611-616.
- Scortecchi G, Misch CE, Benner KU. Implants and Restorative Dentistry. London, UK: Martin Dunitz; 2001:79-85.
- Stefan I. Principles of BOI. Berlin, Heidelberg: Springer-Verlag, 2005. p. 103.
- Thomas Fabritius, Traunreut Minimally-invasive procedures and immediate loading Clinical experience with the single-stage Kos implants: *Orale Implantol.*, 2/07.
- Werner M, Thomas F. Long-term study on immediate loading of one-piece KOS® implants with fixed complete dentures
- Yadav RS, Sangur R, Mahajan T, Rajanikant AV, Singh N, Singh R. An Alternative to Conventional Dental Implants: Basal Implants. *Rama Univ J Dent Sci.*, 2015 June;2(2): 22-28

\*\*\*\*\*