



## RESEARCH ARTICLE

### STUDY ON THE EXISTENCE OF POSTERIOR CONDYLAR FORAMEN AND THE MORPHOMETRY OF POSTERIOR CONDYLAR FOSSA AND JUGULAR FORAMEN

\*Anisha, A. Mahtani and <sup>2</sup>Dr. Thenmozhi M.S.

<sup>1</sup>I BDS, Saveetha Dental College, 162 P. H. Road Chennai Tamil Nadu 600077, India

<sup>2</sup>Department of Anatomy, Saveetha Dental College, 162 P. H. Road Chennai Tamil Nadu 600077

#### ARTICLE INFO

##### Article History:

Received 14<sup>th</sup> May, 2016  
Received in revised form  
23<sup>rd</sup> June, 2016  
Accepted 17<sup>th</sup> July, 2016  
Published online 20<sup>th</sup> August, 2016

##### Key words:

Jugular Foramen,  
Posterior condylar fossa,  
Posterior condylar foramen,  
Vernier caliper,  
Morphometry.

#### ABSTRACT

**Aim:** To analyze the existence of the posterior condylar foramen and the morphometry of the posterior condylar fossa and the jugular foramen.

**Objective:** To check the bilateral or unilateral existence of the posterior condylar foramen. To also observe variations in the measurements of the posterior condylar fossa and the jugular foramen using a vernier caliper.

**Introduction:** The condylar fossae are situated at either side of the foramen magnum behind the occipital condyles and accommodate the postero-superior part of the lateral mass of the atlas when the head is bent backwards. The fossa is best visualized radiologically. The posterior condylar foramen may or may not exist. The jugular foramen is located behind the carotid canal and is formed in front by the posterior portion of the temporal and behind the occipital. It is generally larger on the right than on the left side.

**Materials and methods:** The study was carried out using 40 dry skulls from the Anatomy department of Saveetha Dental College, Chennai, Tamil Nadu. The parameters were measured using a vernier caliper and a scale.

**Results:** 50% of the skulls contained the right posterior condylar foramen and 51% contained the left posterior condylar foramen. The mean value of the right and left width of the jugular foramina was found to be 13.3mm and 12.45mm respectively and the mean value of the antero-posterior diameter for the right and left jugular foramina are 10.05mm and 9.6mm respectively. Thus the right jugular foramen was found to be larger than the left. The mean value of the right and left width of the posterior condylar fossa was found to be 7.17mm and 7.35mm respectively and the mean value of the antero-posterior diameter for the right and left posterior condylar fossae are 5.4mm and 5.5mm respectively.

Copyright©2016, Anisha, A. Mahtani and Dr. Thenmozhi. This is an open access article distributed under the Creative Commons Attribution License, which permits unrestricted use, distribution, and reproduction in any medium, provided the original work is properly cited.

**Citation:** Anisha, A. Mahtani and Dr. Thenmozhi M.S. 2016. "Study on the existence of posterior condylar foramen and the morphometry of posterior condylar fossa and jugular foramen", *International Journal of Current Research*, 8, (08), 36211-36214.

## INTRODUCTION

The Posterior condylar fossae are situated on either side of the foramen magnum behind the occipital condyles (Lewis, 1957). The posterior condylar canal opens through a foramen into the fossa. It transmits an emissary vein from the suboccipital venous plexus to the sigmoid sinus or at times to the jugular bulb (Lewis, 1957). Posterior condylar foramen (PCF), the foramen that Posterior condylar vein passes through, is the largest emissary foramen in the retromastoid region (Mortazavi *et al.*, 2012; Pekcevik *et al.*, 2014 and Ginsberg, 1994).

\*Corresponding author: Anisha, A. Mahtani

I BDS, Saveetha Dental College, 162 P. H. Road Chennai Tamil Nadu 600077, India

The posterior condylar foramen may or may not be present. The condylar canal has a variable presence and is seen only in 50-60% of the cases (Craig Hacking, 2015). Resection of the rectus capitus posterior major and minor muscles reveals the bony recess leading to the posterior condylar canal, which is situated posterior and lateral to the occipital condyle (Lewis, 1957). The jugular foramen lies between the occipital bone and the petrous part of the temporal bone, and it is elongated and irregularly shaped (Pereira, 2010). It courses anteriorly, laterally, and inferiorly as it insinuates itself between the petrous temporal bone and the occipital bone (Craig Hacking, 2015). The jugular foramen is the chief route for the venous outflow from the skull. The glossopharyngeal, vagus and cranial part of spinal accessory nerve pass through this and exit the cranial cavity (Vijisha, 2013). The neural and vascular compartments are generally separated by a bone projection

called the intrajugular process (Hatiboglu, 1992; Prades *et al.*, 1994 and Williams, 1995). The jugular foramen is divided into two parts by a fibrous or bony septum, called the jugular spine, into the pars nervosa and the pars vascularis.

The pars nervosa is the anteromedial portion of the jugular foramen and is smaller than the larger, posterolateral pars vascularis. It contains the inferior petrosal sinus and the glossopharyngeal cranial nerve (CN IX). The inferior petrosal sinus drains the cavernous sinus and courses in the petro-occipital fissure prior to its exit through the pars nervosa and subsequent drainage into the jugular vein beneath the foramen. The glossopharyngeal nerve yields a tympanic branch (Jacobson's nerve) which reaches and supplies the middle ear along with the inferior tympanic artery via the inferior tympanic canaliculus which is occasionally seen at CT in cross section at the level of the carotico-jugular spine (Craig Hacking, 2015; Swartz, 1998 and Komune, 2015). The larger, posterolateral, pars vascularis contains the jugular bulb which is a venous expansion between the endocranial sigmoid sinus and the exocranial internal jugular vein, the vagus nerve (CN X) and the spinal accessory nerve (CN XI), (Craig Hacking, 2015; Swartz, 1998 and Komune, 2015). The vagus nerve yields an auricular branch (Arnold nerve) via the mastoid canaliculus on the lateral wall of the foramen adjacent to the mastoid segment of the facial nerve.

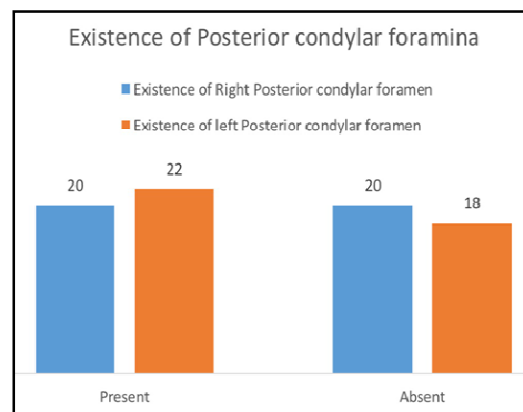
The jugular foramen is further divided into three parts. The petrous part through which the petrosal sinus passes, the intrajugular part through which the nerves pass and the sigmoid part through which the sigmoid sinus passes, (Craig Hacking, 2015; Swartz, 1998 and Komune, 2015). The intrajugular part is positioned between the sigmoid and petrosal parts, and is the site of bony prominences called the intrajugular processes on the opposing surfaces of the temporal and occipital bones. The size of the normal jugular foramen is remarkably variable and asymmetrical. The size and shape of the jugular foramen are associated to the size of the internal jugular vein and the presence or absence of a dome for superior bulb. The right foramen is frequently larger than the left. The dissimilarity in size of the two internal jugular veins is already noticeable in the human embryo at the 23 mm stage and perhaps is due to the differences in the pattern of development of the right and left brachiocephalic veins (Pereira, 2010). However, the normal foramen will always be well-corticated. Therefore, the bony margin (and not the size) of the foramen should guide diagnostic evaluation (Craig Hacking, 2015).

## MATERIALS AND METHODS

The study was carried out on 40 dry skulls from the Anatomy department of Saveetha Dental College, Chennai, Tamil Nadu. The morphometry of the posterior condylar fossa and the jugular foramen were measured. The width and length of the foramina were the parameters that were studied.

The existence of the posterior condylar foramina were also examined. The parameters were measured using a vernier caliper and a scale. (Refer Figure 3)

## RESULTS



Graph 1.

Table 1. Morphometry of jugular foramen

	Jugular Foramen			
	Width (mm)		Antero-Posterior diameter (mm)	
	Right	Left	Right	Left
	13	12	8	9
	13	13	9	8
	12	13	15	14
	14	13	13	14
	16	12	13	12
	17	12	13	12
	12	10	18	16
	12	13	6	5
	12	13	11	11
	8	10	6	7
	10	9	9	9
	12	14	7	7
	12	13	9	9
	10	10	9	9
	18	11	7	6
	17	11	15	14
	15	13	11	10
	15	10	12	10
	17	16	8	9
	18	17	9	10
	14	16	9	10
	14	13	9	9
	11	12	9	8
	15	10	14	10
	13	14	11	11
	11	14	10	9
	10	11	9	8
	14	12	10	11
	9	8	9	9
	16	13	10	11
	13	14	10	8
	15	16	10	9
	14	16	10	9
	18	11	9	8
	16	11	10	9
	12	10	9	8
	11	10	9	8
	12	11	8	9
	10	12	9	8
	14	19	10	11
Mean	13.375	12.45	10.05	9.6
Std.dev	2.598692965	2.341925572	2.480177827	2.22802661
Mode	12	13	9	9

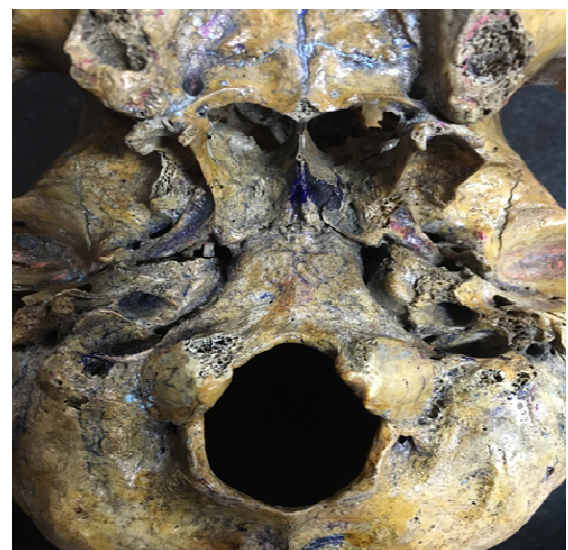
**Table 2. Morphometry of posterior condylar fossa**

	Posterior Condylar Fossa			
	Width (mm)		Artero-Posterior diameter(mm)	
	Right	Left	Right	Left
	10	11	8	7
	11	8	9	7
	7	5	5	4
	6	5	7	6
	6	5	6	5
	6	8	6	9
	5	4	2	2
	7	6	5	4
	3	2	2	2
	4	4	2	2
	7	6	6	5
	9	9	6	6
	6	8	5	9
	9	9	7	7
	3	2	2	2
	6	8	5	5
	7	8	5	5
	7	9	6	7
	9	9	7	6
	9	8	7	6
	9	13	8	8
	9	8	6	7
	6	6	3	2
	8	9	7	6
	2	5	2	4
	7	8	5	4
	8	8	7	6
	8	7	2	3
	3	2	2	2
	8	9	4	4
	6	8	6	7
	6	7	4	5
	6	7	7	6
	6	7	5	6
	10	8	7	6
	11	12	7	8
	10	8	7	8
	10	9	7	8
	9	10	6	7
	8	9	7	8
Mean	7.175	7.35	5.425	5.525
Std.dev	2.24050704	2.465661611	1.97273076	2.06295158
Mode	6	8	7	6

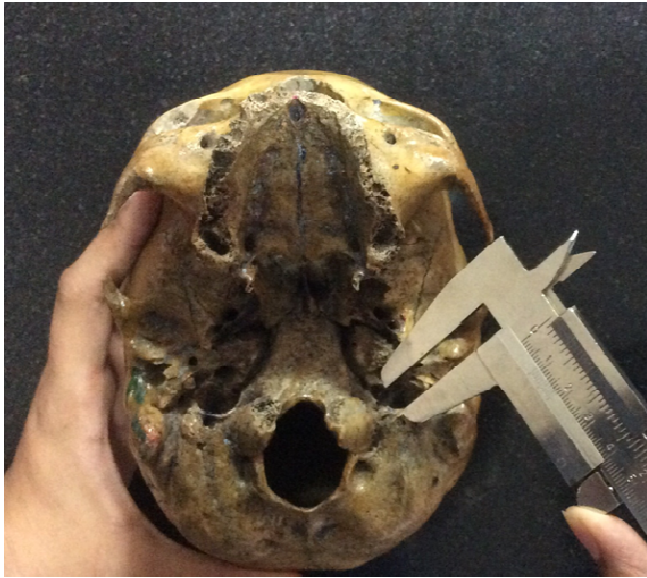
## DISCUSSION

As the largest emissary foramen in the retromastoid region, the morphological features of the posterior condylar foramen are remarkable specifically for posterior cranial fossa neurosurgical procedures (Mortazavi, 2012).

Results of our study revealed that the Right Posterior condylar foramen was present in 50% of the skulls and the Left Posterior condylar foramen was present in 51% of the skulls. (Refer Graph 1). Ginsberg observed the posterior condylar canal to be bilateral in 55.9% and unilateral in 17.6% (Craig Hacking, 2015). Boyd found the posterior condylar canal with an incidence of 77% unilaterally. [8](Refer Figure 1). Krause discovered that condylar canal was present bilaterally in 21% and unilaterally in 38% (Prades *et al.*, 1994). Our study revealed that the mean value of the width of the right jugular foramen was found to be 13.3mm and the left jugular foramen was 12.45mm. (Refer Table 1) Osunwoke *et al.*, Idowu, Vijisha *et al.* found the mean width of the right and left jugular foramen to be 9.34, 10.22, 12.13 mm and 7.54, 9.57, 9.27 mm respectively. This study was carried out on Nigerians and North Indians (Pereira, 2010). However, Gupta C, Kurian P *et al.* found the mean width of right and left side as 16.52 and 16.02 mm, respectively.

**Figure 1. Right Posterior condylar Foramen****Figure 2. The Jugular foramina**





**Figure 3. Measuring the jugular foramen with the vernier caliper**

This study was carried out on South Indians (Gupta, 2014). Pereira *et al.* found the mean right and left A-P diameter of jugular foramen as 9.21 and 8.65. This study was carried out on the Brazilian population.<sup>[6]</sup> In the study carried out by Gupta C, Kurian P *et al.* the A-P diameter values are 11.22 and 9.52.<sup>[17]</sup> Our study showed the mean value of the antero-posterior diameter of the right jugular foramen to be 10.05 and the left jugular foramen to be 9.6. (Refer Table 2) The right jugular foramen was experimentally found to be larger than the left. (Refer Figure 2). According to the present study, the width of the right posterior condylar fossa was found to be 7.17 and the left posterior condylar fossa was 7.35. The antero-posterior diameter of the right posterior condylar fossa was found to be 5.4 and the left posterior condylar fossa was found to be 5.5. (Refer Table 2) The base of the fossa is not always of uniform thickness, and irregular densities occasionally result within the more translucent fossa shadow. Small ridges also may occur within the fossa. The fossa may be large and may be present only unilaterally. These asymmetries and variations have no clinical significance. The posterior condylar canal opens at the groove for sigmoid sinus, posterolateral to the jugular foramen in the posterior cranial fossa. These anomalous foramina also open at the same location in the posterior cranial fossa. This leads to the speculation that these anomalous foramina might be acting as additional source of drainage of the intracranial veins into extracranial veins.

### Conclusion

The posterior condylar foramen serves as a communication between the intracranial and extracranial venous drainage. Hence during surgery in the occipital region, care must be taken. Since the jugular foramen transmits the internal jugular vein and the IX, X and XI cranial nerves, the importance of the foramen was established by the studying the morphometry of it.

### REFERENCES

- Chandni Gupta, Punnose Kurian, and Antony Sylvan D'Souza. 2014. A morphological and morphometric study of jugular foramen in dry skulls with its clinical implications, *J Craniovertebr Junction Spine*. Jul-Sept; 5(3): 118-121.
- Craig Hacking, Prashant Mugdal. Condylar canal. Radiopedia.org
- Craig Hacking, Prashant Mugdal. Jugular Foramen. Radiopedia.org
- Ginsberg, L.E. 1994. The posterior condylar canal. *Am J Neuroradiol*, 5:969-72.
- Gupta, C., Kurian, P., Seva, K.N., Kalthur, S.G., D'Souza, A.S. 2014. A morphological and morphometric study of jugular foramen in dry skulls with its clinical implications. *Journal of Craniovertebral Junction & Spine*. 5(3):118-121.
- Hatiboglu, M.T., Anil, A. 1992. Structural variations in the jugular foramen of the human skull. *J Anat.*, 180:191-6. [PMC free article] [PubMed]
- Khanday, S., Subramanian, R.M., Rajendran, M., Hassan, A.U., Khan, S.H. 2013. Morphological and morphometric study of jugular Foramen in South Indian population. *Int J Anat Res.*, 1:122-7.
- Komune, N., Matsushima, K., Matsushima, T. et al. 2015. Surgical approaches to jugular foramen schwannomas: An anatomic study. *Head Neck*. 2015
- Lewis, L. Haas, M.D. 1957. The posterior condylar fossa, foramen and canal and the Jugular foramen. *Radiology*. October, Volume 69, Issue 4
- Mortaazavi, M., Tubbs, S., Reich, S., Verma, K., Shoja, M., Zurada, A., Benninger, B., Loukas, M., Gadol, C. 2012. Anatomy and pathology of the cranial emissary veins: a review with surgical implications. *Neurosurgery*, 70: 1312-9.
- Mortaazavi, M., Tubbs, S., Reich, S., Verma, K., Shoja, M., Zurada, A., Benninger, B., Loukas, M., Gadol, C. 2012. Anatomy and pathology of the cranial emissary veins: a review with surgical implications. *Neurosurgery*, 70:1312-9.
- Pekcevik, Y., Sahin, H., Pekcevik, R. 2014. Prevalence of clinically important posterior fossa emissary veins on CT angiography. *J Neurosci Rural Pract.*, 5:135-8.
- Pereira, G.A., Lopes, P.T., Santos, A.M. 2010. Morphometric aspects of the jugular foramen in dry skulls of adult individuals in Southern Brazil. *J Morphol Sci*. 2010; 27:3-5.
- Prades, J.M., Martin, C.H., Veyret, C.H., Merzougui, N., Chelikh, L. 1994. Anatomic basis of the infratemporal approach of the jugular foramen. *Surg Radiol Anat.*, 16:11-20. [PubMed]
- Swartz, J.D., Harnsberger, H.R. 1998. Imaging of the temporal bone. George Thieme Verlag.
- Vijisha, P, Bilodi, A.K. 2013. Lokeshmaran Morphometric study of jugular foramen in Tamil Nadu region. *Natl J Clin Anat*. 2:71-4.
- Williams, P., Warwick, R., Dyson, M., Bannister, L. 1995. *Gray Anatomia*. 37th ed. Vol. 2. Rio de Janeiro: Guanabara Koogan., pp. 329-31.

\*\*\*\*\*