



## CASE REPORT

### GEOGRAPHIC TONGUE –A CASE REPORT

<sup>\*</sup><sup>1</sup>Dr. Esha Singh, <sup>2</sup>Dr. Kashish Chakraborty and <sup>3</sup>Dr. Cheena Singh

<sup>1</sup>Department of Oral Pathology, Postgraduate Institute of Dental Sciences, Rohtak

<sup>2</sup>Ex- Demonstrator, Government Medical Hospital and College, Sector 32, Chandigarh

<sup>3</sup>Demonstrator, Department of Oral Medicine and Radiology, Postgraduate Institute of Dental Sciences, Rohtak

#### ARTICLE INFO

##### Article History:

Received 18<sup>th</sup> July, 2016

Received in revised form

29<sup>th</sup> August, 2016

Accepted 05<sup>th</sup> September, 2016

Published online 30<sup>th</sup> October, 2016

##### Key words:

Depapillation of tongue, Stress,  
Filliform papilla, Psoriasis.

#### ABSTRACT

We report here a case of geographic tongue associated with chronic stress in a 60 year old male patient. He noticed the change in colour on tongue and the patches were also changing their positions. Mild burning sensation was reported and for curing this topical anesthetics were given.

Copyright © 2016, Dr. Esha Singh et al. This is an open access article distributed under the Creative Commons Attribution License, which permits unrestricted use, distribution, and reproduction in any medium, provided the original work is properly cited.

Citation: Dr. Esha Singh, Dr. Kashish Chakraborty and Dr. Cheena Singh, 2016. "Geographic tongue –A case report", *International Journal of Current Research*, 8, (10), 40520-40521.

## INTRODUCTION

Geographic tongue is an asymptomatic inflammatory disorder that usually occurs on the dorsal surface and lateral border of tongue (Assimakopoulos *et al.*, 2002). The pinkish-red areas of different of size are surrounded, at least in part, by an irregular white border. The appearance of the affected portion of the tongue results from loss of the conical shaped projections (filiform papilla) which normally cover the tongue's surface (Shahjad *et al.*, 2014). Occasionally, similar appearing lesions occur on other oral sites, such as the palate, cheeks, under the tongue or on the gingival (Borrie *et al.*, 2007) However, its etiopathogenesis is not very clear. Thus, here, we present a case of geographic tongue in a 60 year old male patient, emphasizing on its etiopathogenesis.

### Case Report

A 60 year old male patient came to the outpatient department, with a complaint of red patch on the tongue and has mild burning sensation on eating spicy food for past 2-4 months. On examination of tongue, few pinkish-red depapillated or atrophic raised patches surrounded by white serpentine borders

were seen on the dorsal surface and lateral border of the tongue (Fig. 1, 2 and 3). When proper history was recorded, patient reveals that these patches kept changing their position. Patient was under stress for past few months and it increased when he noticed the changes in his tongue. Hence, on the basis of history and clinical findings, a diagnosis of geographic tongue was made.

## DISCUSSION

Geographic tongue is a very common condition. It can occur at any time in life. Estimation of affected people is 2.5% of the population of the India. It tends to vary in color, shape and size so the name of the condition. Other names of geographic tongue are benign migratory glossitis, wandering rash, erythema migrans and migrant glossitis. Multiple affected areas are commonly seen. It may also completely disappear for a period of time and then reappear. Fissured tongue and geographic tongue commonly occur together (Bruna, 2015). The cause of geographic tongue is unknown. Several factors have been proposed as possible causes such as emotional stress, psychological factors, habits, allergies, diabetes and hormonal disturbances. However, none of these factors have been conclusively linked to geographic tongue. In our patient stress could be the cause of Geographic tongue.

\*Corresponding author: Dr. Esha Singh,

Department of Oral Pathology, Postgraduate Institute of Dental Sciences, Rohtak

### Clinical Pictures of Geographic Tongue

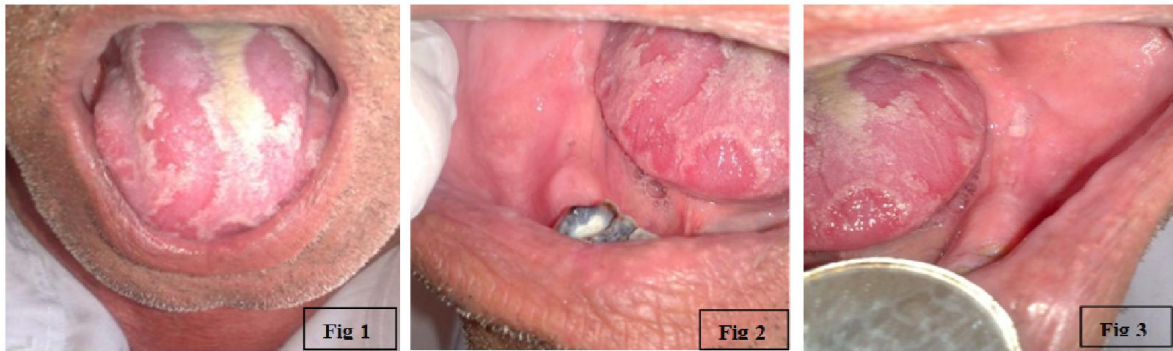


Fig 1, 2 & 3. Pinkish –Red irregular depapillated patches

A relationship between geographic tongue and psoriasis (a skin disease) has been reported. Geographic tongue was found to be more frequent in patients with psoriasis. Some consider geographic tongue an oral form of psoriasis (Femino, 2001). A study done by Ebrahimi *et al* on relation between stress and geographic tongue says that psychosomatic factors appear to play a significant role in its etiology. In another study by Redmen *et al* a higher prevalence of geographic tongue is found in mentally ill patients as compared to university students. They also noticed that students under emotional stress tended to have more severe lesions (Ebrahimi, 2010). In most cases, a biopsy is not necessary to establish the diagnosis because of the identifiable clinical findings and history. But if biopsy sample was taken, the histopathologic appearance of geographic tongue is quite similar to psoriasis i.e. hyperparakeratosis, acanthosis, subepithelial lymphocyte inflammatory infiltration, neutrophils and granulocytes migration into the superficial epithelial layer resulting in formation of superficial microabscesses, similar to the Monro's microabscesses as seen in pustular psoriasis (Masaya Ishibashi *et al.*, 2010; Tarakji *et al.*, 2014). Some other pustular diseases affect the oral mucosa like parulis at the orifice of a fistula extending to the surface from a dental or periodontal abscess, pyostomatitis vegetans and stomatitis herpetiformis. Such lesions show neutrophilic infiltration in the basal layer of the epithelium or underlying connective tissue unlike oral psoriasis (Tarakji, 2014). There is also subcorneal pustular mucositis in the mouth, but the separation of the keratin layer from the spinous layer helps to differentiate it from migratory glossitis (Tarakji, 2014). Geographic tongue is usually asymptomatic, occasionally it may cause a burning sensation of the tongue. (Wadhawan *et al.*, 2013) Therefore, in most cases, there is no need for treatment of this condition. If burning sensation persists, in this situation, topical anesthetics can be used for surface numbing. (Kumar *et al.*, 2015) Geographic tongue is benign condition and till date, no malignant potential has been reported regarding geographic tongue causing cancer.

### Conclusion

Though it is a very commonly occurring lesion, its etiopathogenesis is still controversial so more studies and case reports are required emphasizing on its pathogenesis.

### REFERENCES

- Assimakopoulos, D. *et al.* 2002. " Benign migratory glossitis or geographic tongue: An enigmatic oral lesion, Vol.113(9), pg 751-755, December.
- Borrie, F., Musthyala, R., Macintyre, D. 2007. "Ectopic Geographic tongue –a case report" *Dent update*, Vol. 34(2); pg-121-2, March, 2007
- Bruna L.S. *et al* "Geographic tongue and Fissured tongue in 348 patients with Psoriasis: Correlation with Disease severity." *The Scientific World Journal*, 2015.
- Ebrahimi H, Pourshahidi S, Andisheh A and Bakhshi S. "Relationship of Geographic tongue and Stress." *Iranian Red Crescent Medical Journal*, Vol 12 (3) May 2010.
- Femino, F. 2001. "Geographic tongue (migrant glossitis) and psoriasis" *Minerva Stomatol* Vol. 50(6), pg 213-7, June.
- Kumar T, Puri G, Aravinda K, Arora N. "Benign migratory glossitis: A rare presentation of a common disorder." *Journal of Indian Academy of Oral Medicine and Radiology*, Vol-27 (1) pp:112-114; Oct 2015
- Masaya Ishibashi, Genichi Tojo, Masahiko Watanabe, Takahiro Tamabuchi, Takashi Masu, Setsuya Aiba. "Geographic tongue treated with topical tacrolimus". *J Dermatol Case Rep.*, 2010; 4:57-59.
- Shahjad M., Sattar A and Farhan Ali SM. "Geographic tongue: Case report and literature review" *Pakistan Oral and Dental Journal*, Vol.3 (Sept-2014)
- Tarakji B., Umair A., Babaker Z., Azzeghaiby SN, Gazal G., and Sarraj F. "Relation Between Psoriasis and Geographic Tongue" *Journal of Clinical Diagnostic and Research*, 2014 Nov; 8(11)
- Wadhawan, Richa; Jhakhar, Rohit; Sharma, Sumeet; Nagaraju K.; Malviya, Atish "Symptomatic Geographic Tongue in a 3-year-old Child: A Rarity. *Indian Journal of Stomatology*, 2013, Vol. 4 Issue 4, p163-165. 3p.

\*\*\*\*\*