



CASE REPORT

ODONTOGENIC MYXOMA OF THE MAXILLA: A REPORT OF A RARE CASE WITH REVIEW OF LITERATURE

*Dr. Kavita R. Wadde, Dr. Jayant S landage, Dr. Monali Ghodke and Dr. Saroj Kumar Sethy

Department of Oral and Maxillofacial Surgery, GDC & H, Mumbai, India

ARTICLE INFO

Article History:

Received 04th August, 2016
Received in revised form
29th September, 2016
Accepted 17th October, 2016
Published online 30th November, 2016

Key words:

Odontogenic Myxoma,
Maxilla, Multilocular,
Benign neoplasm,
Conservative treatment.

ABSTRACT

Odontogenic myxoma (OM) is a rare and locally invasive benign neoplasm found exclusively in the jaws. It commonly occur in the second and third decade. The mandible is more involved than maxilla. The lesion often grows without symptoms and presents as a painless swelling. The radiographic features are variable, and the diagnosis is therefore not easy. Radiographically myxomas appear as unilocular or multilocular radiolucencies. The radiolucent defect can contain thin, wispy trabeculae of residual bone which are often arranged at right angles to each other. The Histopathology of myxomas shows loosely arranged spindle-shaped stellate cells and few areas of inactive odontogenic epithelium in a mucoid intercellular substance. OM tumor cells are mesenchymal in origin and express vimentin and muscle- specific actin. In OM, Enucleation and curettage has proved an effective approach. This paper highlight a case of 13 years old male of OM in the maxilla and short review of the current literature on its pathogenesis, radiographic features, histopathology and surgical management.

Copyright©2016, Kavita R. Wadde et al. This is an open access article distributed under the Creative Commons Attribution License, which permits unrestricted use, distribution, and reproduction in any medium, provided the original work is properly cited.

Citation: Dr. Kavita R. Wadde, Dr. Jayant S landage, Dr. Monali Ghodke and Dr. Saroj Kumar Sethy, 2016. "Odontogenic Myxoma of the maxilla: A report of a rare case with review of Literature", *International Journal of Current Research*, 8, (11), 41779-41782.

INTRODUCTION

Myxomas can be found in various sites in the body including the skin and subcutaneous tissue, heart (mainly in the left atrium), and also in various sites of the head and neck (Bruno Ramos Chrcanovic *et al.*, 2010). OM of the jaw was first described by Thoma and Goldman (Thoma and Goldman, 1947) in 1947. OM is defined as an intraosseous neoplasm characterised by stellate and spindle-shaped cells embedded in an abundant myxoid or mucoid extracellular matrix (Leon Barnes *et al.*, 2005). The frequency of OM varies in different parts of the world between 3-20% of all odontogenic tumors. It is the third most frequent odontogenic tumor (after odontoma and ameloblastoma). An annual incidence of 0.07 per million has been reported (Leon Barnes *et al.*, 2005; Simon *et al.*, 2004). The majority is diagnosed in the 2nd- 4th decades and slightly more common in females. OM is a locally invasive neoplasm that shows little encapsulation and often extends through the bone (Iezzi *et al.*, 2007). Two-thirds of OMs are located in the mandibular molar region. The maxillary lesions tend to obliterate the maxillary sinuses as an early feature. It causes painless expansion, cortical perforation and sometimes unilateral sinonasal obliteration which may mimic nasal polyposis³. Radiologically OM may appear as unilocular or multilocular radiolucency with a "honeycomb" "soap bubble" or "tennis racket" pattern with cortical expansion and tooth

displacement (Bruno Ramos Chrcanovic *et al.*, 2010). Variations in radiographic presentation make a radiological differential interpretation of OM challenging because the radiographic features overlap with those of other benign and malignant neoplasms. It may show a mixed radiopaque-radiolucent appearance, which endorsed with the foci of calcification. It was suggest that this appearance may be due to residual bone and not to new bone formation, and therefore it was proposed that it should be considered in differential diagnosis of mixed radiolucent-radiopaque lesion. Differential diagnosis includes ameloblastoma, odontogenic Keratocyst, intraosseous haemangioma, aneurysmal bone cyst, glandular odontogenic cyst, central giant cell granuloma, cherubism, metastatic tumor, and in case of unilocular lesion, simple cyst (Bruno Ramos Chrcanovic *et al.*, 2010). OM may originate from either mesenchymal element of the dental papillae, dental follicle, periodontal membrane or non-dental mesenchyme. Also myxoma located in the soft tissue of head and neck has been reported^{5,6}. Pathologic examination confirms a true neoplasm composed of stellate cells set in a loose myxoid stroma. It is important to differentiate a myxoma, which is a benign lesion, from a malignant lesion with myxoid areas. The differential diagnoses include any lesion with myxoid change. Most important, myxoma of the bone must be distinguished from myxoid chondrosarcoma and rhabdomyosarcoma (embryonal, botryoid type) other differential diagnosis includes chondroblastoma, chondromyxoid fibroma, osteochondromyxoma, and neurofibroma with myxoid change⁷.

*Corresponding author: Dr. Kavita R. Wadde,
Department of Oral and Maxillofacial Surgery, GDC & H, Mumbai, India.

The treatment of myxoma of bone has been controversial. The surgical treatment for myxoma of bone has included Enucleation and curettage, peripheral resection with removal of the lesion with 1-10 mm bony margins. The purpose of the present article is to present one case that was treated in the department of oral and maxillofacial surgery in govt. dental college and hospital Mumbai, emphasizing a review on the differential diagnosis related to radiological findings, histological features and surgical treatment.

CASE REPORT

A 13 year old male child was referred to our department of Oral and Maxillofacial Surgery. Govt. Dental College and Hospital Mumbai, with a history of slowly enlarging right maxillary swelling since one year. The patient denied bleeding, mucosal ulceration, or paraesthesia. Extra oral examination shows a diffused swelling in the right infraorbital region obliterating a nasolabial fold and extending posteriorly in the posterior maxillary region. (Fig1) Intra oral examination revealed swelling extending from right canine region to right maxillary tuberosity and the buccal vestibule was completely obliterated. There was no expansion at right palate. The mucosa overlying the area of the lesion was normal. The rest of clinical head and neck examination was unremarkable. No significant medical history was present. A panoramic radiograph was taken which showed radiolucent lesion in the right maxilla with interlaced bone trabeculae resulting in multilocular appearance with impacted canine.

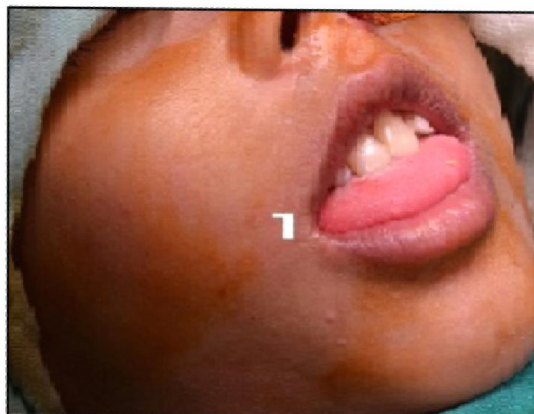


Fig. 1. Pre-operative aspect of the patient, showing swelling in the right infra-orbital region and extending posteriorly

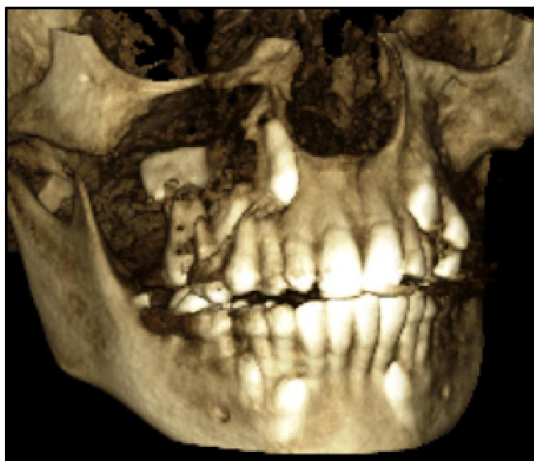

Fig. 2- Computed tomography showing a large mass involving the right maxillary sinus with bone destruction

A computed tomography showed a large mass involving the right maxillary sinus with destruction of bony margin of the anterior and lateral right maxillary sinus wall. (Fig. 2,3,4).

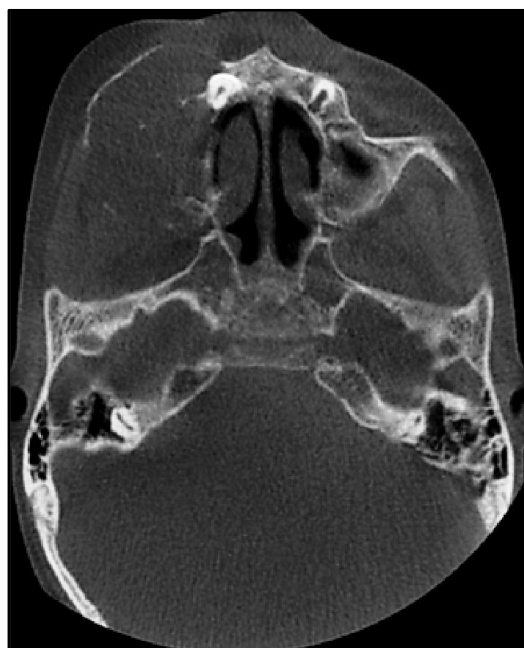

Fig. 3. CT-Axial view showing labial and buccal expansion

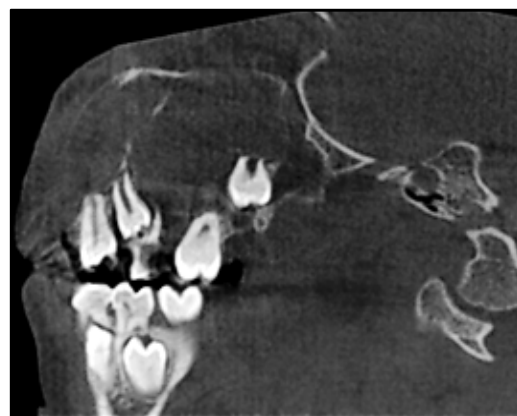

Fig. 4. CT-Sagittal view showing multiple impacted teeth

Based on the clinical findings. A benign odontogenic tumor was considered. The incisional biopsy was taken. The Histopathological report was no conclusive and hence the treatment was decided for Enucleation and curettage. The patient was prepared for all investigations. Surgery was planned under general anaesthesia. Patient was scrubbed and draped in routine surgical manner, crevicular incision was taken with two releasing incision, mucoperiosteal flap was reflected and tumor mass was exposed. (Fig.5) There was a definite delineation between tumor mass and the mucosal layer; hence it shows encapsulation of tumor mass within the bone. (Fig6) The entire tumor mass was removed and curettage was done. (Fig7,8) The tumor mass was sent for histopathological examination. The macroscopic appearance of tumor mass was grayish-white, glistening, firm, mucoid surface with semi-gelatinous consistency. (Fig9) Histopathological findings of OM tumor was loose, abundant mucoid stroma which contains rounded, spindle-shaped cells. (Fig10) The tumor cells are evenly spaced within a fine fibrillar mucinous matrix. Fewer amounts of collagen fiber and inflammatory infiltration was rarely seen.

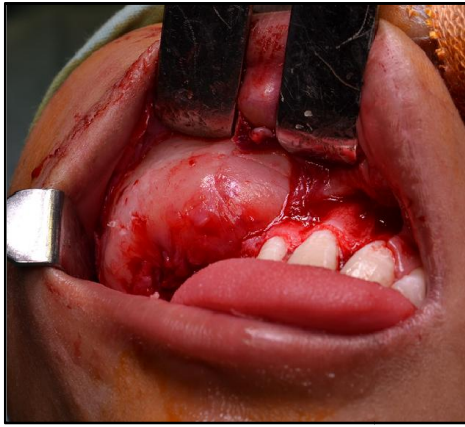

Fig. 5. Intra-operatively, surgical exposure of the tumour mass

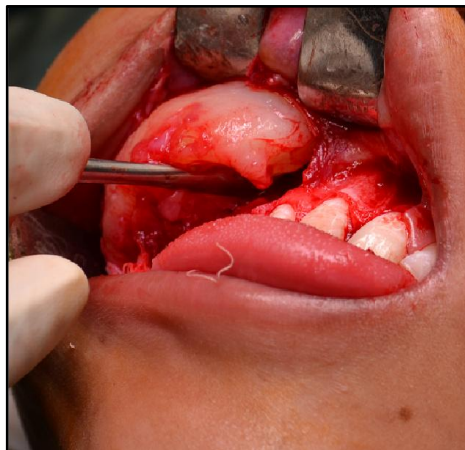

Fig. 6. Encapsulation of the tumour mass

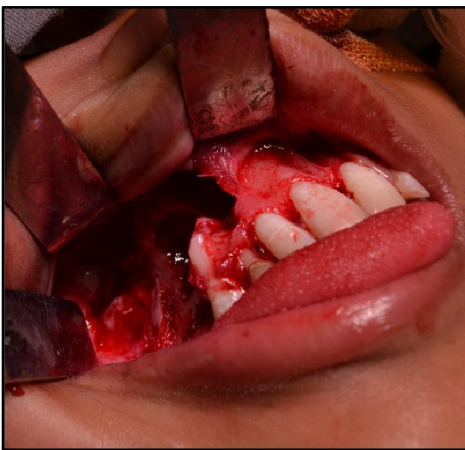

Fig. 7. Removal of the tumour

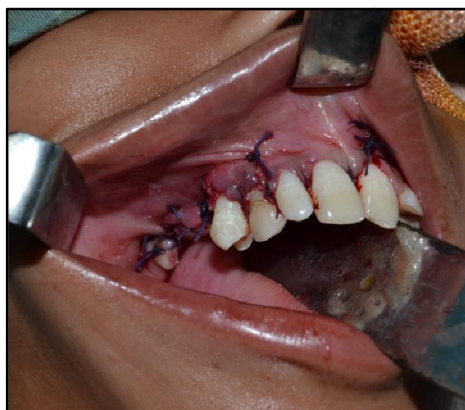

Fig. 8. Closure of the lesion

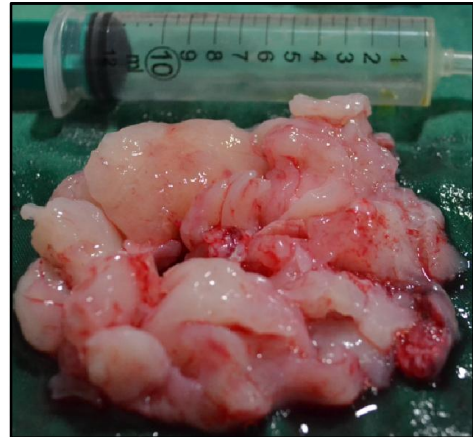

Fig. 9. Gross specimen showing a white gelatinous mass

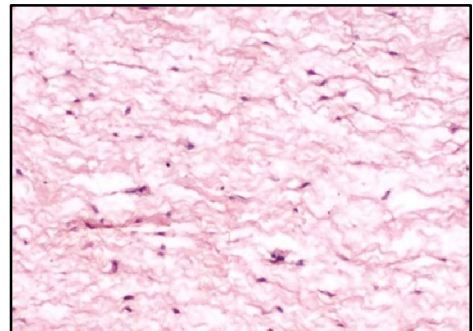


Fig. 10. A loose, abundant mucoïd stroma showing rounded and spindle shaped cells

DISCUSSION

Myxomas were first described by Virchow in 1871. Myxomas of the jaws were identified by Thoma in 1954. In the head and neck, two forms of myxomas or fibromyxomas are recognized: one is derived from the facial skeleton; the other is derived from the soft tissue. Myxoma of bone exclusive of the jaws and facial skeleton is nearly non-existent. The uncertainty that the myxoma is strictly an odontogenic lesion, sustained by its origin in extragnathic locations and nontooth bearing area of the jaws. Although the evidence is mainly circumstantial, support of an odontogenic origin has been postulated by: (1) It's almost exclusive occurrence in the tooth bearing areas of the jaws. (2) Its frequent occurrence in the young individuals, (3) It's common association with an unerupted tooth or a developmentally absent tooth, (4) It's histologic resemblance to dental mesenchyme, especially the dental papilla, and (5) the occasional presence of sparse amounts of odontogenic epithelium⁸. OM is regarded as a locally invasive tumor that does not metastasize and exhibits slow and asymptomatic expansion, sometimes resulting in perforation of the cortical borders of the affected bone (Abiose *et al.*, 1987). In many cases, these lesions are diagnosed accidentally by a routine dental checkup, and patients are usually in their second or third decade of life in almost 60% of the cases (Lo Muzion *et al.*, 1996; Li *et al.*, 2006). External and internal cortical displacement can be very evident, with bone destruction, seen in the CT of our case, with significant expansion of the maxillary sinus. Our case showed encroachment on the maxillary sinus only. This finding is supported in the literature, where it is reported that maxillary lesions encroach upon the maxillary sinus; however, lesions infiltrating the nasal cavity are rare (MacDonald-Jankowsky *et al.*, 2002). On CT images, the low density area may corresponds to the area with the

abundant mucoid component. The solid portion of the tumor is reported to be rich in collagen fiber and may correspond to the enhanced area seen on CT images. Histologically, the myxoma is composed of loosely arranged spindle, rounded and stellate-shaped cells with a lightly eosinophilic cytoplasm in a mucoid rich (myxoid) intercellular matrix. The myxoid matrix is rich in hyaluronic acid and chondroitin sulphate; myxomas pervade bone possibly as a result of the large content of hyaluronic acid (Priya Sar Thomas *et al.*, 2011).

The microscopic assessment of a poorly circumscribed myxoid proliferation outside bone is complex. The most likely diagnoses of these proliferation in the oral cavity include a myxoid area in a pleomorphic adenoma, myxoid change in a fibrosarcoma or plexiform neurofibroma, myxoid liposarcoma, botryoid type embryonal rhabdomyosarcoma, myxoid type chondrosarcoma, nerve sheath myxoma and chondromyxoid fibroma. Microscopic examination of a representative biopsy is important for the accurate diagnosis of myxoid soft tissue neoplasms in any location. OMs show little encapsulation and the growth may be quite rapid due to the accumulation of mucoid ground substance, thereby mimicking an aggressive neoplasm¹¹. In immunohistochemical findings, OM tumor cells are mesenchymal and express vimentin; occasional positivity to S-100 protein and muscle-specific actin is found. The matrix exhibits different proteins, mostly type I and type VI collagen, tenascin, fibronectin, and proteoglycans; OM tumor cells have been characterized as secretory (Peter, 2004). The current recommended therapy depends on the size of the lesion, its nature and behaviour. Treatment can vary from Curettage, Enucleation to Radical Excision, Enucleation followed by thorough curettage, that ensures complete removal remains the treatment of choice unless the clinical behaviour is usually aggressive (Yoav LEISER *et al.*, 2009). Collaboration of an experience pathologist is essential, since these diagnoses may lead to either surgery or a more conservative treatment and follow up must be restricted with imaging to detect any early recurrence. A follow up period is clearly also necessary. It has been recommended that this case is most likely to recur. Rocha et al suggested that 5 years of surveillance is needed to confirm successful excision but that ideally follow up should be maintained indefinitely (Yoko Kawase-Koga *et al.*, 2014). Although our young patient undergo surgery more conservatively and follow up was done for three years. There have been no clinical or radiologic signs of recurrence.

Conclusion

The successful clinical management of this case and our systemic review of the literature should help to inform the treatment decisions for odontogenic myxoma to minimising the risk of recurrence, while adapting a less invasive surgical approach whenever possible.

REFERENCES

- Barnes, L. 2001. Tumours and tumour-like lesions of the soft tissues. In: Barnes L, editor. Surgical pathology of the head and neck. New York: Dekker, p. 948-54.
- Bruno Ramos Chrcanovic, Marcio Bruno Figueiredo do Amaral, Helenice de Andrade Marigo, and Belini Freire-Maia, 2010. An expanded odontogenic myxoma in maxilla. *Stomatologija, Baltic Dental and Maxillofacial Journal*, 12: 122-8.
- Erich J. Raubenheimer, Claudia E. Noffke, 2012. Peripheral Odontogenic Myxoma: A Review of the Literature and Report of Two Cases. *J. Maxillofac. Oral Surg.*, 11(1):101-104
- Iezzi, G., A. Piattelli, C. Rubini, L. Artese, M. Fioroni, F. 2007. Carinici, MIB-1, Bcl-2 and p53 in odontogenic myxoma of the jaws, *Acta otorhinolaryngologica italic*, 27:237-242.
- Leon Barnes, John W. Eveson, Peter Reichart, David Sidransky, Pathology and Genetics, Head and Neck Tumors, 2005. *World Health Organization Classification of Tumors.*, p-316.
- Leopoldo, E. Landa, Marc H. Hedrick, Nepomuceno-Perz and George C. Sotereanos, 2002. Recurrent Myxoma of the zygoma: A case report. *J Oral Maxillofac Surg.*, 60:704-708.
- MacDonald-Jankowsky, D.S., Yeung, R., Lee, K.M., Li, T.K.L. 2002. Odontogenic myxoma in the Hong Kong Chinese: clinic radiological presentation and systemic review. *Dentomaxillofac Radiol.*, 31:71-83
- Peter A. Reichart, Hans P. Philipsen, 2004. Odontogenic Tumors and Allied Lesions, 189-196.
- Priya Sar Thomas, Subhas Babu G, Chandni Mishra, Anusha RL, Shishir Shetty, 2011. Odontogenic Myxoma: Report of Two Cases with Review of Literature. *Journal of Indian Academy of Oral Medicine and Radiology*, April-June, 23(2):143-146
- Simon, E.N., Merckx, M.A., Vuhahula, E., Ngassapa, D., Stoelinga, P.J. 2004. Odontogenic myxoma: a clinicopathologic study of 33 cases. *Int J Oral Maxillofac Surg.*, 33: 333-7.
- Thoma, K.H., Goldman, H.M. 1947. Central myxoma of the jaws. *Am J Orthop.*, 33:532-40.
- Yoav LEISER, Imad ABU-EL-NAAJ, Micha PELED, 2009. Odontogenic myxoma- A case series and review of the surgical management. *Journal of Cranio-Maxillofacial Surgery*, 37,206-209
- Yoko Kawase-Koga, Hideto Saijo, Kazuhito Hoshi, Tsuyoshi Takato and Yoshiyuki, 2014. Surgical management of odontogenic myxoma: a case report and review of the literature. *Biomedical Research Notes.*, 7:214
