



## CASE STUDY

### DENTAL IMPLANT THERAPY IN GENERALIZED AGGRESSIVE PERIODONTITIS

Dr. Shantipriya Reddy, Dr. Prasad, \*Dr. Abis Amir, Dr. Huzaifa Rashid and Dr. Vimal, S. K.

Department of Periodontics, Dr Syamala Reddy Dental College and Hospital, Bengaluru

#### ARTICLE INFO

##### Article History:

Received 27<sup>th</sup> August, 2016  
Received in revised form  
10<sup>th</sup> September, 2016  
Accepted 15<sup>th</sup> October, 2016  
Published online 30<sup>th</sup> November, 2016

##### Key words:

Generalized aggressive periodontitis, Implant.

Copyright©2016, Dr. Shantipriya Reddy et al. This is an open access article distributed under the Creative Commons Attribution License, which permits unrestricted use, distribution, and reproduction in any medium, provided the original work is properly cited.

Citation: Dr. Shantipriya Reddy, Dr. Prasad, Dr. Abis Amir, Dr. Huzaifa Rashid and Dr. Vimal, S. K. 2016. "Dental implant therapy in generalized aggressive periodontitis", *International Journal of Current Research*, 8, (11), 42350-42353.

#### ABSTRACT

Generalized aggressive periodontitis is a form of periodontitis which shows rapid destruction of periodontal tissues. Subjects tend to lose their teeth early in life due to the severity of the destruction and it often has led to challenge in prosthetic rehabilitation of such patients. In the present study two case have been discussed which were diagnosed with generalized aggressive periodontitis and implant supported prosthesis was planned.

## INTRODUCTION

Periodontitis is a multifactorial chronic inflammatory disease of the periodontium and has been classified into chronic and aggressive types. Aggressive periodontitis is characterized by rapid destruction and progression of periodontal tissue. It generally occurs in the early decades of age in otherwise healthy patients. (Armitage, 1999; Parameter on aggressive periodontitis, 2000) Familial aggregation is considered an important feature of aggressive periodontitis. (De Boever et al., 2006) This disease can occur in localized or generalized forms. In Generalized aggressive periodontitis (GAP), involvement of at least three permanent teeth other than first molars and incisors is characteristic. (Quirynen et al., 2006; Al-Zahrani, 2008) It usually affects people under 30 years of age, but patients may be older. GAP is frequently associated with *Actinobacillus actinomycetemcomitans* and *Porphyromonas gingivalis* and is believed that such patients may have a deficiency in the host immune system. Patients with GAP often lose most of their teeth due to severe attachment loss of affected teeth. (Al-Zahrani, 2008) Several longitudinal studies aimed at analyzing the influence of a history of aggressive periodontal disease on implant treatment outcome in terms of implant survival rate and marginal bone loss suggest that patients with GAP experienced higher implant failure rates when compared with patients with chronic periodontitis and healthy patients. However, there is still no consensus that clarifies the effect of previous history of GAP on implant

treatment outcome. (Donos et al., 2012; Koldslund et al., 2009; Schou, 2008; Mombelli et al., 1987)

### Clinical case 1

A 25 year old patient with chief complaint of mobility in teeth was examined in the outpatient department of periodontics. Periodontal examination revealed an average attachment loss of 7mm. Mobility and flaring was present in maxillary anterior teeth. Medical history was non-contributory. Radiographic analysis revealed generalized alveolar bone loss with intraosseous defects present. The patient was diagnosed with Generalized Aggressive periodontitis. Subsequently a treatment plan was formulated which included extraction of teeth with hopeless prognosis, flap surgery and regenerative techniques in intrabony defects and implant supported prosthesis. In the first phase following the non-surgical treatment, patient was posted for flap surgery in maxillary and mandibular quadrants. Intraosseous defects in relation to mandibular left premolars were grafted using Demineralized freeze dried bone allograft and Platelet Rich Fibrin. Maxillary and mandibular anterior teeth were extracted at the same time. After four weeks of healing, a Cone Beam Computed Tomography (CBCT) was done using single FOV in maxillary anterior teeth region to assess the volume of alveolar bone available. During the second surgical phase, implants of dimension 3.5mm x 10mm were placed in relation to maxillary canines and central incisors. A temporary prosthesis was given to the patient which was subsequently replaced with final prosthesis after 6 months of implant placement.

\*Corresponding author: Dr. Abis Amir,

Department of Periodontics, Dr Syamala Reddy Dental College and Hospital, Bengaluru.

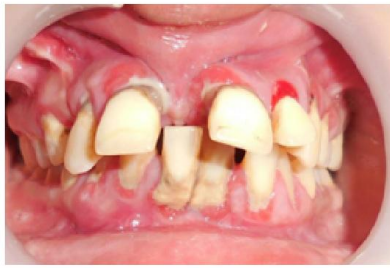

FIG 1. PRE-OPERATIVE SITE

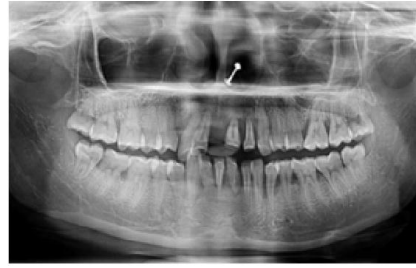


FIG 2. PRE-OPERATIVE OPG

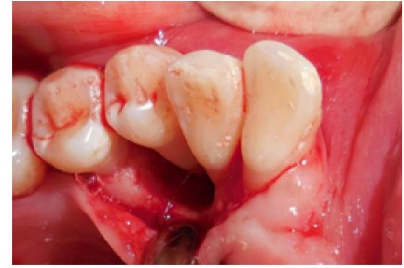

FIG 3. INTRA OSSEOUS DEFECT IN RELATION TO TOOTH 34

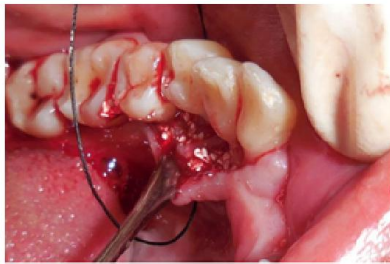


FIG 4. DFDBA AND PRF PLACED IN THE DEFECT

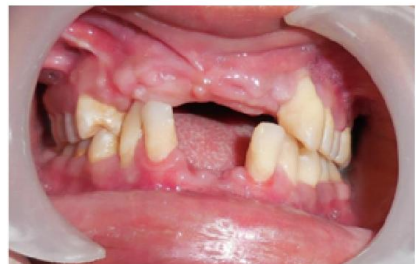

FIG 5. PRE-OPERATIVE SITE BEFORE IMPLANT PLACEMENT

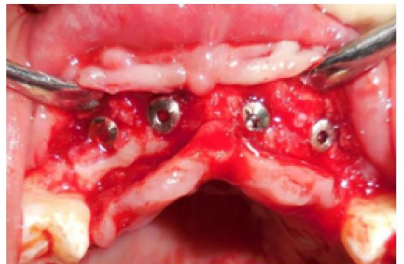


FIG 6. IMPLANTS PLACED IN RELATION TO TEETH 13, 11, 21 AND

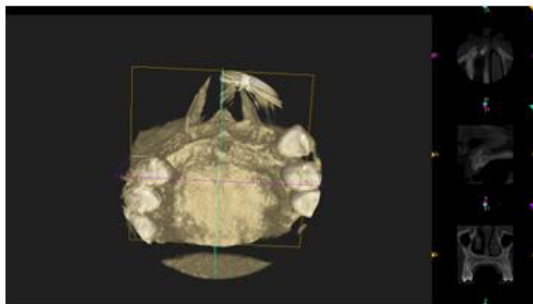


FIG 7. CBCT FOR IMPLANT PLANNING

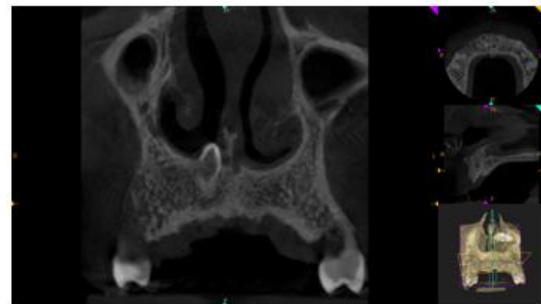


FIG 8. SAGITTAL VIEW ON CBCT

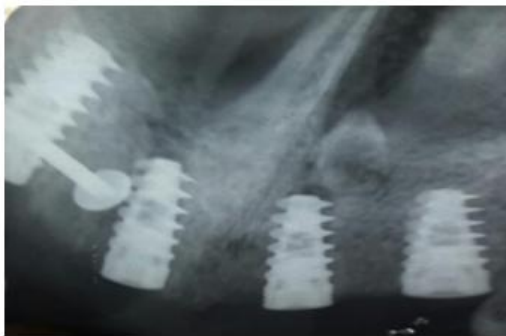

FIG 9. POST-OPERATIVE IOPA RADIOGRAPH

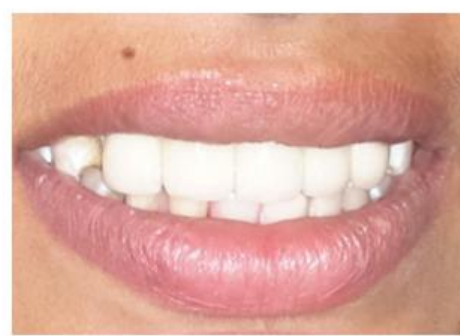
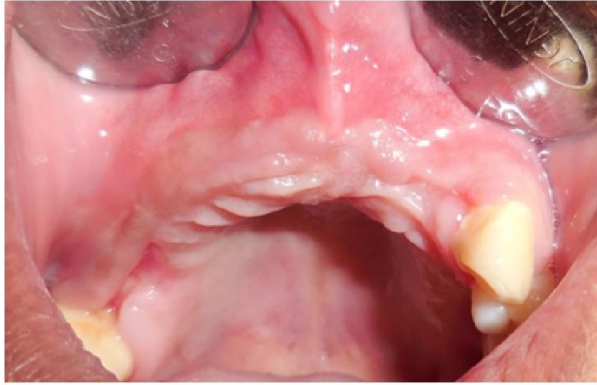
FIG 10. TEMPORARY PROSTHESIS PLACED

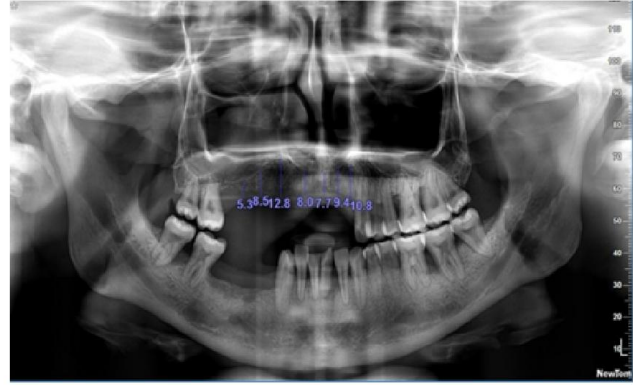## Clinical case 2

A 28 year old male patient presented to the department of periodontics with chief complaint of loose teeth since 3 years. Patient had minimal plaque deposit and periodontal examination revealed average attachment loss of 7mm. medical history was non-contributory. Generalized tooth mobility was present. Radiographic examination revealed an average of 4 mm of vertical height of alveolar bone available in maxillary right quadrant. A periodontal treatment plan was developed for the patient which included non-surgical and surgical periodontal therapy, extraction of teeth with hopeless prognosis, guided bone regeneration and implant supported

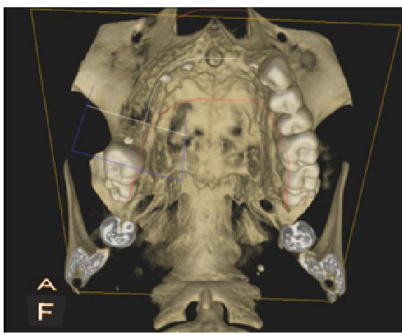
prosthesis. In the first surgical phase, all teeth with hopeless prognosis were extracted and periodontal treatment of remaining teeth were completed. In the second surgical phase guided bone regeneration was attempted using hydroxyapatite putty and tricalcium phosphate bone graft particles. After 6 months from the second phase implant of dimension 3.5mm x 11.5mm were placed in relation to tooth number 14, 12 and 22. Maxillary sinus lift was performed in relation to 16 and implant of dimension 3.5 x 8.5 mm was placed simultaneously. Sinus lift was performed using OSSTEM Crestal approach kit (CAS). A temporary prosthesis was placed and was subsequently replaced with a final prosthesis after 6 months of implant placement.



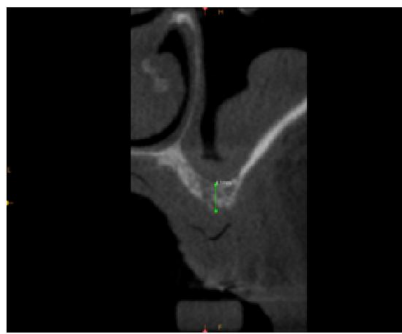
**FIG 11. SITE 6 MONTHS AFTER RIDGE AUGMENTATION**



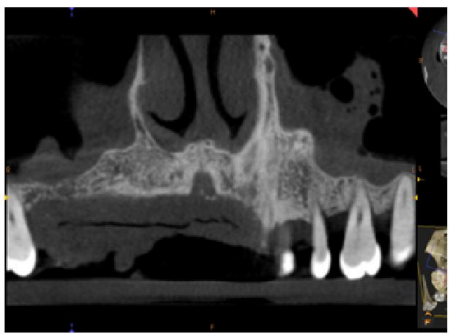
**FIG 12. OPG FOR ASSESSMENT OF ALVEOLAR BONE**



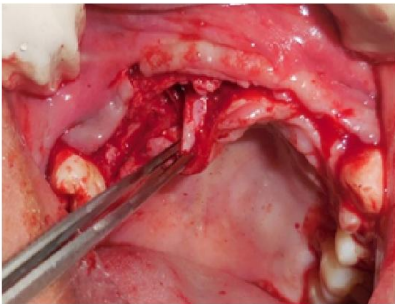
**FIG 13. CBCT FOR ASSESSMENT OF ALVEOLAR BONE**



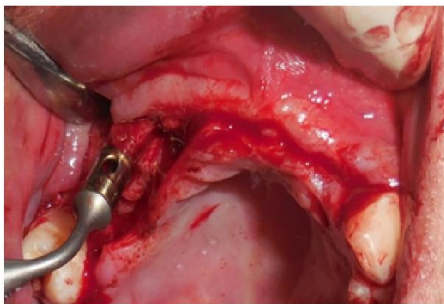
**FIG 14. CBCT SHOWING 4mm OF VERTICAL HEIGHT AVAILABLE IN RELATION TO 16**



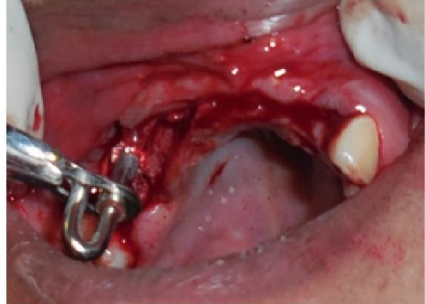**FIG 15. CBCT SAGITTAL VIEW**



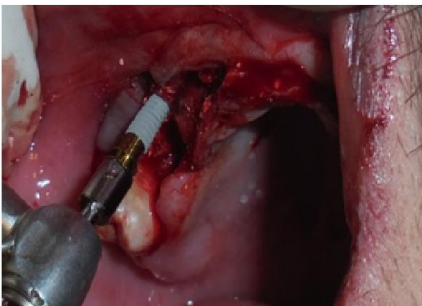**FIG 16. INCISION GIVEN AND CONNECTIVE TISSUE HARVESTED**



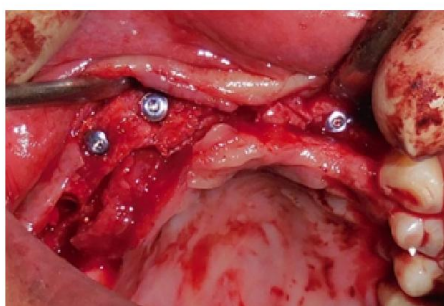
**FIG 17. MAXILLARY SINUS LIFT USING CRESTAL APPROACH**



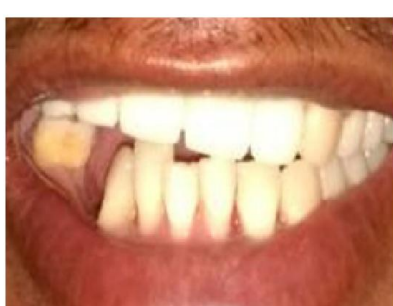**FIG 18. BONE GRAFT PLACED AFTER SINUS LIFT**



**FIG 19. IMPLANT PLACED AFTERSINUS LIFT**



**FIG 20. IMPLANTS PLACED IN RELATION TO TEETH 16, 14, 12 AND 22.**



**FIG 21 TEMPORARY PROSTHESIS PLACED**

## DISCUSSION

There is a controversy about whether implant treatment in patients with previous tooth loss due to GAP is characterized by an increased incidence of peri-implantitis and implant loss. (Wu and Chee, 2007) Implant survival is no longer considered a challenge; however, for the success of implant dentistry, longevity of implant supported prosthesis must be sought. (Heitz-Mayfield, 2008) Many factors were shown to influence the final outcome in implant therapy. Among others, patients with a previous history of periodontal disease and smokers tend to exhibit higher incidences of implant failure and bio-mechanical complications than patients without such conditions. (Heitz-Mayfield, 2008) A study conducted over 18 months only on one patient with GAP reported that inflammation or marginal bone loss was not found in all implants. The survival rate of implants was 100%. (Olson et al., 2000) Another studies reported on similar cases with a positive outcome. However, These studies had short followup period and sample size were small. In long-term studies, marginal bone loss in patients with GAP as compared with implants in periodontally healthy patients or patients with chronic periodontitis showed significantly higher incidence. (Hoffmann et al., 2007; Hong et al., 2010; Huh et al., 2010; Bidra and Shaqman, 2012) These long term studies suggest increased susceptibility to progressive marginal bone loss around implants in patients with GAP. Therefore, marginal bone loss at implants in patients with GAP as compared with implants in periodontally healthy patients or chronic periodontitis patients was not significantly greater in short term studies but was significantly greater in long term studies. (Mengel and Flores-de-Jacoby, 2005; Mengel et al., 2007) The reported short-term implant survival rates in patients with GAP were 97.4%, (Mengel and Flores-de-Jacoby, 2005) reaching up to 100% in three studies (Mengel and Flores-de-Jacoby, 2005; Mengel et al., 2007; Mengel and Flores-de-Jacoby, 2005) with a 3 year follow-up period from the same research group. All patients were nonsmokers and had no systemic diseases in three studies. Mengel & Flores-de-Jacoby found that the 3-year implant survival rate was 100% in the periodontally healthy subjects and chronic periodontitis patients, and 97.4% in the GAP patients. (Mengel and Flores-de-Jacoby, 2005) Numerous studies have reported the influence of smoking on implant success, finding that smoking increases the risk of implant failure.

## Conclusion

Late diagnosis of aggressive periodontitis can lead to edentulism in young patients and thus decrease their quality of life. Implant treatment in patients with generalized aggressive periodontitis is not contraindicated provided that adequate infection control and an individualized maintenance program are assured. However, long term longitudinal studies are required to help in assessing the true predictability of implant survival in such cases.

## REFERENCES

- Al-Zahrani MS. 2008. Implant therapy in aggressive periodontitis patients: A systematic review and clinical implications. *Quintessence Int.*, 39:211-215.
- Armitage GC. 1999. Development of a classification system for periodontal diseases and conditions. *Ann Periodontol.*, 4:1-6.
- Bidra AS, Shaqman M. 2012. Treatment planning and sequence for implant therapy in a young adult with generalized aggressive periodontitis. *J Oral Implantol.*, 38:405-15.
- De Boever AL, De Boever JA. 2006. Early colonization of non-submerged dental implants in patients with a history of advanced aggressive periodontitis. *Clin Oral Implants Res.*, 17:8-17.
- Donos N, Laurell L, Mardas N. 2012. Hierarchical decisions on teeth vs. implants in the periodontitis-susceptible patient: The modern dilemma. *Periodontol.*, 59:89-110.
- Heitz-Mayfield LJ. 2008. Peri-implant diseases: Diagnosis and risk indicators. *J Clin Periodontol.*, 35(Suppl. 8):292-304.
- Hoffmann O, Beaumont C, Zafiroopoulos GG. 2007. Combined periodontal and implant treatment of a case of aggressive periodontitis. *J Oral Implantol.*, 33:288-92.
- Hong JS, Yeo IS, Kim SH, Lee JB, Han JS, Yang JH. 2010. Implants and all-ceramic restorations in a patient treated for aggressive periodontitis: a case report. *J Adv Prosthodont.*, 2:97-101.
- Huh YH, Shin HJ, Kim DG, Park CJ, Cho LR. 2010. Full mouth fixed implant rehabilitation in a patient with generalized aggressive periodontitis. *J Adv Prosthodont.*, 2:154-9.
- Koldslund OC, Scheie AA, Aass AM. 2009. Prevalence of implant loss and the influence of associated factors. *J Periodontol.*, 80:1069-1075.
- Mengel R, Flores-de-Jacoby L. 2005. Implants in patients treated for generalized aggressive and chronic periodontitis: a 3-year prospective longitudinal study. *J Periodontol.*, 76:534-43.
- Mengel R, Flores-de-Jacoby L. 2005. Implants in regenerated bone in patients treated for generalized aggressive periodontitis: a prospective longitudinal study. *Int J Periodontics Restorative Dent.*, 25:331-41.
- Mengel R, Kreuzer G, Lehmann KM, Flores-de-Jacoby L. 2007. A telescopic crown concept for the restoration of partially edentulous patients with aggressive generalized periodontitis: a 3-year prospective longitudinal study. *Int J Periodontics Restorative Dent.*, 27:231-9.
- Mombelli A, van Oosten MA, Schurch E Jr, Land NP. 1987. The microbiota associated with successful or failing osseointegrated titanium implants. *Oral Microbiol Immunol.*, 2:145-151.
- Olson JW, Shernoff AF, Tarlow JL, Colwell JA, Scheetz JP, Bingham SF. 2000. Dental endosseous implant assessments in a type 2 diabetic population: a prospective study. *Int J Oral Maxillofac Implants*, 15 (6): 811-818.
- Parameter on aggressive periodontitis. American Academy of Periodontology. *J Periodontol.*, 2000;71:867-9.
- Quirynen M, Vogels R, Peeters W, van Steenberghe D, Naert I, Haffajee A. 2006. Dynamics of initial subgingival colonization of 'pristine' peri-implant pockets. *Clin Oral Implants Res.*, 17:25-37.
- Schou S. 2008. Implant treatment in periodontitis-susceptible patients: A systematic review. *J Oral Rehabil.*, 35(Suppl. 1):9-22.
- Wu AY, Chee W. 2007. Implant-supported reconstruction in a patient with generalized aggressive periodontitis. *J Periodontol.*, 78:777-82.