



## CASE REPORT

### PROSTHETIC REHABILITATION FOR OCULAR DEFECT

**<sup>1,\*</sup>Dr. Yogesh S. Sonawane, <sup>2</sup>Dr. Amar A. Thakare, <sup>3</sup>Dr. Deepak C. Kelgandre,  
<sup>4</sup>Dr. Pratibha L. Shirsath and <sup>5</sup>Dr. Geetanjali S. Nikam**

<sup>1</sup>Senior Lecturer, Department of Prosthodontics, YCMM & RDF's Dental College and Hospital, Ahmednagar, Maharashtra, India

<sup>2</sup>Senior Lecturer, Department of Prosthodontics, YCMM & RDF's Dental College and Hospital, Ahmednagar, Maharashtra, India

<sup>3</sup>Senior Lecturer, Department of Oral Pathology, YCMM & RDF's Dental College and Hospital, Ahmednagar, Maharashtra, India

<sup>4</sup>Tutor, Department of Prosthodontics, YCMM & RDF's Dental College and Hospital, Ahmednagar, Maharashtra, India

<sup>5</sup>Clinical Practitioner, Government Rural Hospital, Newasa, Ahmednagar, Maharashtra, India

#### ARTICLE INFO

##### Article History:

Received 11<sup>th</sup> October, 2016

Received in revised form

15<sup>th</sup> November, 2016

Accepted 20<sup>th</sup> December, 2016

Published online 31<sup>st</sup> January, 2017

#### ABSTRACT

Loss of the facial structures affects the physical, psychological and social well being of an individual. The maxillofacial prosthesis not only restores the oral or associated facial structures but also improves the patient aesthetic, form and function. Loss of an eye may be due to congenital defect, neoplastic lesions or trauma. Different treatment modalities are available for ocular defects. This article not only describes a simplified prosthetic management of an ocular defect but also include an technique to mimick the shade and color of the prosthesis similar to that of the natural eye.

#### Key words:

Custom Ocular Prosthesis,  
Conformer, Enucleation,  
Evisceration, Exenteration,  
Congenital Defects.

*Copyright*©2017, *Yogesh et al.* This is an open access article distributed under the Creative Commons Attribution License, which permits unrestricted use, distribution, and reproduction in any medium, provided the original work is properly cited.

**Citation:** Dr. Yogesh S. Sonawane, Dr. Amar A. Thakare, Dr. Deepak C. Kelgandre, Dr. Pratibha L. Shirsath and Dr. Geetanjali S. Nikam. 2017. "Prosthetic rehabilitation for ocular defect", *International Journal of Current Research*, 9, (01), 44998-45001.

## INTRODUCTION

An unfortunate absence or loss of an eye may be caused by a congenital defect, irreparable trauma, a painful blind eye. The disfigurement associated with the loss of an eye can cause significant physical and emotional problems. Three types of Surgical procedures can be classified as: Evisceration, which includes removal of the contents of the globe, leaving the sclera intact, Enucleation, most common, where the eyeball is completely removed after serving muscles and the optic nerve. Exenteration, where the entire contents of the orbit including the eyelids and the surrounding tissues are removed [Taylor, 2000]. The art of making artificial eyes has been practiced since ancient times. Egyptian priests made the first ocular prosthesis, called Ectblepharons, as early as the 5th century BC.

In those days, artificial eyes were made of enameled metal or painted clay and attached to cloth and worn outside the socket. The first in-socket artificial eye made in the 15th century was made of gold with colored enamel. In the latter part of the 16th century, the Venetian glass artisans discovered a formula that could be tolerated inside the eye socket. These early glass eyes were crude, uncomfortable to wear and very fragile (Fernandes *et al.*, 2009; Sandeep *et al.*, 2013; Artopoulou *et al.*, 2006). The rehabilitation of an ocular defect patient enhances esthetics, improves facial contours, and helps the patient to overcome psychological trauma. This case report describes a simplified prosthetic management of an ocular defect along with a technique to mimick the shade and color of the prosthesis similar to that of the natural eye.

#### Case report

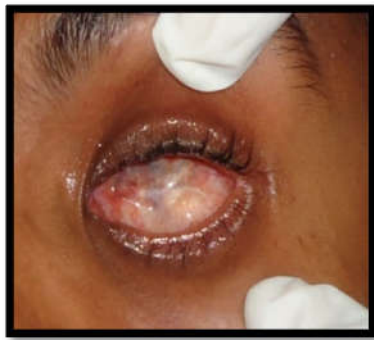A 28 year male patient reported to the department of prosthodontics with chief complaint of missing left eye (Fig 1).

**\*Corresponding author: Dr. Yogesh S. Sonawane,**  
Senior Lecturer, Department of Prosthodontics, YCMM & RDF's  
Dental College And Hospital, Ahmednagar, Maharashtra, India.

Patient gave a history of trauma to left eye 15 years back followed by surgical interventions.



**Fig.1. Pre-operative**



**Fig. 2. Enucleated eye socket**

On examination, intraocular tissue bed was healthy with intact ocular musculature and proper residual movements (Fig 2). Evaluation of the muscular control of the palpebrae and the internal anatomy of the socket in resting position and full excursive movement was performed. Mobility of the posterior wall of the defect was assessed. Condition of conjunctiva, depth of fornices, and presence of cul de sac was noted. Adequate depth between the upper and lower fornices was also present which will help in retention of the ocular prosthesis.

The following treatment options were given to the patient

- Stock eye prosthesis,
- Implant supported prosthesis and
- Custom made acrylic resin ocular prosthesis.

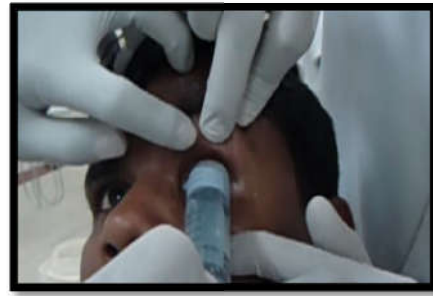Accordingly patient opted for custom made ocular prosthesis. The entire procedure was explained to the patient and informed consent was given by the patient.

## MATERIALS

Armamentarium & material included irreversible hydrocolloid, light body consistency additional polyvinyl siloxane impression material, paraffin wax, acrylic paints, fibers of heat cure polymerizing resin.

## METHODS

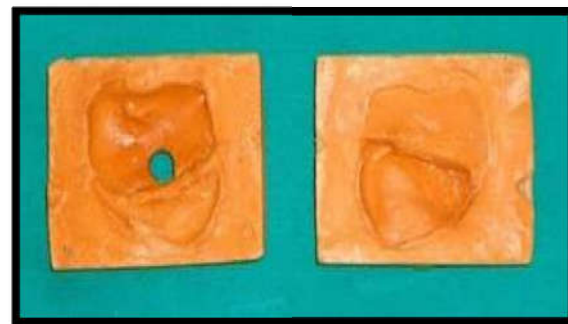
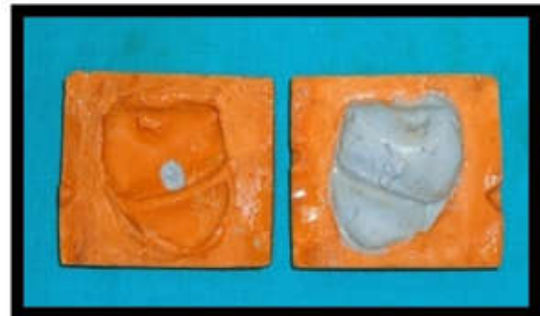The patient's eye socket was coated with a thin layer of Vaseline and an impression was made using irreversible hydrocolloid impression material (alginate) (Fig.3 &4).



**Fig.3. Impression making for eye socket**



**Fig. 4. Recorded impression of ocular defect tissue bed**



**Fig.4 & 5. Split cast for primary impression**

Impression was made by injecting the material first into the depth below the upper eye lid and then into the lower. This was done so as to record the proper extensions of the defect. Then patient was asked to close his eye so the excess material could flow out. Patient was instructed to move his eye to the right, left, up & down and finally in a circular motion to obtain the functional impression of the defect. The impression was then retrieved when it had completely set. This impression was then invested into the Type III dental stone to obtain a primary split cast (Fig.5).

Paraffin Wax was poured in mould to obtain the sclera wax pattern (Fig. 6). This wax pattern was placed in the defect and was added or trimmed until satisfactory contours of the eyelids

were achieved in open and closed positions. Final sclera wax pattern was evaluated for fit, contour, esthetics and comfort of the patient (Fig.7).

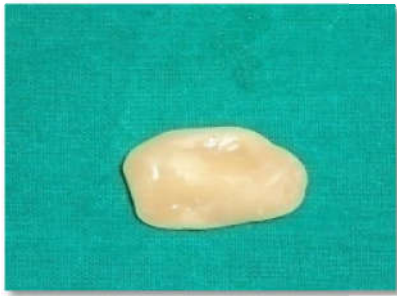

Fig 6. Sclera wax



Fig. 7. Sclera wax pattern trial



Fig. 8. Iris Positioning In Wax Pattern



Fig.9. iris placement

During try-in the iris was placed keeping in mind the symmetry with the iris of the adjacent unaffected right natural eye of the patient. To achieve this exact location, Spectacle attached with transparent graph grid was used for positioning and orientation of iris plane and pupil point (fig.8). On this graph grid, position of the right side natural iris was marked. During this procedure patient was instructed to look ahead to a distant object. With help of graph grid the position and distance of the natural right side iris was transferred to patient forehead. The distance was measured from the midline to the centre of the pupil of the natural eye and the same distance to the left side was marked and engraved into the wax pattern. The pattern was taken out and keeping this position in mind, the iris was placed and adjusted according to the horizontal and vertical axis (Fig.9). Patient's eye movements were checked

for symmetry and function. The wax try-in moved and synchronized in harmony with the patient's natural eye movements. This gave a realistic feeling and confidence to the patient. Once iris positioning was finalized, Relining of wax pattern was done by using light body polyvinyl siloxane elastomeric impression material (Fig.10). Acrylic stump or handle (Fig.11) was made which was attached to iris along with wax pattern (Kirti Somkuwar *et al.*, 2009).

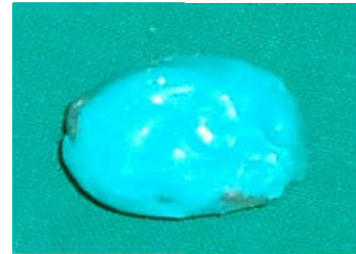

Fig.10. Relining of wax pattern

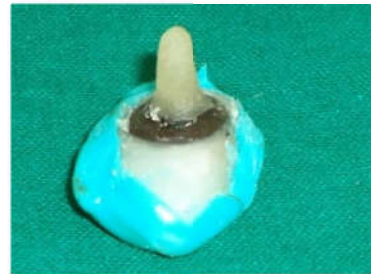

Fig.11. Acrylic stump

**Investing, Dewaxing, and Packing**

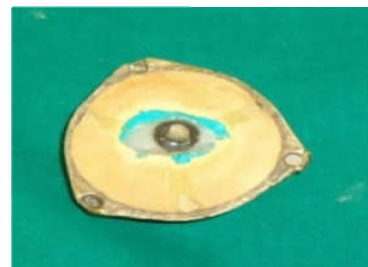

Fig.12. Investing and dewaxing

After the trial of wax pattern the secondary cast was obtained and invested in flask by using dental gypsum in a two piece brass flask (Fig.12). The second pour was poured in such a way that the handle attached to the iris was fix into the plaster of the counter flasking. The flask was then placed in a dewaxing bath for 20 min. Acrylic stump or handle attached to iris will prevent displacement of iris during dewaxing procedure (Kirti Somkuwar *et al.*, 2009). Tooth colored heat

cured polymethylmethacrylate resin was used for packing to simulate the shade similar to that of normal eye sclera (Mc Arthur, 1977).

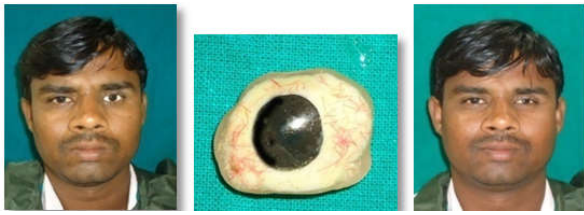

Fig. 13. Acrylic Painting Of Sclera

Rayon thread fibrils were used to simulate vasculature, by monomer polymer syrup method (Thomas D. Taylor; p233-76) (Fig 13). The characterization is done to obtain the patient's natural appearance and cosmetics. Packing was kept for bench curing to enable complete polymerisation and prevention of any excess unreacted monomer. This enables the minimization of porosities and gives a good finish to the prosthesis. We used long curing cycle of 4-6 hours so as to prevent the presence of any residual monomer in the prosthesis which is very essential to prevent irritation or sensitivity and thereby rejection of the prosthesis by the patient. The eye socket is extremely sensitive and the residual conjunctiva and related structures react to any surface roughness and irregularities.

#### Prosthesis placement and follow-up

The final outcome of the prosthesis was assured by pleasant look on patient face (Fig.14). Instructions were given to the patient regarding easy insertion, removal, Cleaning and storage in water or anti-bacterial solution. Follow-up was done on day 1, 2 and 7 after the prosthetic insertion followed by 6 months for prosthesis evaluation and adjustment.



Pre-operative



Post-operative

## DISCUSSION

A properly planned ocular prosthesis maintains its orientation when patient performs various movements. Prosthetic rehabilitation may be improved by implant retained prosthesis but economically it may not be possible for each individual. Although use of stock ocular prosthesis of appropriate size and color cannot be neglected but a custom made ocular prosthesis provides better results functionally as well as aesthetically (Doshi, 2005).

#### Conclusion

The use of custom-made ocular prosthesis has been a boon to the patients who cannot afford for the implant replacements. The esthetic and functional outcome of the prosthesis is better than the stock ocular prosthesis (Cain, 1982). Although the patient is unable to see with this prosthesis but it restore self-esteem of the patient and build the confidence to face the world. The procedure used here is cheaper, affordable and can be carried out in a small clinical set-up. This method has provided good results from patient esthetics, acceptance, and satisfaction points of view.

## REFERENCES

- Artopoulou, I.I., Montgomery, P.C., Wesley, P.J., Lemon, J.C. 2006. Digital imaging in the fabrication of ocular prostheses. *Journal of Prosthetic Dentistry*. 95: 327-330.
- Cain, J.R. 1982. Custom Ocular Prosthetic. *The Journal of Prosthetic Dentistry*, 48(6):690-694.
- Textbook of Clinical Maxillofacial Prosthetics; Thomas D. Taylor; p233-76.
- Doshi, P.J., Aruna, B. 2005. Prosthetic management of patient with ocular defect. *The Journal of Indian Prosthodontic Society*, 5(1): 37-38.
- Fernandes, A.U., Goiato, M.C., Batista, M.A., Santos, D.M. 2009. Color alteration of the paint used for iris painting in ocular prostheses. *Braz Oral Res.*, 23: 386-392.
- Kirti Somkuwar, Robin Mathai, \*Panambily Jose. Ocular prosthesis: Patient rehabilitation - A Case Reprot. *People's Journal of Scientific Research*. vol.2(2), July 2009:21-26.
- Mc Arthur D.A. 1977. Aids for positioning prosthetic eyes in orbital prosthesis. *Journal of Prosthetic Dentistry*.37:192-3
- Sandeep, C., Gopinadh, A., Kavaya, R., Phani, P.B., Sampath, K., Krishna, C.A. 2013. A time saving method to fabricate a custom ocular prosthesis. *Journal of Orofacial Research*. 3: 42-45.
- Taylor, T.D. 2000. Carol stream, Illinois: Quintessence publishing co, Inc; Clinical maxillofacial prosthetics; pp. 233-76)

\*\*\*\*\*