



CASE STUDY

BOWEL OBSTRUCTION FOLLOWING LAP APPENDECTOMY AND OPEN APPENDECTOMY

*Dr. Osama Abdullah Abdul Raheem, Dr. Abd-EL-Aal A- Saleem and Dr. Hassan Ahmed Abdallah

Lecturer of General Surgery, Faculty of Medicine, Aswan University, Egypt

ARTICLE INFO

Article History:

Received 10th December, 2016
Received in revised form
05th January, 2017
Accepted 15th February, 2017
Published online 31st March, 2017

Key words:

Open appendectomy (OA),
Laparoscopic appendectomy (LA),
Bowel obstruction (BO).

ABSTRACT

Background: Acute appendicitis is a common indication for abdominal surgery with a life-time incidence between 7 and 9% and appendectomy is one of the most common surgical procedures. Open appendectomy (OA) performed through the right lower quadrant incision was first described in 1894. It has become the standard treatment of choice for acute appendicitis, due to its efficacy and safety. Laparoscopic appendectomy (LA), first performed by Semm in 1983, and gradually acceptance.

Objective: The aim of the present study was to compare the frequency of readmissions due to bowel obstruction (BO) after open versus laparoscopic surgery performed for suspected acute appendicitis.

Copyright©2017, Dr. Osama Abdullah Abdul Raheem et al. This is an open access article distributed under the Creative Commons Attribution License, which permits unrestricted use, distribution, and reproduction in any medium, provided the original work is properly cited.

Citation: Dr. Osama Abdullah Abdul Raheem, Dr. Abd-EL-Aal A- Saleem and Dr. Hassan Ahmed Abdallah, 2017. "Bowel obstruction following lap appendectomy and open appendectomy", *International Journal of Current Research*, 9, (03), 47566-47568.

INTRODUCTION

Successful appendectomy was first described by McBurney in 1894. The open surgical approach remained the gold standard for nearly a century. The lifetime risk of developing appendicitis is between 7 and 9% with evidence of increasing incidence (Addiss *et al.*, 1990; Buckius *et al.*, 2012). With the advance of minimal invasive surgery, new approaches for the existing operations have been proposed. Semm first described the laparoscopic approach for acute appendicitis in 1983 (Semm, 1983). Now laparoscopic appendectomy (LA) has become common and an acceptable approach in the management of acute appendicitis (Litynski, 1998). LA association with decreased postoperative pain, more rapid return to daily activities, and improved cosmetic results. However, the literature has shown the association of laparoscopy with specific adverse events such as increased intra-abdominal abscess and hospital costs (Sauerland *et al.*, 2004). Despite OA being associated with low morbidity and mortality rates the popular minimally invasive approach showed more advantages such as less wound infection, less pain, and faster recovery in the cost of more operating time and hospital cost (Shaikh *et al.*, 2009; Heikkinen *et al.*, 1998). LA can have extra benefits for female patients as decreasing adhesions and fertility problems and better cosmetic (Tzovaras *et al.*, 2007). Adhesion formation is now one of the most common causes of intestinal obstruction. Late complications

due to intra-abdominal adhesions include chronic abdominal pain, small bowel obstruction (SBO), and female infertility. These chronic conditions can result in a major impairment for the patient, a challenge to treat, and represent a major cost for society (Cuschieri, 1997; Tingstedt *et al.*, 2007). Reduced adhesion formation is a substantive long term advantage of laparoscopic appendectomy. The adhesion rate after open appendectomy more than 80% compared to 10% after laparoscopic appendectomy, when patients were laparoscoped three months after surgery (Cuschieri, 1997). It has been shown that the tissue trauma of the incision increases the total inflammatory response, thereby inhibiting fibrinolysis and promoting fibroblast migration and collagen formation.

PATIENTS AND METHODS

This was performed in Aswan university hospital, on 100 patient from April 2015 to April 2016 who underwent laparoscopic and open appendectomy. The merits and drawbacks of LA and OA were explained to all of the patients with diagnosis of acute appendicitis. The diagnosis of acute appendicitis is mainly clinical. Several methods have been suggested to diminish the diagnostic error like U/S and CT abdomen if diagnosis is not clear. The symptoms of appendicitis can initially be difficult to differentiate from gastroenteritis. Early symptoms may include vague bloating, indigestion and mild pain which generally is perceived as being in the area of the umbilicus. As the infection worsens, the pain becomes more prominent in the right lower quadrant. There is usually nausea, vomiting and loss of appetite. Many

*Corresponding author: Dr. Osama Abdullah Abdul Raheem,
Lecturer of General Surgery, Faculty of Medicine, Aswan University, Egypt.

other conditions can mimic appendicitis such as gastroenteritis, kidney stones, urinary infections, ulcerative colitis and Crohn's disease. In women, problems such as ovarian cysts and pelvic infections can mimic appendicitis. The most accurate non-invasive method of diagnosis is ultrasonography but this is not totally reliable. The history and physical examination will generally lead to the correct diagnosis. Our exclusion criteria for this study were being patients, showing signs of generalized peritonitis, having a palpable mass in RLQ suggesting appendiceal abscess, or being pregnant or appendectomy was performed as a part in a more extensive surgical procedure colorectal resection or when the operation was extended because of an advanced appendicitis (eg, ileocecal resection). When the appendectomy was accompanied with another concurrent intra-abdominal surgical procedure (eg, oophorectomy, Meckel diverticulum). And patients with carcinoma of the appendix. The patient classified blindly into two group, group A for LA and group B for OA Patients who gave their informed consent were randomized to either LA or OA groups. The randomization technique was by having patient open a concealed envelope from a randomized order of envelopes by a blinded technician.

All of the patients received prophylactic ceftriaxone (1 gram, every 12 hours) and metronidazole (500 mg, every 8 hours). All of the surgeries were performed by the same surgeon. The OA surgeries were performed through a McBurney's muscle-splitting incision. For the LA patients, the classic three port technique was performed through two 10 mm (umbilical and iliac fossa) and one 5 mm (suprapubic) ports. In lap app ligation of base of appendix with endoloop while in open app ligation of base with vicryle 2 /0 (Fig -1,2). All of the removed appendices were sent for pathologic study.

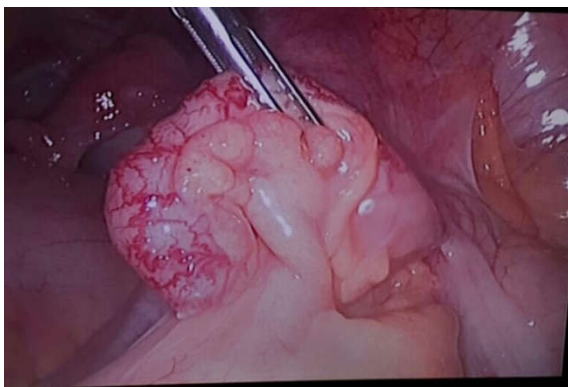


Fig.1. Inflamed appendix

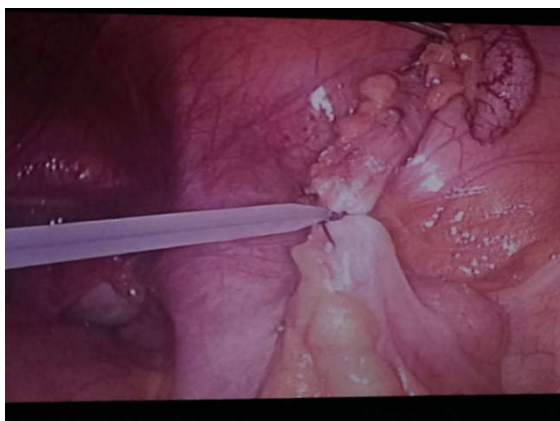

Fig.2. Ligation of base with endoloop

After the operation all of the patients were NPO and received antibiotics for 48 hours. The routine analgesic used for patients was morphine (5 mg intramuscular, every 8 hours). Soft diet was started after 24 hours and patients were discharged after normal diet was tolerated. Post operation follow up visits were in weeks 1, 2 and 4. Patients were asked to contact the therapy team in case of any abdominal problem.

RESULTS

The total number of 100 patients, in two groups of open and laparoscopic appendectomy, was followed up for six month in this study. The LA group was 50 patient and OA group also 50. The mean age was 18.3 for group A and 19 for group B (Fig.3). The group A was 30 male and 20 female and group B was 35 male and 15 female (Table 1).

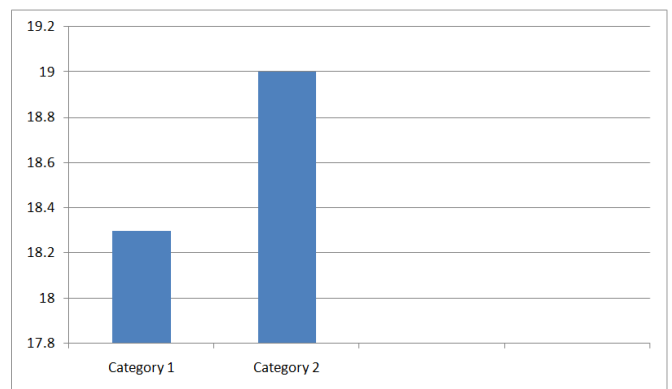


Fig.3. Mean age in two groups

Table 1. Male and female ratio in both groups

	Male	%	Female	%
Group A	30 patient	60%	20 patient	40%
Group B	35 patient	70%	15patient	30%

- No intra operative complication was encountered in operations. There was no conversion to open surgery in LA operations.
- No complication for group A during the period of follow up except chronic pain at the port site and improved with time and analgesia.
- Group B about 10 patient readmitted with abdominal pain and distension, x rays abdomen done for them and showed intestinal obstruction and diagnosed as adhesive intestinal obstruction 8 of them treated conservative fluid support, NGT and enema and discharged after improvement, the other two patient not improved with medication and treated by open surgery and we found adhesion at the site of wound adhesiolysis done for them and improved after one week and discharged.

Post operative follow up for development of intestinal obstruction for two groups

	Group A	Group B	
		10 PATIENT	
Symptom of intestinal obstruction abdominal pain, distention, vomiting and absolute constipation	No	8 Patient treated conservative	2 patient treated with surgical intervention

Post operative follow up for development of intestinal obstruction for two groups

DISCUSSION

Postoperative adhesions are quite common, especially not only after surgery of the lower part of the abdomen such as gynecological and colorectal surgery but also after appendectomy. Late complications due to intra-abdominal adhesions include chronic abdominal pain, bowel obstruction (BO), and female infertility. These chronic conditions can result in a major impairment for the patient, a challenge to treat, and represent a major cost for society. In Sweden, costs related to admissions due to abdominal adhesions are estimated to about €40 million to €60 million per year (Tingstedt *et al.*, 2007). Abdominal adhesions are the most common cause of BO requiring surgical intervention. The lifetime risk of postoperative bowel obstruction after abdominal surgery with a frequency of up to 25% after some procedures has been reported. The incidence of bowel obstruction after appendectomy has historically been reported to be between 0.7% and 10.7% (Tsao *et al.*, 2007; Zbar *et al.*, 1993). Type and grade of surgical trauma seem to play an important role in adhesion formation. There are documented advantages of laparoscopic procedures in general, as compared with open surgery, in reducing postoperative adhesion formation by minimizing the trauma to the peritoneal surface (Gutt *et al.*, 2004). The laparoscopic surgical techniques lead to fewer intra-abdominal adhesions by reducing tissue trauma, which in turn reduces circulating inflammatory mediators (Garrard *et al.*, 1999). Open surgery seems to increase the risk of BO at least 4-fold compared with laparoscopic surgery for most of the abdominal surgical procedures (Angenete *et al.*, 2012). The laparoscopic approach appears to decrease the risk of adhesion formation by 45% as well as decreasing the need for adhesion-related reintervention to 0.8% after appendectomy (Ouaïssi *et al.*, 2012). A recent study by Isaksson *et al* found a significant difference in the rate of postoperative BO: 1.0% in the open group, and 0.4% in the laparoscopic group (Isaksson *et al.*, 2014). In our study we confirm low intestinal complication following lap app so become trend in our hospital to do lap app in cases of acute appendicitis.

Conclusion

Laparoscopic appendectomy is equally safe, and can provide less postoperative morbidity in experienced hands, as open appendectomy. Most cases of acute appendicitis can be treated laparoscopically. Laparoscopic appendectomy is a useful method for reducing hospital stay, complications and return to normal activity.

REFERENCES

- Addiss, D. G., N. Shaffer, B. S. Fowler, and R. V. Tauxe, 1990. "The epidemiology of appendicitis and appendectomy in the United States," *American Journal of Epidemiology*, vol. 132, no. 5, pp. 910–925, View at Google Scholar •
- Angenete E, Jacobsson A, Gellerstedt M, *et al.* 2012. Effect of laparoscopy on the risk of small-bowel obstruction: a population-based register study. *Arch Surg.*, 147:359–365.
- Buckius, M. T., B. McGrath, J. Monk, R. Grim, T. Bell, and V. Ahuja, 2012. "Changing epidemiology of acute appendicitis in the United States: study period 1993–2008," *Journal of Surgical Research*, vol. 175, no. 2, pp. 185–190, View at Publisher •
- Cuschieri. A. 1997. Appendectomy-laparoscopic or open? *Surg Endosc.*, 11: 319-320.
- Garrard, C.L., R.H. Clements, L. Nanney, J.M. Daviddson, W.O. Richards. 1999. *Surg Endosc.*, 13: 10-13. Adhesion formation is reduced after laparoscopic surgery.
- Gutt CN, Oniu T, Schemmer P, *et al.* 2004. Fewer adhesions induced by laparoscopic surgery? *Surg Endosc.*, 18:898–906.
- Heikkinen TJ, Haukipuro K, Hulkko A. 1998. Cost-effective appendectomy. Open or laparoscopic? A prospective randomized study. *Surg Endosc.*, 12(10):1204-
- Isaksson K, Montgomery A, Moberg AC, *et al.* 2014. Long-term follow-up for adhesive small bowel obstruction after open versus laparoscopic surgery for suspected appendicitis. *Ann Surg.*, 259:1173–1177.
- Litynski, G. S. 1998. "Kurt Semm and the fight against skepticism: endoscopic hemostasis, laparoscopic appendectomy, and Semm's impact on the "laparoscopic revolution" *Journal of the Society of Laparoendoscopic Surgeons*, vol. 2, no. 3, pp. 309–313.
- McBurney, C. 1894. "The incision made in the abdominal wall in cases of appendicitis, with a description of a new method of operating," *Annals of Surgery*, vol. 20, no. 1, pp. 38–43.
- Ouaïssi M, Gaujoux S, Veyrie N, *et al.* 2012. Post-operative adhesions after digestive surgery: their incidence and prevention: review of the literature. *J Visc Surg.*, 149:104–114.
- Sauerland, S., R. Lefering, and E. A. Neugebauer, 2004. "Laparoscopic versus open surgery for suspected appendicitis," *Cochrane Database of Systematic Reviews*, no. 4, Article ID CD001546.
- Semm, K. 1983. "Endoscopic appendectomy," *Endoscopy*, vol. 15, no. 2, pp. 59–64, View at Publisher •
- Shaikh AR, Sangrasi AK, Shaikh GA. 2009. Clinical outcomes of laparoscopic versus open appendectomy. *JSLs*, 13(4):574-80.
- Tingstedt B, Isaksson J, Andersson R. 2007. Long-term follow-up and cost analysis following surgery for small bowel obstruction caused by intra-abdominal adhesions. *Br J Surg.*, 94:743–748.
- Tingstedt B, Isaksson J, Andersson R. 2007. Long-term follow-up and cost analysis following surgery for small bowel obstruction caused by intra-abdominal adhesions. *Br J Surg.*, 94:743–748.
- Tsao KJ, St Peter SD, Valusek PA, *et al.* 2007. Adhesive small bowel obstruction after appendectomy in children: comparison between the laparoscopic and open approach. *J Pediatr Surg.*, 42:939–942; discussion 942.
- Tzovaras G, Liakou P, Baloyiannis I, Spyridakis M, Mantzos F, Tepetes K, Athanassiou E, Hatzitheofilou C. 2007. Laparoscopic appendectomy: differences between male and female patients with suspected acute appendicitis. *World J Surg.*, 31(2):409-13.
- Zbar RI, Crede WB, McKhann CF, *et al.* 1993. The postoperative incidence of small bowel obstruction following standard, open appendectomy and cholecystectomy: a six-year retrospective cohort study at Yale-New Haven Hospital. *Conn Med.*, 57:123–127.