



## CASE STUDY

### STAGED NEUROSURGICAL APPROACH TO COMPLEX SKULL BASE LESION

**Dr. Ali Al Mashani, \*Dr. Neeraj Salhotra, Dr. Azmat Ali, Dr. Munther Al Zabin, Dr. Salim Al Abri,  
Dr. Mohammad Hashim and Dr. Ahmed Al Risi**

Department of Neurosurgery, Khoula Hospital Muscat, Oman

#### ARTICLE INFO

##### Article History:

Received 23<sup>rd</sup> January, 2017  
Received in revised form  
07<sup>th</sup> February, 2017  
Accepted 16<sup>th</sup> March, 2017  
Published online 20<sup>th</sup> April, 2017

##### Key words:

Skull base tumors, Staged approach.

#### ABSTRACT

Skull base tumors are a challenge to neurosurgeons. Starting from meningiomas, pituitary tumors to clival chordoma or acoustic schwannoma all demand a complex case planning and strategy (Koutourousiou *et al.*, 2013). We present a skull base meningioma in a adult male treated in two stage surgery with complete tumor excision with no gross neurological deficit. Single stage exhausting prolonged surgery weighs inferior to staged surgery with good outcome with minimal complications.

Copyright©2017, Dr. Ali Al Mashani *et al.* This is an open access article distributed under the Creative Commons Attribution License, which permits unrestricted use, distribution, and reproduction in any medium, provided the original work is properly cited.

Citation: Dr. Ali Al Mashani, Dr. Neeraj Salhotra, Dr. Azmat Ali *et al.* 2017. "Staged neurosurgical approach to complex skull base lesion", *International Journal of Current Research*, 9, (04), 48773-48775.

## INTRODUCTION

Skull base tumors involve all three anterior, middle and posterior cranial fossa. Meningiomas are the most common lesion can be olfactory groove, planum sphenoidal, clinoidal or petroclival. Pituitary tumors and craniopharyngiomas are a well known entity. (Malekpour and Cohen-Gadol, 2014) Chordoma, chondroma, chondrosarcomas and glomus jugulare are the other entities. Treatment is a challenge specially in invasive lesions more so in middle and posterior cranial fossa. Our case was an adult male with middle and posterior cranial fossa involvement and was treated in a staged manner with minimal deficit.

## MATERIALS AND METHODS

Our patient a 40 yr old adult male got admitted in our hospital with history of headache and episodic facial spasms for last 2 months. On examination no gross neuro deficit was seen. Patient underwent MRI brain which revealed contrast enhancing lesion in the petroclival region with compression of brainstem and surrounding structures as in Fig 1. Detailed discussion was done with patient regarding nature of disease, approach to surgical excision and likely risks and benefits. Single staged exhaustive presigmoid and retrosigmoid surgery to staged 1st stage presigmoid approach followed by 2 nd stage retrosigmoid approach was discussed. Patient gave consent for

2 nd option and we undertook the surgery. Patient underwent presigmoid subtemporal approach for the middle cranial fossa part of the tumour. Tumour was highly vascular, firm and piece meal excision could be obtained using CUSA. All neural elements were safeguarded. After a 6 hrs procedure patient was extubated without any deficit and shifted to ICU. Post op CT was satisfactory and patient was discharged after 4 th day to follow up after 2 months for the 2<sup>nd</sup> stage procedure. After 2months patient underwent a MRI as in Fig 2 which showed the remaining clival part of tumour. Patient underwent now retrosigmoid approach extending the earlier incision inferiorly in retromastoid region in a park bench position. Neurophysiological monitoring by SSEP and facial nerve and other lower cranial nerve monitoring was instituted. After a routine retromastoid craniotomy and retracting the cerebellum via subarachnoid approach to the lesion and piece meal excision of the tumor done microscopically from the cerebellopontine region and in front of brain stem using the CUSA.

## RESULTS

After a 6 hrs surgical procedure complete excision of the tumour was done. Patient was extubated and mild facial nerve paresis was noticed which improved in following days. No other gross deficit was seen. Neurophysiological monitoring did not reveal any damage to neural structures. After 1 day stay in ICU patient was shifted to ward and after 4 days stay in hospital was discharged home. Post operative CT scan is as per Fig 3.

\*Corresponding author: Dr. Neeraj Salhotra,  
Department of Neurosurgery, Khoula Hospital Muscat, Oman.

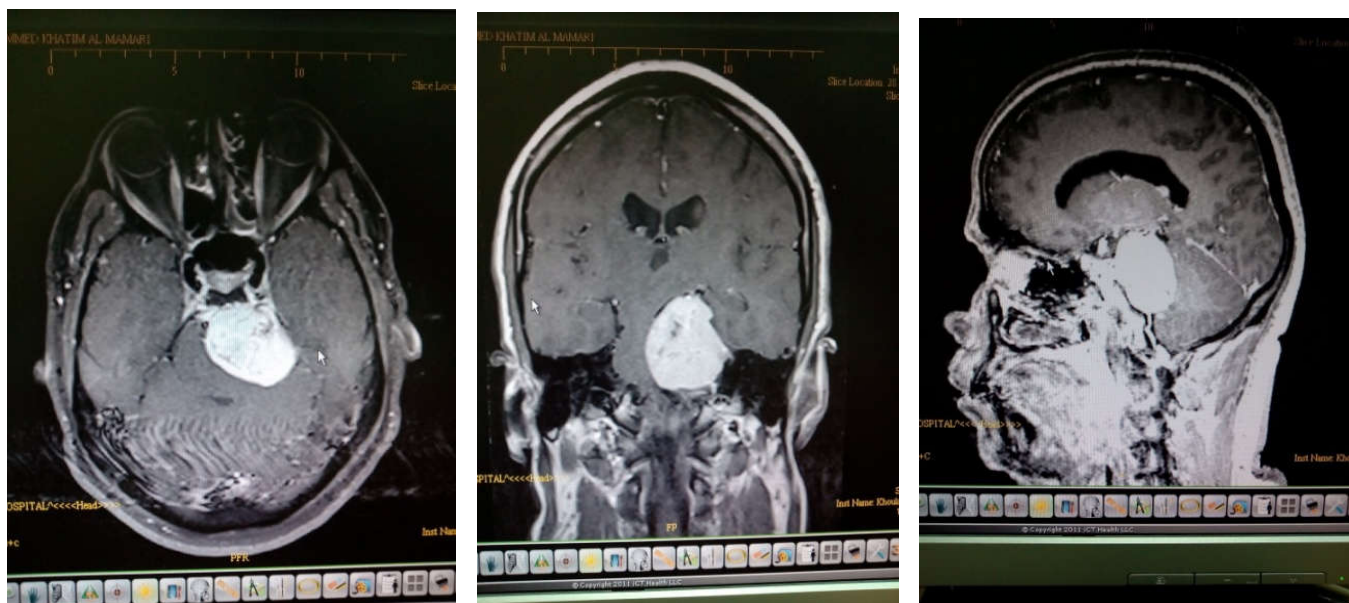

Fig.1. Pre operative MRI

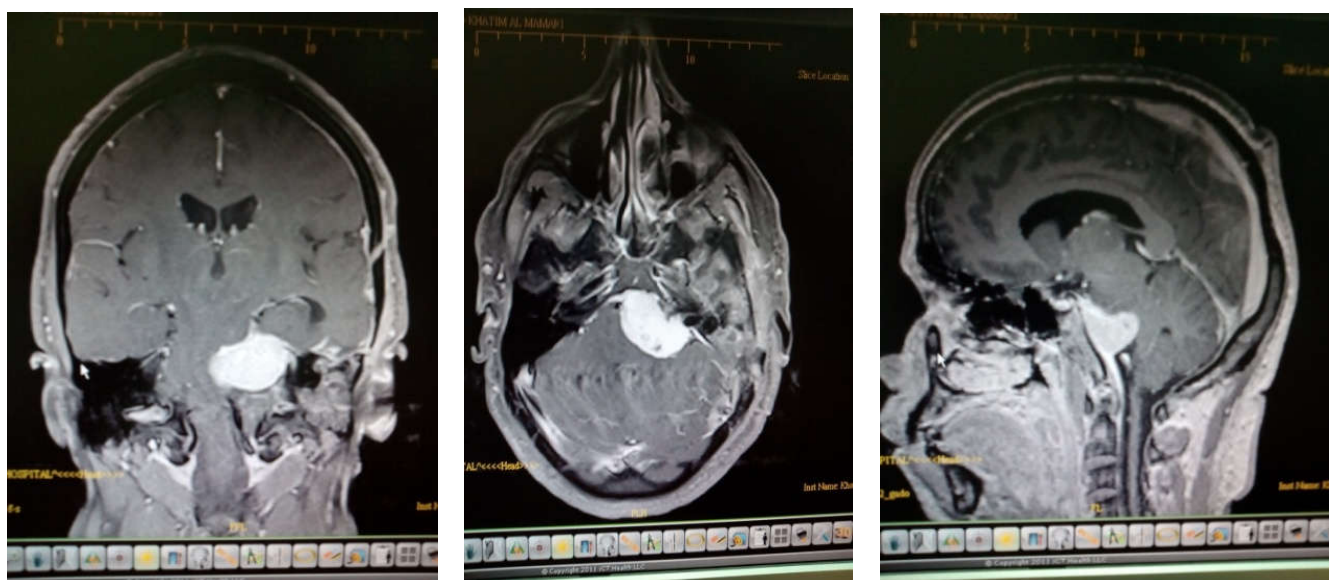


Fig.2. MRI after 1 st stage resection of supratentorial part

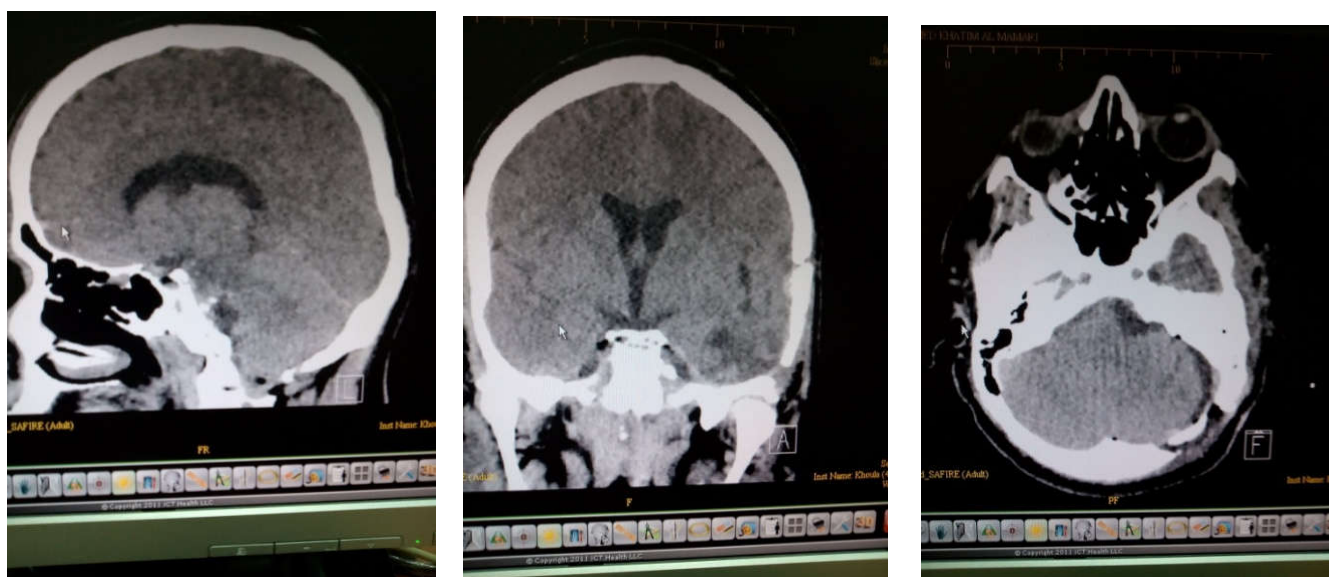


Fig.3. CT brain after 2 nd stage surgery

Histopathology revealed it to be WHO grade I meningioma and patient is on follow up in OPD.

## DISCUSSION

Malekpour *et al* described in 2014 the Harvey Cushing's approach to complex skull base tumors in staged way for a better outcome (Malekpour and Cohen-Gadol, 2014). Yang K in 2017 described how to plan the surgery of petroclival meningiomas by preoperative simulation of abducens nerve course (Yang *et al.*, 2017). Tajudeen BA in 2016 described ectopic pituitary adenomas presenting as erosive clival regions making hormonal assessment as prerequisite in preoperative planning which was done in our case (Tajudeen *et al.*, 2017). Koutourousiou *et al.* described the endonasal endoscopic approach to complex skull base tumors specially massive invasive pituitary adenomas as a part of staged strategy (Koutourousiou *et al.*, 2013). Masamitsu ABE in 1998 stressed the extensive preoperative planning on plastic skull models prior to venturing into complex skull base tumour surgeries (Masamitsu *et al.*, 1998). Michell L in 2010 emphasized the importance of petroclival surgery and cranial nerve morbidities as a biggest challenge to manage (Era Michael L. DiLuna *et al.*, 2010).

## Conclusion

Staged surgical approach to complex skull base lesion versus single stage exhaustive prolonged surgery is more patient and surgeon friendly giving minimal neurodeficits better surgical outcome than to leave patient crippled with multiple neurodeficits. Our case report supports the idea of a staged approach to such lesions.

## REFERENCES

- Era Michael L. DiLuna, M.D.<sup>1</sup> and Ketan R. Bulsara, M.D 2010. Surgery for Petroclival Meningiomas: A Comprehensive Review of Outcomes in the Skull Base Surgery, *Skull Base. Sep*; 20(5): 337–342.
- Koutourousiou M1, Gardner PA, Fernandez-Miranda JC, Paluzzi A, Wang EW, Snyderman CH. 2013. Endoscopic endonasal surgery for giant pituitary adenomas: advantages and limitations. *J Neurosurg.*, Mar;118(3):621-31. doi: 10.3171/2012.11.JNS121190. Epub 2013 Jan 4.
- Malekpour M1 and Cohen-Gadol, 2014. The pursuit of a cholesteatoma by harvey cushing: staged approach to a complex skull base tumor. *J Neurol Surg B Skull Base.* a339-45. doi: 10.1055/s-0034-1372471. Epub, May.
- Masamitsu ABE<sup>1</sup>, Kazuo TABUCHI<sup>1</sup>, Masaaki GOTO<sup>2</sup>, Akira UCHINO<sup>3</sup>, 1998. Model-based Surgical Planning and Simulation of Cranial Base Surgery, *Neurol Med Chir (Tokyo)* 38, 746-751.
- Tajudeen BA<sup>1</sup>, Kuan EC<sup>2</sup>, Adappa ND<sup>3</sup>, Han JK<sup>4</sup>, Chandra RK<sup>5</sup>, Palmer JN<sup>3</sup>, Kennedy DW<sup>3</sup>, Wang MB<sup>2</sup>, Suh JD<sup>2</sup>, 2017. Ectopic Pituitary Adenomas Presenting as Sphenoid or Clival Lesions: Case Series and Management Recommendations. *Neurol Surg B Skull Base*, Apr;78(2): 120-124. doi: 10.1055/s-0036-1592081. Epub 2016 Sep
- Yang K, Ikawa F, Onishi S, Kolakshyapati M, Takeda M, Yamaguchi S, Ishifuro M, Akiyama Y, Morishige M, Kurisu K. 2017. Preoperative simulation of the running course of the abducens nerve in a large petroclivalmeningioma: a case report and literature review. *Neurosurg Rev.*, Apr;40(2):339-343. doi: 10.1007/s10143-017-0816-1. Epub 2017 Jan 25.

\*\*\*\*\*