



RESEARCH ARTICLE

A COMPARATIVE STUDY OF AgNOR WITH PCNA IMMUNOHISTOCHEMICAL STAINING IN ORAL SQUAMOUS CELL CARCINOMA

¹Samir Ahmed, ²Dinkar Desai, ^{*,3}Pramod Redder Chandrappa, ²Siddarth Pandit, ²Sharan. Jayram. Shetty and ⁴Dr. Suresh, K. V.

¹Department of Oral Pathology and Microbiology, KMCT Dental College, Calicut, Kerala, India

²Department of Oral Pathology and Microbiology, A.J. Institute of Dental Sciences, Mangalore, Karnataka, India

³Associate Professor of dentistry, Batterjee Medical College, P.O box6231, Jeddah 21442

⁴Assistant Professor, Department of Oral Medicine and Radiology, SEGI University, Kulalampur, Malaysia

ARTICLE INFO

Article History:

Received 22nd February, 2017

Received in revised form

05th March, 2017

Accepted 16th April, 2017

Published online 19th May, 2017

Key words:

Argyrophilic Nucleolar Organizer Regions, Oral squamous cell carcinoma, Proliferating Cell Nuclear Antigen.

ABSTRACT

Background: The present study was to compare Argyrophilic Nucleolar Organizer Regions (AgNORs) with Proliferating Cell Nuclear Antigen (PCNA) expression in Oral squamous cell carcinoma (OSCC) and to assess the proliferating activity in OSCC, also to assess the reliability between PCNA and AgNOR.

Methods: Previously confirmed 30 cases of oral squamous cell carcinomas were taken for the study. Histological sections were prepared from paraffin embedded blocks and processed for AgNOR stain and PCNA stain according to super sensitive polymer HRP method. The statistical evaluation by ANOVA test helped us to compare and correlate between the two methods.

Results: PCNA expression in Well-differentiated OSCC was 61.6471% followed by moderately differentiated OSCC with 72.4% and poorly differentiated OSCC with 89%. The AgNOR count in the well differentiated OSCC had a mean value of 3.4 followed by moderately differentiated OSCC with 3.9 and poorly differentiated OSCC with 9.4. In the current study, on correlation between PCNA and AgNOR, the pearsons co-relation coefficient value was found to be highly significant. Whereas the relation between PCNA and AgNOR within the grades of OSCC were found to be not correlated. This was statistically not significant.

Conclusions: Proliferation activity was more in poorly differentiated OSCC followed by moderately differentiated and well differentiated OSCC. The combination of PCNA immunohistochemistry with AgNOR count appears to be an effective means of identifying the proliferating activity of squamous cell carcinoma, thereby appropriate treatment can be given.

Copyright©2017, Samir Ahmed et al. This is an open access article distributed under the Creative Commons Attribution License, which permits unrestricted use, distribution, and reproduction in any medium, provided the original work is properly cited.

Citation: Samir Ahmed, Dinkar Desai, Pramod Redder Chandrappa, Siddarth Pandit, Sharan. Jayram. Shetty and Dr. Suresh, K. V. 2017. "A comparative study of AgNOR with pcna immunohistochemical staining in oral squamous cell carcinoma", *International Journal of Current Research*, 9, (05), 49930-49934.

INTRODUCTION

The most common of oral carcinoma is squamous cell carcinoma that represents about 3 % of all human malignant tumours (Daniel Brandizzi *et al.*, 2008). The proliferating activity of these carcinomas can be studied by using proliferation associated marker "Proliferating Cell Nuclear Antigen" (PCNA). An additional method often used to evaluate cell proliferation in oral squamous cell carcinoma is the Argyrophilic staining for proteins of the Nucleolar Organizer Regions (NORs) (Costa *et al.*, 1999). The PCNA is a 36 kilodalton non histone nuclear protein which is involved in DNA synthesis. PCNA level increase rapidly in mid-G1 remains high throughout S-phase and begins to decline from G2/M to G1 phase of cell cycle. Recently it has been suggested

that the proliferative activity of tumors could be evaluated when anti-PCNA antibodies are employed (Nalan Karademir *et al.*, 1996). The NORs are particular nucleolar components which symbolize the sites for ribosomal RNA transcription and their related proteins bind with silver. In a neoplasm the degree of malignancy can be assessed using the Argyrophilic technique by scoring the interphase Nucleolar organizing region (Nalan Karademir *et al.*, 1996). These Argyrophilic nucleolar organizing regions (AgNORs) can be visualized in histological and cytological preparations as black or dark brown dots in the interphase nucleus. The mean number of AgNORs in each nucleus is counted and aids in tumour pathology as a diagnostic and prognostic marker (Papadhimitriou *et al.*, 2000). Hence the present study was to compare the relationship between the AgNOR and the immunohistochemical expression of cell proliferative marker PCNA in oral squamous cell carcinoma.

*Corresponding author: Pramod Redder Chandrappa, Associate Professor of dentistry, Batterjee Medical College, P.O box6231, Jeddah 21442

MATERIALS AND METHODS

Study consisted of previously diagnosed 30 samples of oral squamous cell carcinomas. 17 samples were of well differentiated, 12 were of moderately differentiated and 1 poorly differentiated cases. Three sections were prepared from paraffin embedded blocks of the same cases. One section was to prepare H & E (Hematoxylin and Eosin) stain just to reconfirm diagnosis, second section was prepared according to super sensitive polymer HRP (horse radish peroxidase) method for identifying immunohistochemical expression of PCNA. Third section was stained with AgNOR.

Interpretation for immunohistochemical slides

Tumor markers – blue in color

Nucleus – brown in color.

The extent of PCNA positivity was evaluated by determining the percentage of positive nuclei present in 1000 cells and this percentage was expressed as Labeling Index (LI).

Counting procedure for AgNOR

The AgNOR sites were counted in at least 100 randomly selected cells using a 100x objective under oil emulsion and AgNORs were identified. The number of individually discernable and separable block dots in each nucleus was recorded and the average for each case computed; where two or more dots were so closely aggregated within a nucleolus that the precise number within the aggregate could not be counted, the aggregate was recorded as one. The mean number of AgNORs/nucleus was used for the analysis.

Statistical Analysis

The Immunohistochemistry expression of PCNA and AgNOR counts were statistically analyzed by ANOVA test, using the formula: $F = \frac{\text{ratio of mean sum of squares between observations}}{\text{mean sum of squares in observations}}$. The interobserver variation between the two observers was calculated using the "pearsons co-relation coefficient"(r) using the formula: $r = \frac{\text{covariance between two standard deviation of the first and second variable (PCNA and AgNOR)}}{\text{standard deviation of the first and second variable}}$

RESULTS AND OBSERVATIONS

The descriptive statistics showed the mean percentage of PCNA count was 66.8 for hundred cells with a standard deviation of 7.9 and for AgNOR count was 3.84 per cells with a standard deviation of 11.4 (Table 1). The well differentiated OSCCs (61.6471%) showed lower expression of PCNA with a standard deviation of 5.01 followed by moderately differentiated OSCCs (72.4%) with a standard deviation of 3.31 and poorly differentiated OSCC with (89%).

Table 1. The descriptive statistics showed the mean percentage of PCNA and AgNOR with a standard deviation

	N	Minimum	Maximum	Mean	Std. Deviation
PCNA /100 cells	30	52.00	89.00	66.8667	7.97727
AgNOR per cell	30	2.70	9.40	3.844	11.47608

Table 2. Expression of PCNA in different grades of squamous cell carcinoma

		N	Mean	Std. Deviation	F	P
PCNA	Well differentiated	17	61.6471	5.01175	34.16	<.001 vhs
	Moderately differentiated	12	72.4167	3.31548		
	Poorly	1	89.0000			

Table 3. Argyrophilic nucleolar organizer regions (AgNORs) in squamous cell carcinoma

Squamous cell carcinoma	N	Mean	Std. Deviation	Minimum	Maximum
Well	17	3.4394	.41753	2.70	4.15
Moderate	12	3.9542	.38213	3.20	4.50
Poor	1	9.4000		9.40	9.40

F=10.801 p<0.001 vhs

Table 4. Correlation between PCNA and AgNOR- "pearsons co relation coefficient"

		AgNOR per
PCNA	R	.620**
	P	.001 v
	N	30

** Correlation is significant at the 0.01 level (2-tailed).

Table 5. Correlation between PCNA and AgNOR within the grades of OSCC

Grade		AgNOR per
Well differentiated	PCNA R	-.143
	P	.583
	N	17
Moderately differentiated	PCNA R	.046
	P	.888
	N	12

It indicates proliferation activity is more in poorly differentiated OSCC followed by moderately differentiated and well differentiated OSCC (Table 2, Graph 1, Fig-1, Fig-3, Fig-5). These results were found to be statistically very highly significant. The AgNOR count in the well differentiated OSCC ranged from 2.7-4.15 with a mean value of 3.4 and the standard deviation was found to be 0.41.

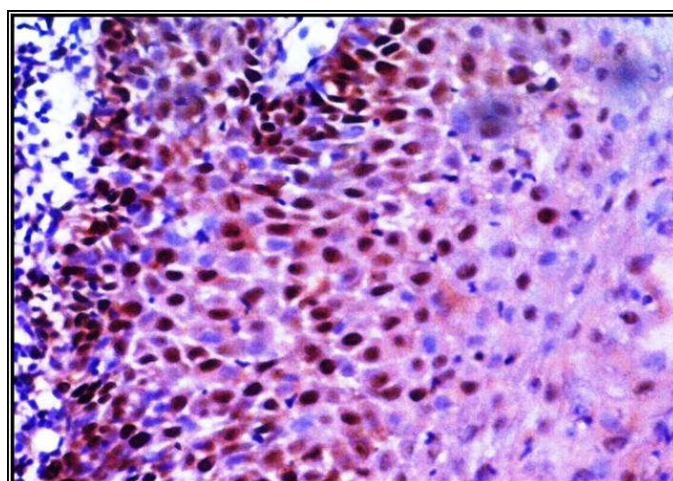


Figure 1. Photomicrograph showing positive staining of PCNA in well differentiated squamous cell carcinoma in 40x

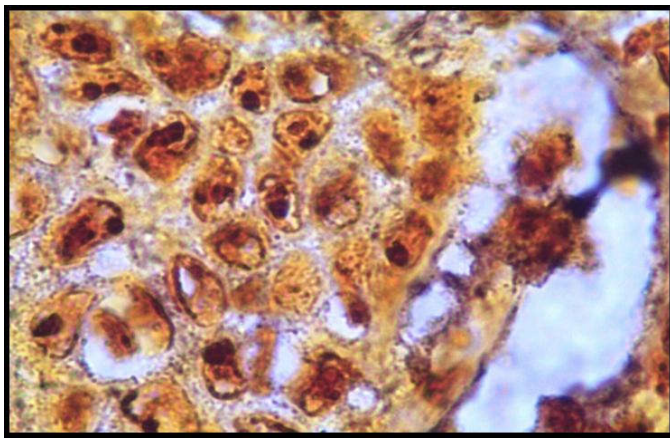


Figure 2. Photomicrograph showing positive staining of AgNOR in well differentiated squamous cell carcinoma in 100x

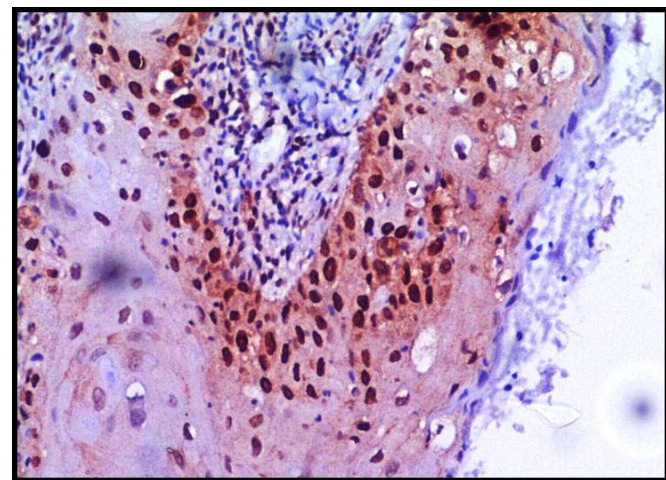


Figure 3. Photomicrograph showing positive staining of PCNA in Moderately differentiated squamous cell carcinoma in 40x

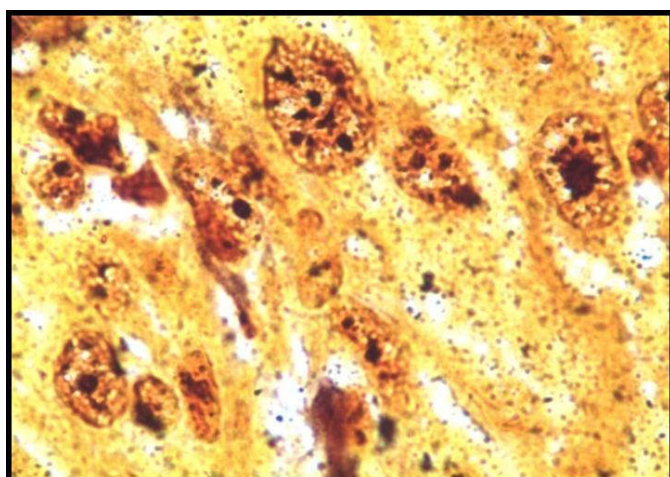


Figure 4. Photomicrograph showing positive staining of AgNOR in Moderately differentiated squamous cell carcinoma in 100x

AgNOR were correlated within the grades of OSCC, “pearsons co-relation coefficient” value was found to be not correlated.

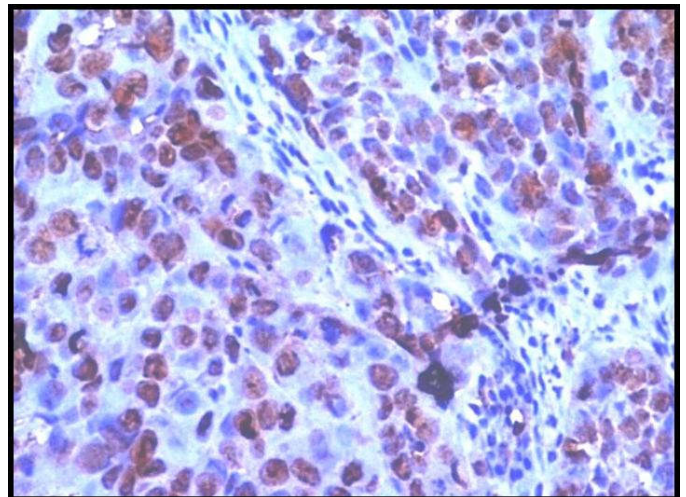


Figure 5. Photomicrograph showing positive staining of PCNA in poorly differentiated squamous cell carcinoma in 40x

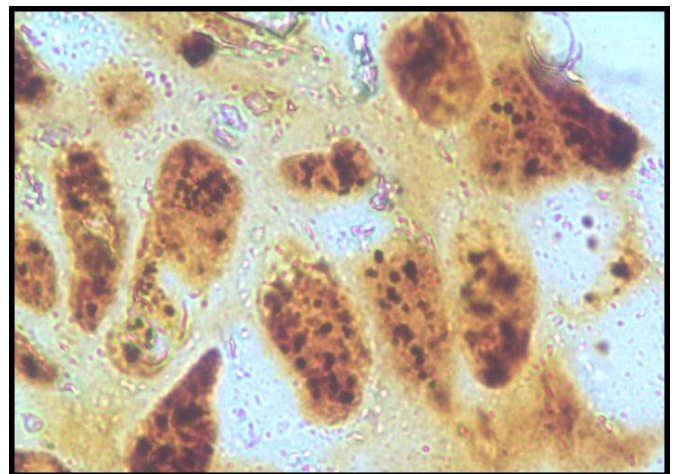
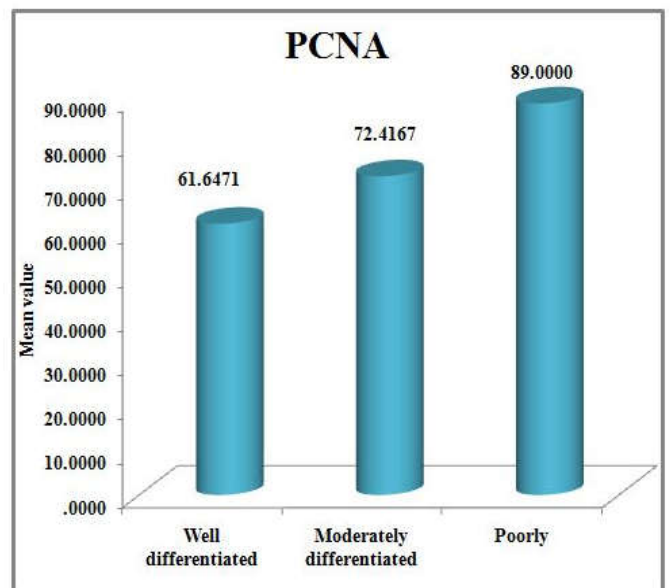
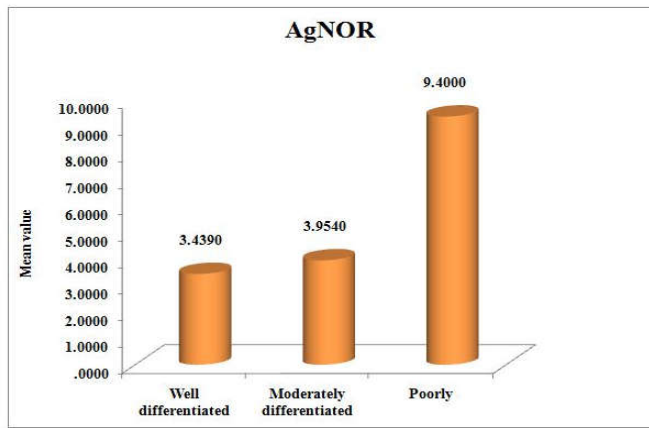


Figure 6. Photomicrograph showing positive staining of AgNOR in poorly differentiated squamous cell carcinoma in 40x

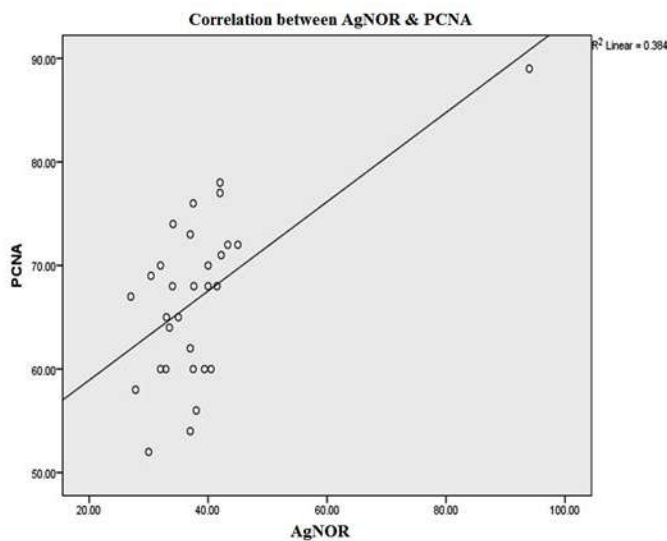


Graph 1. Indicating the proliferation activity in different grades of OSCC

The AgNOR count in moderately differentiated squamous cell carcinoma cases ranged from 3.5-4.5 with a mean value of 3.9 and the standard deviation was found to be 0.39. AgNOR count in one case of poorly differentiated squamous cell carcinoma was 9.4. (Table3, Graph2, Fig-2, Fig-4, Fig-6) On correlation between PCNA and AgNOR, the “pearsons correlation coefficient” value was found to be 0.620 for 30 samples. This correlation was statistically found to be very highly significant. (Table 4, Graph 3). When PCNA and



Graph 2. Showing the AgNOR count in different grades of OSCC



Graph 3. Correlation between PCNA and AgNOR

DISCUSSION

The quantitative assessment of PCNA expression plays a vital role in the prediction of survival rate, choice of treatment modalities and planning of prophylactic adjuvant therapy. PCNA aid in histopathological grading of OSCC (Zain *et al.*, 1995). In our study the mean count of PCNA was 66.8 for hundred cells. High expression of PCNA would signify high proliferative activity in tumours which is more precise for proliferating cells. PCNA also can be used as a biomarker for differentiating between normal epithelium from dysplastic epithelium (Zain *et al.*, 1995). The mean AgNOR count was 3.84 per cells with a standard deviation of 11.4. This was in correlation with the study done by Smith F G *et al.* (1993) in Non Hodgkin Lymphomas. According to their study AgNOR counts were relatively high in PCNA negative cells. This may indicate that PCNA and AgNORs are presented at different stages of cell cycle or may linger for different durations after mitosis. In the present study poorly differentiated OSCC showed 89% of positive cells compared with moderately differentiated and well differentiated (72.4% and 61.6% respectively, $P < 0.001$ vhs (very highly significant), $F = 34.16$). It indicates proliferation activity is more in poorly differentiated OSCC followed by moderately differentiated and well differentiated OSCC. This is in accordance with study by Hall *et al.* (1994). Wherein they reported, a correlation of

PCNA expression with cell proliferation probably induced by expression of growth factors by tumour cells and also it has been postulated by Williams *et al.* (1989) that some tumours keenly secrete platelet derived growth factor (PDGF) that can stabilize PCNA and enhance translation of PCNA mRNA without entering into the cell cycle. In our study similar to PCNA observations, AgNOR per cell also showed increased count in poorly differentiated squamous cell carcinoma (mean count 9.4) than moderately (mean count 3.9) and well differentiated squamous cell carcinoma (mean count 3.4) with $p < 0.001$ vhs, $F = 10.801$. This is in contrast with study by Rajendra *et al.* (1994) where the poorly differentiated has a mean AgNOR count of 9.4 and well differentiated 8.2. The variation in the AgNOR counts between our study and other studies cited may be due to the differences in the staining and processing procedures employed, and may also be due to the section thickness employed. As the section thickness increases the number of AgNORs also increases. Sano *et al.* (1992) proposed that the 5 year survival rate of cases with high AgNOR count (> 6.5) was significantly lower than count of (< 6.5). Therefore it was proposed that AgNOR counts might be a useful marker in assessing the prognosis of malignant lesion. Based on this proposition the AgNOR counts in our study showing very high values may be marked as having poor prognosis.

In the current study, on correlation between PCNA and AgNOR, the "pearsons co-relation coefficient value" (r) was found to be 0.0620 for 30 samples with $p < 0.001$ (table 4, graph 3) which was highly significant. Whereas the relation between PCNA and AgNOR within the grades of OSCC were found to be not correlated. This was statistically not significant. $P > 0.005$, $r = -0.143$ for 17 samples (well differentiated) and $r = 0.046$ for 12 samples (moderately differentiated) (Table 5). According to Morisaki *et al.* (1995) PCNA and AgNOR cannot be correlated, as hundred nuclei may be too few to express the proliferative capacity of each tumour. The combination of PCNA index with AgNOR count appears to be an effective means of identifying patients with poor prognosis.

Conclusions

- Proliferation activity was more in poorly differentiated OSCC followed by moderately differentiated and well differentiated OSCC.
- Similar to PCNA, AgNOR per cell also showed increased count in poorly differentiated squamous cell carcinoma than moderately and well differentiated squamous cell carcinoma.
- In the current study, on correlation between PCNA and AgNOR, the pearsons co-relation coefficient value was found to be highly significant. Whereas the relation between PCNA and AgNOR within the grades of OSCC were found to be not correlated. This was statistically not significant.

REFERENCES

- Costa Al., Araujo, N.S., Pinto Jr D.S, *et al.* 1999. PCNA/AgNOR and Ki-67/ AgNOR double staining in OSCC. *J Oral Pathol Med.*, 28,438-41.
- Daniel Brandizzi., Mariana Gandolfo., Maria Lucia Velazco., *et al.* 2008. Clinical features and evolution of oral cancer: A study of 274 cases in Buenos Aires, Argentina. *Med Oral Patol Oral Cir Buca.*, 11.3(9), 544-8

- Hall, P. A., Coates, P.J., Goodlad, R.A., Hart, I.R., Lane, D.P., 1994. Proliferating cell nuclear antigen expression in non-cycling cells may be induced by growth factors in vivo. *Br. J. Cancer*, 70,244-247
- Nalan Karademir., Mehmet,M.Orman., Tolga Guvenc., *et al.* 1996. Comparison of AgNOR staining and PCNA immune staining methods and mitotic index scores in intra cutaneous cornifying epiteloma and squamous cell carcinoma. *Ankra Univ. vet.fak.derg.* 43, 281-285
- Papadimitriou, S. I., Daskalopoulou, D., Tsaftaridis, P., *et al.* 2000. Evaluation of argyrophilic nuclear organiser regions (AgNORs) in multiple myeloma. *J clin pathol.* 53,462-465.
- Rajendran, R. and Nair, S.M. 1992. Silver-binding nucleolar organizer region proteins as a possible prognostic indicator in oral submucous fibrosis. *Oral Surg Oral Med Oral Pathol.*, 74,481-6
- Sano, K., Takahashi, H. and Fujita, S., 1992. Prognostic implication of silver-binding nucleolar organizer regions (AgNORs) in OSCC. *J Oral Pathol Med.*, 20,53-56.
- Smith, F. G., Murray, P. G., Crocker, G. 1993. Correlation between PCNA and AgNOR scores in non-Hodgkin's lymphoma using sequential staining technique. *J Clin Pathol.*, 46, 28-31
- William, R.L., Risua, W., Zerwes, H.G. *et al.* 1989. Endothelioma cells expressing polyoma middle T antigen induce hemangioma by host cell recruitment. *Cell*, 57,1053-1063
- Yoshihisa Morisaki., Shingo Shima., Yutaka Yoshizumi., *et al.* 1995. PCNA Immunostaining combined with AgNOR staining in Esophageal Squamous Cell Carcinoma to Identify Patients with a Poor Prognosis. *Jpn.J.Surg.*, 25,389-395.
- Zain, R. B., Sakamoto, F., Shrestha, P. *et al.* 1995. Proliferating cell nuclear antigen (PCNA) expression in OSCC - an aid to conventional histological grading? *Malaysian J Pathol.*, 17(1), 23 – 30.
