



RESEARCH ARTICLE

ANTIOXIDANT AND HEPATOPROTECTIVE POTENTIAL OF THE AQUEOUS DECOCTION FROM SIDDHA FORMULATION DRUG KARISALAI KARPAM

¹Bharathkumar, G., ²Kanagavalli, K., ³Bama, P., ⁴Sankaranarayanan, S. and ⁵*Pitchiah Kumar, M.

¹Department of Siddha, The Tamil Nadu Dr. MGR Medical University, Guindy, Chennai - 600 032, Tamil Nadu, India

²Department of Medicine, Government Siddha Medical College, Arumbakkam, Chennai - 600 106, Tamil Nadu, India

³Department of Biochemistry, Sri Sairam Siddha Medical College and Research Centre, West Tambaram, Chennai - 600 044, Tamil Nadu, India

⁴Department of Medicinal Botany, Government Siddha Medical College, Chennai - 600 032, Tamil Nadu, India

⁵Department of Gunapadam, Government Siddha Medical College, Chennai - 600 032, Tamil Nadu, India

ARTICLE INFO

Article History:

Received 21st February, 2017

Received in revised form

10th March, 2017

Accepted 13th April, 2017

Published online 23rd May, 2017

Key words:

Karisalai Karpam,
Antioxidant,
Aqueous decoction,
Hepatotoxicity.

ABSTRACT

The present study was conducted to evaluate the antioxidant and hepatoprotective potential of Karisalai Karpam. Antioxidant activity of the aqueous decoction of Karisalai Karpam was studied using in vitro and in vivo models, phytochemical screening result revealed the presence of alkaloid, flavonoid, tannin, flavonoid, anthocyanin, terpenoid and absence of glycosides. The Karisalai Karpam exhibited strong free radical scavenging activity as evidenced by the highest activity values in ABTS (2,2'-azino-bis-3-ethyl benzthiazoline-6-sulphonic acid) (74.23%), lipid peroxidation (81%), superoxide anion (79.5%), Metal chelating activity (84.05%), and nitric oxide scavenging activity (81.45) methods. Hepatoprotective activity of Karisalai Karpam was determined by the alcohol induced oxidative tissue injury in rat liver, the aqueous decoction showed significant hepatoprotective activity that was evident by enzymatic examination and histopathological study. This study provides a scientific basis for the ethnomedical claims that Karisalai Karpam is effective against ageing related diseases and liver injury.

Copyright©2017, Bharathkumar et al. This is an open access article distributed under the Creative Commons Attribution License, which permits unrestricted use, distribution, and reproduction in any medium, provided the original work is properly cited.

Citation: Bharathkumar, G., Kanagavalli, K., Bama, P., Sankaranarayanan, S. and Pitchiah Kumar, M. 2017. "Antioxidant and Hepatoprotective potential of the aqueous decoction from Siddha formulation drug Karisalai Karpam", *International Journal of Current Research*, 9, (05), 50435-50443.

INTRODUCTION

The reactive oxygen metabolites are generated either by the transfer of radiant energy to the oxygen molecule or by its stepwise reduction. In the former case, the molecular oxygen absorbing energy is raised to an excited state to produce singlet oxygen, whereas its stepwise reduction leads to the generation of a series of oxidant molecules, such as superoxide anions, hydrogen peroxide and hydroxyl radicals (Athar *et al.*, 1992). Usually, free radicals are generated by exposure of tissue to ionizing radiation and ultra violet light. Moreover, the metabolism of certain pesticides, drugs, alcohol and cigarette smoke and various other pollutants generate a number of reactive oxygen species and free radicals in biological systems. Besides, many enzymes such as xanthine oxidase, NAD(P)H oxidase, aldehyde oxidase and flavinhydrogenase produce

superoxide anions. The generation and subsequent involvement of free radicals in a large number of diseases such as myocardial ischemia, carcinogenesis, inflammatory diseases, cataract formation, liver diseases and Alzheimer's disease have been recognized. Liver plays a major role in detoxification and excretion of many endogenous and exogenous compounds, any hepatic injury or impairment of its function may lead to many pathological complications. Liver diseases which are still a global health problem may be classified as acute or chronic hepatitis (inflammatory liver diseases), hepatosis (noninflammatory diseases) and cirrhosis (degenerative disorder resulting in liver fibrosis). Unfortunately, treatments of choice for liver diseases are controversial because conventional or synthetic drugs for the treatment of these diseases are insufficient and sometimes cause serious side effects (Kumar *et al.*, 2011). Drug induced liver damage or liver dysfunction is the most important health crisis that challenges not only medical personnel but also the pharmaceutical field and drug control board. According to the United States Acute Liver Failure Study Group, drug induced

*Corresponding author: Pitchiah Kumar, M.

Department of Gunapadam, Government Siddha Medical College, Chennai - 600 032, Tamil Nadu, India.

liver injury accounts for more than 50% of acute liver failure, including hepatotoxicity caused by over dose of acetaminophen (39%) and idiosyncratic liver injury triggered by other drugs (Thyagarajan *et al.*, 2002). Hepatic-cell injury caused by various toxic chemicals (certain antibiotic, chemotherapeutic agents, carbon tetrachloride (CCl₄), thioacetamide (TAA) etc.), excessive alcohol consumption and microbes.

Since ancient times, mankind has made use of plants in the treatment of various ailments because their toxicity factors appear to have lower side effects (Elberry *et al.*, 2011). Many of the currently available drugs were derived either directly or indirectly from medicinal plants. Recent interest in natural therapies and alternative medicines has made researchers pay attention to traditional herbal medicine. In the past decade, attention has been centered on scientific evaluation of traditional drugs with plant origin for the treatment of various diseases. Due to their effectiveness, with presumably minimal side effects in terms of treatment as well as relatively low costs, herbal drugs are widely prescribed, even when their biologically active constituents are not fully identified (Levy *et al.*, 2004). The utility of natural therapies for liver diseases has a long history. Despite the fact that most recommendations are not based on documented evidence, some of these combinations do have active constituents with confirmed antioxidant, anti-inflammatory, anticarcinogenic, antifibrotic, or antiviral properties. Although a large number of these plants and formulations have been investigated, the studies were mostly unsatisfactory. For instance, the therapeutic values, in most of these studies, were assessed against a few chemicals-induced subclinical levels of liver damages in rodents. The reasons that make us arrive at such a conclusion are lack of standardization of the herbal drugs, limited number of randomized controlled clinical trials, and paucity of traditional toxicologic evaluations (Thyagarajan *et al.*, 2002). Hepatotoxicity implies chemical driven liver damage. Hepatotoxicity is the main reason for the withdrawal of many drugs from the market as more than 900 drugs are reported to produce toxicity to the liver. Other chemical agents such as those used in laboratories and industries, natural chemicals and herbal remedies can also induce Hepatotoxicity. As liver is an important metabolic organ and also a vulnerable one to the various factors, the importance of a hepato-protective is increasing manifold nowadays. The therapeutic benefits of traditional Siddha medicines have been recognized for centuries.

Although there is still lack of evidence for clarification of their typical mechanisms, unlike with Western medicine, it is still widely accepted by people from East Asia and beginning to be accepted by the rest of the world. Karisalai Karpam (Poly herbals preparation contained medicinal plants are *Eclipta alba*, *Wedelia chinensis*, *Indigofera tinctoria*, *Sphaeranthus indicus*, *Centella asiatica*, *Acalypha indica* and *Coldenia procumbens*, as a folk medicine for the treatment of some ailments associated with inflammation as hepatitis for over 2000 years, is widely distributed in tropical Asia. The present study confirms the therapeutic utility of the sashthri formulation Karisalai Karpam as hepatoprotective agents. Individually single plant extract has been reported to have hepatoprotective activity. However, literature survey shows that no sufficient scientific data have been submitted on pharmacological evaluation of these plants in combined form.

So it was decided to prepare and evaluate the formulation for its protective effect against the hepatotoxins like ethanol.

MATERIALS AND MATERIALS

Collection of plant

The composition of Karisalai Karpam chooranam as per the Siddha sashthri preparation contained medicinal plants are *Eclipta alba* (Vellai Karisalai Samoolam), *Wedelia chinensis* (Manjal Karisalai Samoolam), *Indigofera tinctoria* (Neeli Samoolam) *Sphaeranthus indicus* (Kottakaranthai Samoolam), *Centella asiatica* (Vallarai Samoolam) *Acalypha indica* (Kuppaimeni) and *Coldenia procumbens* (Siru Serupadai) collected from Sairam Herbal garden, Department of Medicinal Botany, Sri Sairam Siddha Medical College and Research Centre, West Tambaram, Chennai-44, Taminadu, India. Plants are authenticated by Dr. S. Sankaranarayanan, Head Department of Medicinal Botany, Government Siddha Medical College, Arumbakkam, Chennai-600 106.

Phytochemical Analysis of Karisalai Karpam

The aqueous decoction of Karisalai Karpam were freshly prepared and various chemical constituents were analysed according to methods described by Allen, (1974) and Harbone, (1976). The different chemical constituents tested for included tannins, saponin, glycosides, alkaloids, terpenoids, anthocyanin, polyphenol and flavonoids. *High Performance Thin-layer chromatography (HPTLC)* fingerprint profile of Karisalai Karpam. HPTLC was performed on silica gel 60 F₂₅₄, 20X10 cm HPTLC plates (Merck, Germany-#5642), with ethyl acetate: methanol: formic acid: water [20:2.5:0.5:2 (v/v)] as a mobile phase. The Karisalai Karpam solutions (5.0 µL of each concentration 1 mg/mL) were applied to the plates as 10 mm bands, sample application with CAMAG-Linomat IV automated spray on band applicator equipped with a 100 µL syringe and operated with following settings: band length 10 mm, application rate 10 sec/ µL, distance between 4 mm, distance from the plate side edge 1.5 cm and distance from the bottom of the plate 2 cm. CAMAG TLC Scanner 3 was used to densitometrically to quantify the bands using WIN CATS software (Version 4 X). The scanner operating parameters were: (Mode: absorption / reflection; Slit dimension; 5 x 0.1 mm; scanning rate: 20 mm/s and monochromator band width: 20 nm at an optimized wavelength 254, 366 nm and in visible range).

ABTS (2,2'-azino-bis-3-ethyl benzthiazoline-6-sulphonic acid) radical scavenging assay of different solvent extracts from Karisalai Karpam

ABTS radical scavenging activity of aqueous decoction from Karisalai Karpam was determined according to Re *et al.* (1999). ABTS radical was freshly prepared by adding 5 ml of a 4.9 mM potassium persulfate solution to 5 ml of a 14 mM ABTS solution and kept for 16 h in dark. This solution was diluted with distilled water to yield an absorbance of 0.70 at 734 nm and the same was used for the antioxidant assay. The final reaction mixture of standard group was made up to 1 ml with 950 µl of ABTS solution and 50 µl of Vit-C. Similarly, in the test group 1 ml reaction mixture comprised 950 µl of ABTS solution and 50 µl of the extract solutions. The reaction mixture was vortexed for 10 s and after 6 min absorbance was

recorded at 734 nm against distilled water by using an ELICO (SL150) UV-Vis Spectrophotometer and compared with the control ABTS solution. Ascorbic acid was used as reference antioxidant compound.

Superoxide radical scavenging assay of different solvent extracts from Karisalai Karpam

This assay was based on the capacity of the extract to inhibit the photochemical reduction of nitroblue tetrazolium (NBT) in the presence of the riboflavin-light-NBT system, as described earlier (Beauchamp and Fridovich, 1971). In brief, each 3 ml reaction mixture contained 50 mM phosphate buffer (pH 7.8), 13 mM methionine, 2 μ M riboflavin, 100 μ M EDTA, NBT (75 μ M) and different concentration of aqueous decoction of Karisalai Karpam sample solution. It was kept in front of fluorescent light and absorbance was taken after 6 min at 560 nm by using an ELICO (SL150) UV-Vis Spectrophotometer. Identical tubes with reaction mixture were kept in the dark and served as blanks. The percentage inhibition of superoxide generation was measured by comparing the absorbance of the control and those of the reaction mixture containing test sample solution.

$$\% \text{ Super oxide radical scavenging capacity} = [(A_0 - A_1)/A_0] \times 100$$

Where A0 was the absorbance of control and A1 was the absorbance of aqueous decoction.

Inhibition of Lipid Peroxidation activity of different solvent extracts from Karisalai Karpam

Lipid peroxidation induced by Fe²⁺-ascorbate system in egg yolk was estimated as thiobarbituric acid reacting substances (TBARS) by the method of Ohkawa *et al.* (1979). The reaction mixture contained egg yolk 0.1 ml (25% w/v) in Tris-HCl buffer (20mM, pH 7.0); KCl (30mM); FeSO₄(NH₄)₂SO₄.7H₂O (0.06mM); and various concentrations of aqueous decoction of Karisalai Karpam in a final volume of 0.5ml. The reaction mixture was incubated at 37°C for 1 h. After the incubation period, 0.4ml was removed and treated with 0.2ml sodium dodecyl sulphate (SDS) (1.1%); 1.5 ml thiobarbituric acid (TBA) (0.8%); and 1.5 ml acetic acid (20%, pH 3.5). The total volume was made up to 4.0 ml with distilled water and then kept in a water bath at 95 to 100 °C for 1 h.

After cooling, 1.0 ml of distilled water and 5.0 ml of n-butanol and pyridine mixture (15:1 v/v) were added to the reaction mixture, shaken vigorously and centrifuged at 4000 rpm for 10 min. The butanol-pyridine layer was removed and its absorbance at 532 nm (ELICO (SL150) UV-Vis Spectrophotometer) was measured to quantify TBARS. Inhibition of lipid peroxidation was determined by comparing the optical density (OD) of treatments with that of the control. Ascorbic acid was used as standard. Inhibition of lipid peroxidation (%) by the extract was calculated according to 1-(E/C) X 100, where C is the absorbance value of the fully oxidized control and E is absorbance of the test sample.

Metal chelating activity of different solvent extracts from Karisalai Karpam

Metal chelating capacity of aqueous decoction of Karisalai Karpam was measured according to the method described by

Iihami *et al.* (2003). 1 mL of different concentrations of ethanolic extract was added to a 0.05ml of 2 mM ferric chloride solution. The reaction was initiated by the addition of 0.2 mL of 5 mM Ferrozine and the mixture was shaken vigorously. After 10 min, the absorbance of the solution was measured at 562 nm against blank. All readings were taken in triplicate and Vitamin C was used as the standard. The % inhibition of ferrozine-Fe²⁺ complex was calculated by following equation.

$$\% \text{ Inhibition of ferrozine-Fe}^{2+} \text{ complex} = [(A_0 - A_1)/A_0] \times 100$$

Where A0 was the absorbance of control and A1 was the absorbance of aqueous decoction.

Nitric oxide radical scavenging activity of different solvent extracts from Karisalai Karpam

Nitric radical scavenging capacity of aqueous decoction of Karisalai Karpam was measured according to the method described by Olabinri *et al.* (2010). 0.1ml of sodium nitroprusside (10mM) in phosphate buffer (0.2 M, pH 7.8) was mixed with different concentration of aqueous decoction and incubated at room temperature for 150 min. After incubation period, 0.2 mL of Griess reagent (1% Sulfanilamide, 2% Phosphoric acid and 0.1% N-(1-Naphthyl) ethylene diamine dihydrochloride) was added. The absorbance of the reaction mixture was read at 546nm against blank. All readings were taken in triplicate and Vitamin-C was used as the standard. The % inhibition was calculated by following equation.

$$\% \text{ Nitric oxide radical scavenging capacity} = [(A_0 - A_1)/A_0] \times 100$$

Where A0 was the absorbance of control and A1 was the absorbance of aqueous decoction.

Hepatoprotective activity of study drug Karisalai Karpam was carried out in Chronic alcohol-induced liver injury model in rats

Chronic alcohol-induced liver injury model in rats

Alcoholic liver disease (ALD) is a complex process that includes a wide spectrum of hepatic lesions, from steatosis to cirrhosis. Cell injury, inflammation, oxidative stress, regeneration and bacterial translocation are key drivers of alcohol-induced liver injury.

Experimental Animals

Healthy adult Wistar albino male rats weighing between 200-220 g were used for the study. The animals were housed in polypropylene cages and were kept in well ventilated with 100% fresh air by air conditioning. A 12 light / dark cycle were maintained. Room temperature was maintained between 22 \pm 2 °C and relative humidity 50–65%. They were provided with food (Sai feeds, Bangalore, India) and water *ad libitum*. All the animals were acclimatized to the laboratory for 7 days prior to the start of the study (OECD, 2008). The experimental protocol was approved by The Institutional Animal Ethics Committee of Sathyabama University, Chennai, Tamil Nadu, India.

Approval reference number-SU/CLATR/IAEC/IV/013/2016**Animal Grouping Details**

- Group I : Administered with normal saline 5 ml/kg (p.o)
 Group II : Administered with alcohol (0.5ml/100gm, p.o)
 Group III : Administered with alcohol (0.5ml/100gm, p.o) and treated with honey 40mg/kg, p.o.
 Group IV : Administered with alcohol (0.5ml/100gm, p.o) and treated with Karisalai Karpamin honey at the dose of 200mg/kg, p.o.
 Group V : Administered with alcohol (0.5ml/100gm, p.o) and treated with Karisalai Karpamin honey at the dose of 400mg/kg, p.o.

Induction and Treatment schedule on Alcohol Induced Hepatic Injury Model

Induction of liver damage in rats was carried out by administration of alcohol at the dose of 0.5 ml/100gm body weight (Jain *et al.*, 2009) Liver damage was induced in all groups except control group. Animal belongs to group I (Control) administered with normal saline 5 ml/kg (p.o). No treatment given to animals belongs to group II (Disease control) from 0 -7 days, from 8th to 35th day, ethanol (0.5ml/100gm) was given orally. Animals belongs to group III (Vehicle control) pretreated with honey (40mg/kg), p.o (0-7 days) and administered with ethanol (0.5ml/100gm), p.o from day 8th to 35th day along with honey one hour after ethanol administration. Animals belongs to group IV and V pretreated with low (200mg/kg) and high dose (400mg/kg) of study drug Karisalai Karpamin honey, p.o (0-7 days) and administered with ethanol (0.5ml/100gm), p.o from day 8th to 35th day along with test drug one hour after ethanol administration. At the end of the study period all the rats were sacrificed for serum liver enzyme estimation and histopathological analysis.

Masson's trichrome staining

5µm thick sections of liver samples were prepared for Masson's trichrome (Sigma, USA) staining as a marker for detecting the degree of fibrosis and observing the collagen fibers developed in liver tissues. Examination of the slides was performed under a light microscope, and digital images were captured using Olympus CX 41 microscope at the magnification ×40. Masson's trichrome stained liver showing fibrous tissue. The fibrous tissue is stained blue while the cytoplasm of hepatocytes are stained red. The nuclei can be seen as dark red to black structures within cells; Collagen in the fibrous tissue are stained Blue (with aniline blue).

Statistical analysis

The statistical analysis will be carried by one way ANOVA (GRAPH PAD PRISM 5 computer program). Results were expressed as mean ± standard error. A statistical comparison was carried out using the Dunnett's test for the control and treatment group. P-values less than 0.05 were set as the level of significance.

RESULTS AND DISCUSSION**Phytochemical screening of Karisalai karpam**

Phytochemical screening provides basic information about medicinal importance of a plant extract. In this study

evaluation for qualitative analysis of the chemical constituents of Karisalai Karpam aqueous decoction showed the presence of various secondary metabolites. The results revealed the presence of alkaloid, saponins, flavonoid, tannins, polyphenols, anthocyanin and triterpenes. Cardiac glycosides was not detected in aqueous decoction (Table-1).

High performance thin-layer chromatography (HPTLC) fingerprint profile of Karisalai Karpam

HPTLC study reveals the presence of nine prominent peaks. First largest prominent peak with Rf value of 0.10 with peak area of 494.1. Second largest peak with Rf value of 0.11 with peak area of 312.0 and third peak with Rf value of 0.16 with peak area of 23.5. The fourth less prominent peak with Rf value of 0.21 with peak area of 62.1, fifth least prominent peak with Rf value of 0.26 with peak area of 33.7. Peak six, seven and eight with Rf value of 0.42, 0.46, 0.50 and their corresponding peak area are 245.0, 250.1, 98.7. The ninth very less prominent peak appears with the Rf value of 0.73 with corresponding peak area of 16.2 (Table-2 and Fig-1).

ABTS radical activity of aqueous decoction of Karisalai Karpam

Aqueous decoction of Karisalai Karpam exhibited a powerful scavenging activity for ABTS radical cations in a concentration dependent manner (Fig-2), showing a direct role in catching free radicals. Maximum inhibition was observed with the aqueous decoction ranges from 29.14 to 74.23% at 25-100 µl/ml of Karisalai Karpam and minimum inhibition was observed with the Vitamin-C ranges 23.93 to 73.37% at 25-100 µl/ml. This property may be credited to the presence of polyphenolics and flavones in the decoction of Karisalai Karpam. ABTS radical involves a hydrogen atom transfer process. In this assay, the good antioxidant activity on ABTS radical of Karisalai Karpam may be attributed to a direct role in trapping free radicals by donating hydrogen atom. Therefore, it is important to discover some chemicals with good scavenging capacity on these reactive oxygen species (Rajani and Kanaki, 2008).

All the observations in different groups showed significant (P < 0.01) relationship between the concentration and percentage inhibition (Pearson's correlation analysis). ^aMean ± SD.

Inhibition of lipid peroxidation by aqueous decoction of Karisalai Karpam

Aqueous decoction of Karisalai Karpam also inhibited the lipid peroxidation induced by ferrous sulfate in egg yolk homogenates. Maximum inhibition was observed with total aqueous decoction with inhibition percentage 24.13 to 81.8 and 22.1.63 to 79.083 at 100 µg/ml than other fractions (Fig-3). This activity of lipid peroxidation is possibly either due to chelation of Fe or by corner of the free radicals. Iron also plays a major role for the formation of lipid peroxidation in the body. This inhibition of lipid peroxidation may be either due to chelation of Fe or by trapping of the free radical. To test this situation, we further investigated the role of Karisalai Karpam on metal chelation and other free radical species. Tondon and Gupta (2005) have also reported similar antioxidant properties of *Vitex negundo* in rats, by using ethanol induced oxidative stress model.

Table 1. Phytochemical screening of aqueous decoction from Karisalai Karpam

S.No.	Phytochemical Constituents	Result indicated	Extract of Karisalai Karpam
1.	Alkaloids Dragendorffs reagent	Brown precipitation	+
	Mayears reagent	Yellow precipitation	+
2.	Flavonoids Alkalaine test	Yellow coloration	+
	Lead acetate	Immediate precipitation	+
3.	Polyphenols Ferrozine Test	Blue Coloration	+
4.	Terpenoids Salkowski test	Brown ring	-
5.	Tannins	Dark green blue	+
6.	Glycosides Keller-Killani test	Reddish brown ring	-
	Bronbagers Test	Pink colour in ammonia layer	-
7.	Saponins	Foam	+
	Froth Test		
8.	Anthocynin Ammonia Test	Yellow colour in ammonia layer	+

-- = Negative (absent); + = Positive (present)

Table 2. HPTLC finger printing of Karisalai Karpam

S.No	Rf	Height	Area	Lamda Max
1	0.10	20.6	494.1	504
2	0.11	18.5	312.0	504
3	0.16	1.0	23.5	506
4	0.21	2.5	62.1	506
5	0.25	1.9	33.7	506
6	0.42	6.5	245.0	506
7	0.46	7.1	250.1	506
8	0.50	4.1	98.7	506
9	0.73	1.4	16.2	506

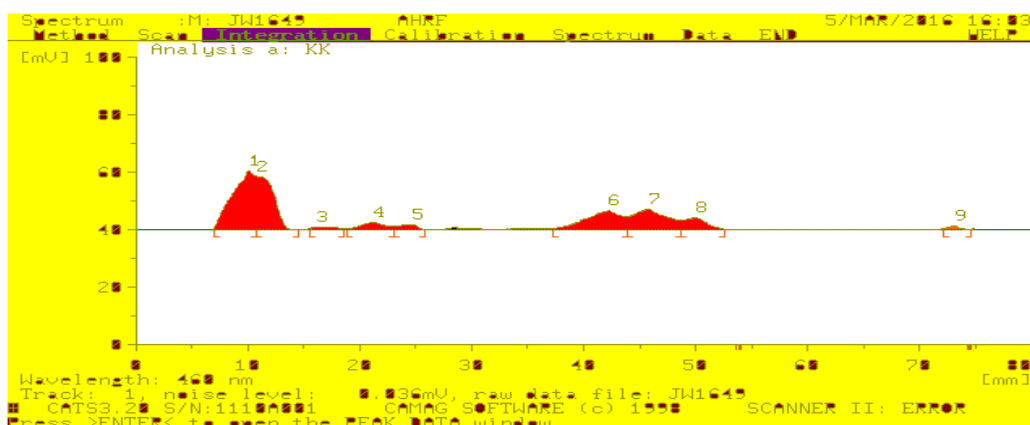


Fig.1. HPTLC finger print profile retantion factor value of Karisalai Karpam

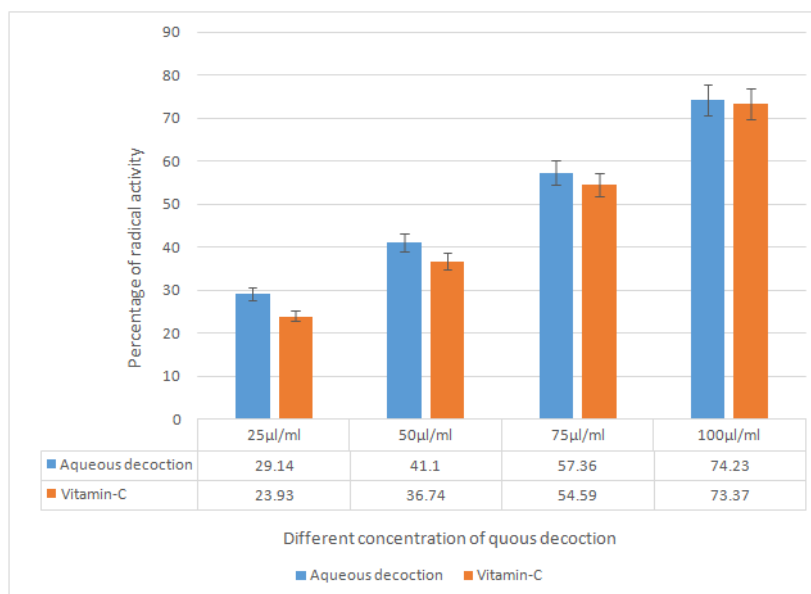


Fig.2. ABTS radical activity of aqueous decoction from Karisalai Karpam

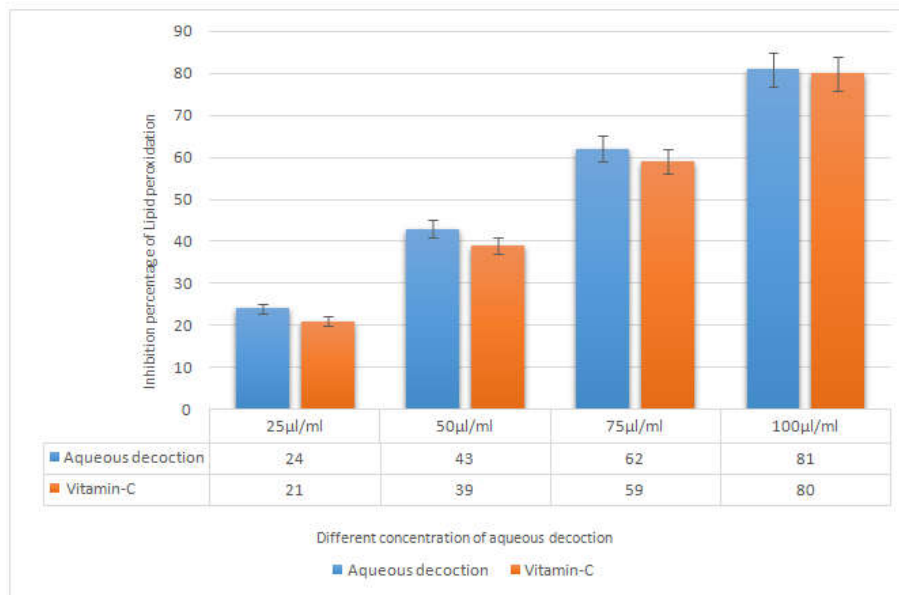


Fig.3. Inhibition of lipid peroxidation by aqueous decoction of Karisalai Karpam

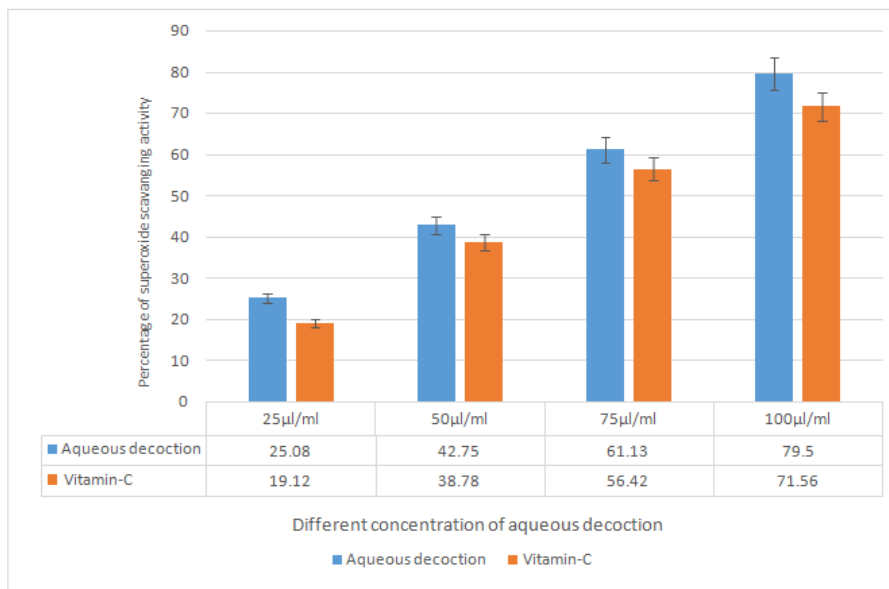


Fig.4. Superoxide radicals scavenging activity of aqueous decoction of Karisalai Karpam

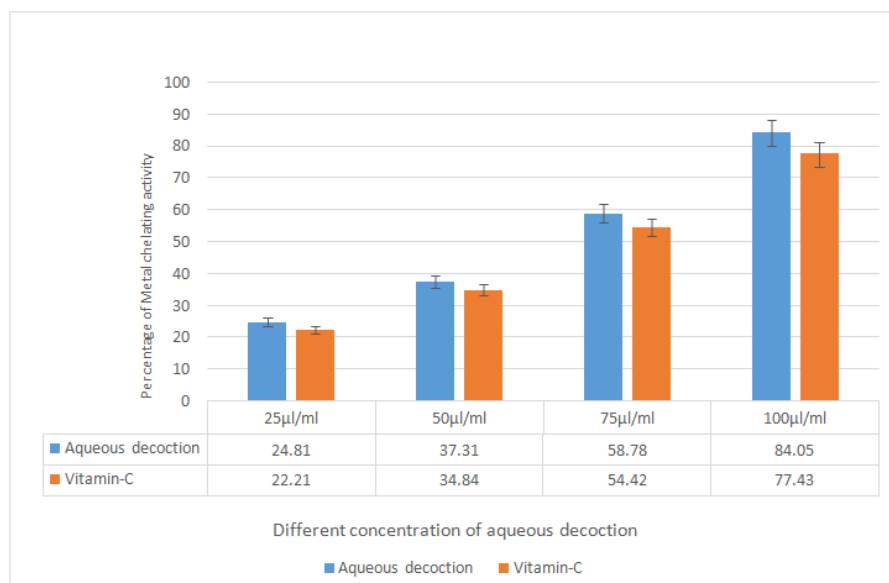


Fig.5. Metal chelating activity of aqueous decoction from Karisalai Karpam

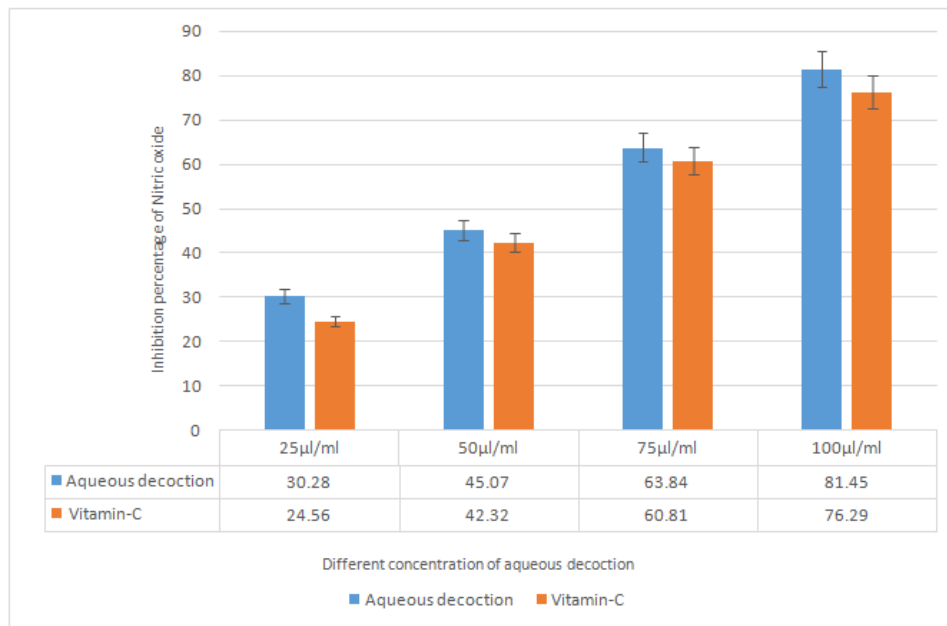


Fig.6. Nitric oxide scavenging assay of aqueous decoction from Karisalai Karpam

Table 2. Effect of Karisalai Karpamon Serum Liver enzyme level in Alcohol Induced Hepatic Injury Model in rats

Group	Treatment	(AST) (IU/ml)	(ALT) (IU/L)	(ALP) (IU/L)	Serum Bilirubin		
					Total Bilirubin mg/dl	Direct Bilirubin mg/dl	Indirect Bilirubin mg/dl
Group I	Normal saline 5 ml/kg	69.33±2.917	29.17±2.5	111.5±3.6*	0.48±0.04*	0.29±0.02*	0.18±0.02*
Group II	Ethanol 0.5ml/100gm	104.7±3.9*	52.67±2.5*	135.3±4.6*	1.91±0.1*	1.18±0.08**	0.72±0.06*
Group III	Ethanol 0.5ml/100gm+ Honey 40mg/kg	93.17±3.3*	43.67±2.14*	128.8±1.64*	1.55±0.11*	0.94±0.08*	0.61±0.05*
Group IV	Ethanol 0.5ml/100gm + KK 200 mg/kg	81±1.67**	40.17±2.4**	120.2±1.1*	1.18±0.08*	0.72±0.05*	0.46±0.03*
Group V	Ethanol 0.5ml/100gm + KK 400 mg/kg	78.17±2.2**	37±2.78*	121.3±8.4**	0.73±0.05*	0.44±0.03**	0.28±0.02**

Values are expressed as mean ± S.E.M. (N=6). Symbols represent statistical significance: *p<0.05, **p<0.01. One way ANOVA followed by Dunnett's test.

Table 3. Effect of Karisalai Karpamon Liver weight of rats in Alcohol Induced Hepatic Injury Model

Group	Treatment	Weight of the Liver in gms
Group I	Normal saline 5 ml/kg	5.48± 0.19
Group II	Ethanol 0.5ml/100gm	8.33±0.23*
Group III	Ethanol 0.5ml/100gm+ Honey 40mg/kg	7.51±0.16*
Group IV	Ethanol 0.5ml/100gm + KK 200 mg/kg	6.96±0.25*
Group V	Ethanol 0.5ml/100gm + KK 400 mg/kg	6.05±0.15*

Values are expressed as mean ± S.E.M. (N=6). Symbols represent statistical significance: *p<0.05. One way ANOVA followed by Dunnett's test

All the observations in different groups showed significant ($P < 0.01$) relationship between the concentration and percentage inhibition (Pearson's correlation analysis). ^aMean ± SD.

Superoxide radicals scavenging activity of aqueous decoction from Karisalai Karpam

Superoxide radicals can be scavenged by photochemical decrease of nitro blue tetrazolium (NBT) in the occurrence of a riboflavin-light-NBT system, which is one of the standard methods. The Aqueous decoction of Karisalai Karpam exhibited potent scavenging activity for superoxide radicals in a concentration dependent manner (Fig-4). The aqueous decoction fraction had highest Superoxide radicals scavenging percentage 79.50 ± 0.79 at $20 \mu\text{g/ml}$ and Vitamin C was least potent with 71.56 ± 1.38 value at $100 \mu\text{g/ml}$. Removal of superoxide in a concentration dependent manner by aqueous decoction may be attributed to the direct reaction of its phytochemicals with inhibition of the enzymes. Numerous

biological reactions generate superoxide radical which is a highly toxic species. Although they cannot directly initiate lipid oxidation, superoxide anion radical are potential precursors of damaging oxygen species and thus the study of the scavenging of this radical is important (Rajani and Kanaki, 2008).

Metal chelating activity of aqueous decoction from Karisalai Karpam

The chelating properties of aqueous decoction of Karisalai Karpam contribute to their antioxidant activity. Through removing and neutralizing iron ions from iron-loaded hepatocytes, Poly phenol metabolites inhibit oxidative damage. Fig-5 shows the chelating effect of the Karisalai Karpam aqueous decoction, on ferrous ions. Similarly, the ability of chelating ferrous ions also increased with the concentration ranges from $25\text{-}100 \mu\text{g/ml}$ of the Karisalai Karpam extracts to a certain point, after that leveled off as the concentration further increased. At a dose level of $100 \mu\text{g/ml}$, the chelating

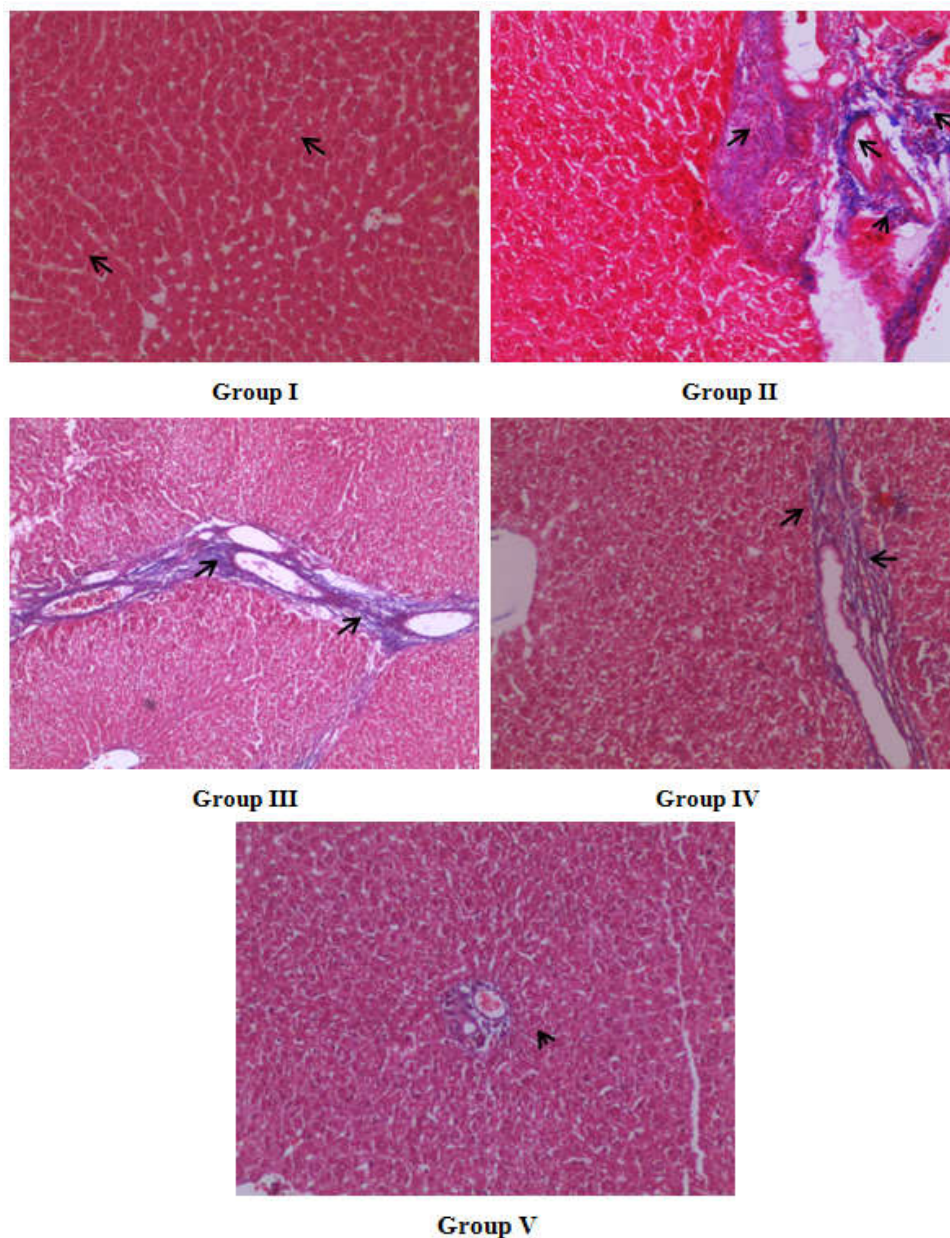


Fig.7. Masson's trichrome staining of Alcohol Induced liver injury in Rats Histopathology of Liver

effect of the Karisalai Karpam aqueous decoction could reach to 84.08% than other organic solvent extract. Fe^{2+} has been shown to cause the production of oxyradicals and lipid peroxidation, minimizing Fe^{2+} concentration in Fenton reaction affords protection against oxidative damage (Chethan *et al.*, 2012).

Nitric oxide scavenging assay of aqueous decoction from Karisalai Karpam

Nitric oxide injury takes place in most of the part through peroxynitrite route because peroxynitrite can directly oxidize LDLs, resulting in irreversible damage to the cell membrane. Inhibition increased with increasing concentration of the extract. Present study with aqueous decoction of Karisalai Karpam showed Nitric oxide scavenging activity. It is observed that the scavenging activity of aqueous decoction ranges 81.04 ± 1.67 at $100 \mu\text{g/ml}$ compared with 76.29 ± 0.85 $100 \mu\text{g/ml}$ for vitamin C which served as positive control (Fig-6). The present study demonstrated a decoction acts as Nitric oxide scavenging due to extracts

contain poly phenol compounds; free radicals are scavenged and therefore can no longer react with nitric oxide, resulting in less damage (Shutenko *et al.*, 1999). Nitric oxide is produced by several different types of cells, including endothelial cells and macrophages. Although the early release of nitric oxide through the activity of constitutive nitric-oxide synthase is important in maintaining the dilation of blood vessels, the much higher concentrations of nitric oxide produced by inducible nitric-oxide synthase in macrophages can result in oxidative damage (Wong *et al.*, 1988).

Effect of Karisalai Karpam on serum liver enzyme level in alcohol induced hepatic injury model in rats

The result of the study clearly showed that rats treated with ethanol (0.5ml/100gm) belongs to group II shown significant elevation in the level of AST, ALT, ALP, total, direct and indirect bilirubin when compared to group I (Table-2). Similarly rats treated with honey 40mg/kg belongs to group III has shown very mild decrease in the level of such markers. Treatment with Karisalai Karpam at the dose of 200 and 400

mg/kg to group IV and V showed significant decrease in the level of AST, ALT, ALP, total, direct and indirect bilirubin. The results are correlated with Padmanabhan and Jangle (2014) who has proved that the alcohol feeding cause elevation in serum activities of AST, ALT, ALP, γ GT and LDH enzymes which are markers of liver damage. Visavadiya *et al.* (2007) also reported that the ethanol treated group resulted in substantial increase in AST and ALT activities, which is a sign of hepatocellular damage in rats, whereas treatment with a flavonoid compound quercetin reduced ethanol –induced toxicity as specified by the lowering of marker enzymes.

Effect of Karisalai Karpam on liver weight of rats in alcohol induced hepatic injury model

Liver weights of rats treated with ethanol (0.5ml/100gm) were significantly increased when compared to that of the control group treated with normal saline. Similarly rats treated with honey 40mg/kg belongs to group III has shown marked decrease in liver weight (Table-3). Treatment with Karisalai Karpam at the dose of 200 and 400 mg/kg to group IV and V showed significant decrease in the liver weight.

Masson's trichrome staining of alcohol induced liver injury in rat

Microscopic observation of masson's trichrome stained liver belongs to control group rats showed normal architecture of hepatocyte with intact arrangement of prominent nucleus. Arrangement of sinusoids was normal with no signs of fibrosis. Liver section of disease control group II showed characteristic deposition of collagen fibrous tissue in central vein zone and radiating in between the cords of the hepatocytes. Histological observation of sample belongs to group III showed moderate collagen deposition indicating moderate fibrosis. Liver section of group IV, V treated with low (200mg/kg) and high dose (400mg/kg) of test drug Karisalai Karpam shown reduced level of fibrosis with restored hepato cellular architecture in treated rats (Fig-7). Cytokines are formed in excess particularly TNF- α by hepatic Kupffer cells, which plays a major role in causing hepatic damage, when administered with alcohol both in acute and chronic. Furthermore, prolong administration of alcohol results in increased hepatic lipids, lipid peroxides led to the autooxidation of hepatic cells acting as pro-oxidants and decrease in antioxidant levels, resulting in a noteworthy hepatotoxicity (Kumar *et al.*, 2013).

Conclusion

The present results confirmed that Karisalai Karpam may play a vital role in the protection against alcohol induced hepatotoxicity and oxidative stress. Pre-treatment with Karisalai Karpam may protect the liver from the hepatotoxic effect and oxidative stress caused by alcohol. Moreover, the drug Karisalai Karpam appears to be relatively safe, non-toxic, causes no apparent organ damage. Collectively the findings of the present study would recommend that the long term usage of this drug has no adverse effect.

REFERENCES

Allen ST. 1974. Chemical analysis of ecological material. Blackwell Scientific Publication, New York, pp. 313.
Athar M, Agarwal R, Bickers DR and Mukhtar H. 1992. Role of reactive oxygen species in skin. In: H. Mukhtar (Eds.),

Pharmacology of the Skin, CRC Press Inc., Boca Raton, Florida, USA, pp. 269-282.
Beauchamp C. and Fridovich I. 1971. Superoxide dismutase: improved assay and an assay applicable to acrylamide gels. *Analytical Biochemistry*, 44: 276-287.
Chethan J, Sampath Kumara KK, Niranjana SR. and Prakash HS. 2012. Evaluation of antioxidant and antibacterial activities of methanolic flower extract of *Wedeliatri lobata* (L.) Hitch. *Afr. J. Biotechnol.*, (11): 9829-9834.
Elberry AA, Harraz FM, Ghareib SA, Gabr SA, Nagy AA, Abdel-Sattar E. 2011. Methanolic extract of *Marrubium vulgare* ameliorates hyperglycemia and dyslipidemia in streptozotocin-induced diabetic rats. *Int J Diabetes Mellit*, 11: 1877-1878.
Harbone JR. 1976. Phytochemical methods. A guide to modern techniques of plant analysis. Charpan and Hall, London, pp.78.
Iihami G, Emin BM, Munir O, Irfan KO. 2003. Antioxidant and analgesic activities of turpentine of pinusnigra Arnsusspallisian A (Lamb) Holmboe. *J. Ethnopharmacology*, 86: 51-58.
Jain N, Sharma P, Sharma N. and Joshi S C. 2009. Haemato-biochemical profile following sub acute toxicity of malathion in male albino rats. *Pharmacology*, online, 2: 500-506.
Kumar CH, Ramesh A, Kumar JNS and Ishaq BM. 2011. A review on hepatoprotective activity of medicinal plants. *Int J Pharm Sci Res.*, (2): 501-515.
Levy C, Seeff LD and Lindor KD. 2004. Use of herbal supplements for chronic liver disease. *Clin. Gastroenterol. Hepatol.*, 2: 947-956.
OECD 2008. Guide lines 407 for testing of chemicals. Repeated dose 28-Day Oral Toxicity Study in Rodents. 2- 8.
Ohkawa H, Ohisi N. and Yagi K. 1979. Assay for lipid peroxides in animals tissue by thiobarbituric acid reaction. *Analytical Biochemistry*, 95: 351-358.
Olabinri BM, Odedire OO, Olaleye MT, Adekunle AS, Ehigie LO. and Olabinri PF. 2010. In vitro evaluation of hydroxyl and nitric oxide radical scavenging activities of artemether. *Research Journal of Biological Science*, 5 (1): 102-105.
Padmanabhan, P. and Jangle SN. 2014. Hepatoprotective activity of herbal preparation (HP-4) against alcohol Induced hepatotoxicity in mice. *Int J Appl Sci Biotechnol.*, 2(1): 50-8.
Rajani M. and Kanaki NS. 2008. Phytochemical Standardization of Herbal Drugs and Polyherbal Formulations, Bioactive Molecules and Medicinal Plants. Berlin, Heidelberg: Springer. pp. 349-69.
Re R, Pellegrini N, Proteggente A, Pannala A, Yang M, Rice-Evans, C. 1999. Antioxidant activity applying an improved ABTS radical cation decolorization assay. *Free Radic Biol Med.*, 26: 1231-1237.
Thyagarajan SP, Jayaram S, Gopalakrishnan V, Hari R, Jayakumar P and Sripathi MS. 2002. Herbal medicines for liver diseases in India. *J Gastroenterol Hepatol.*, 17: 370-376.
Tondon V. and Gupta RK. 2005. Effect of Vitexnegundo on oxidativestress. *Indian Journal of Pharmacology*, 37:37-45.
Visavadiya, NP. and Narasimhacharya, AVR. 2007. Hypocholesteremic and antioxidant effects of *Withania somnifera* (Dunal) in hypercholesterolemic rats. *Phytomedicine*, 14: 136-42.
Wong S, Wong MM, Seligmann O, Wagner H. 1988. Drugs for liver therapy part 16. Anthraquinone glycoside from seeds of *C. tora*. *Phytochemistry*, 28 (1): 211-214.