



RESEARCH ARTICLE

NON SURGICAL ENDODONTIC TREATMENT OF EXTRA ORAL SINUS: A CASE REPORT

*¹Dr. Ritu Meel, ²Dr. Neetu Meel and ³Dr. Pratibha Chaudhary

¹MDS (Department of Conservative Dentistry and Endodontics), Mahatma Gandhi Dental College and Hospital, Jaipur (Rajasthan)

²(Sr. Lecturer), Department of Orthodontics and Dentifacial Orthopaedics, Rajasthan Dental College & Hospital, Rajasthan University of Health Science, Jaipur (Rajasthan)

³Post Graduate (Department of Conservative Dentistry and Endodontics), Mahatma Gandhi Dental College and Hospital, Jaipur (Rajasthan)

ARTICLE INFO

Article History:

Received 13th February, 2017
Received in revised form
04th March, 2017
Accepted 09th April, 2017
Published online 23rd May, 2017

ABSTRACT

The present case report discusses diagnosis and treatment of an extraoral cutaneous sinus tract of odontogenic inception in cognation to a mandibular right Central incisor. Patient responded well and the cutaneous lesions rejuvenated uneventfully. In the absence of any clinical symptom complete obturation was done. Patient was kept on customary follow-up.

Key words:

Non-surgical endodontic treatment,
Extra oral sinus,
Mandibular Incisor.

Copyright©2017, Dr. Ritu Meel et al. This is an open access article distributed under the Creative Commons Attribution License, which permits unrestricted use, distribution, and reproduction in any medium, provided the original work is properly cited.

Citation: Dr. Ritu Meel, Dr. Neetu Meel and Dr. Pratibha Chaudhary. 2017. "Non surgical endodontic treatment of extra oral sinus: a case report", *International Journal of Current Research*, 9, (05), 50747-50749.

INTRODUCTION

The sinus tract described as a communication lead from an enclosed area of inflammation to an epithelial surface (Swales, K. L. et al., 2015). Odontogenic sinus tract is a distinctive but well- documented condition. Categorical dental symptoms are absent in such cases, patients first visit a physician for treatment (Abuabara, A. et al., 2012). Studies indicate that sinus tracts more frequently are found on the chin or submandibular region (John. et al., 2015). Hence, eighty percent of the cases are reported with mandibular teeth and twenty percent with maxillary teeth (Roland A Barrowman. et al., 2007).

Case Report

A 25 year old male who had earlier undergone unsuccessful medical treatment procedure thrice reported to Medical Hospital and was referred to the Department of Conservative Dentistry & Endodontics with chief complaint of Pain and swelling in lower anterior tooth region since 5 months. Past

dental history patient gives a history of pus discharge from chin region fever for which he was taking medication. That root canal therapy was performed on the tooth two year back. On extra oral examination there was soft fluctuant swelling tender on palpation with pus discharge in the chin region there was red edematous area surrounding the swelling (Figure1). Palpable submental lymph nodes. Clinical examination revealed discoloration presence of restoration and Grade I mobility irt 41(Figure 2). Intraoral periapical radiograph revealed an endodontically treated tooth with well-defined radiolucent lesion associated with the lower anterior central incisors (Figure3). Access cavity was reentered using a endo access bur. (Dentsply) .Coronal guttapercha was removed by Xylene and engaged with the help of H-files (Dentsply, Maileffer .Canal was irrigated with saline to flush the GP and sealer remnants. Working Length Determined With 15 K-Files (2%) (Figure 4). The canal were cleaned & shaped with protaper (Densply-Maileffer, Ballaigues, Switzerland), irrigated thoroughly with 5.25% sodium hypochlorite and 2% chlorhexidine Intra canal Medication Calcium Hydroxide Placed irt 41 with a Lentulospiral For 7 Days. Calcium Hydroxide dressing changed periodically every week up to 3 weeks. When the patient was asymptomatic with no discharge from the canals the tooth was obturated with gutta percha

*Corresponding author: Dr. Ritu Meel

MDS (Department of Conservative Dentistry and Endodontics), Mahatma Gandhi Dental College and Hospital, Jaipur (Rajasthan)

points. (Figure 5 and 6). Healing of extra oral sinus absence of swelling Patient was asymptomatic. He was unable to shave before but was comfortable in shaving after the treatment. Only a slight scar remained related to the sinus tract. (Figure7). Eighteen months later complete recuperation of the periapical lesion was observed on radiograph (Figure 8).

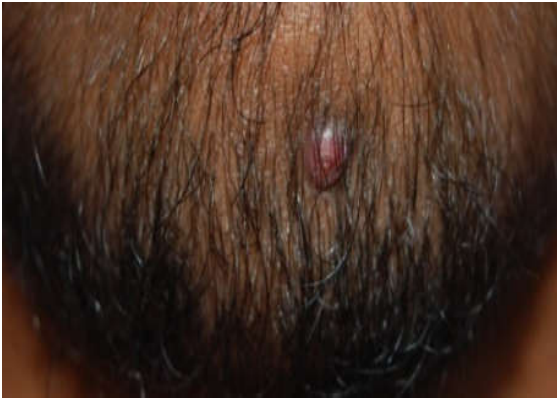

Figure 1. Pre-operative extraoral sinus tract

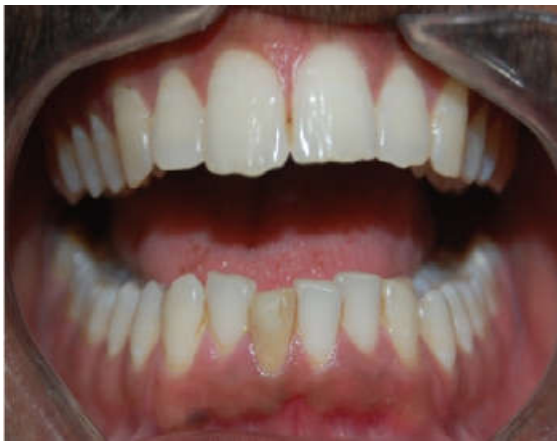

Figure 2. Intra-oral image

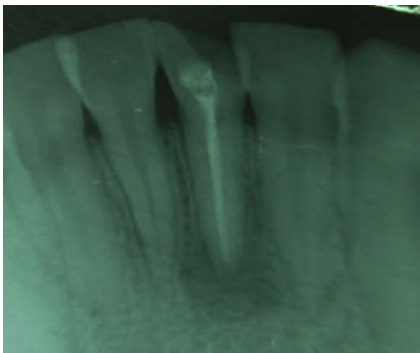


Figure 3. Preoperative intraoral periapical radiograph

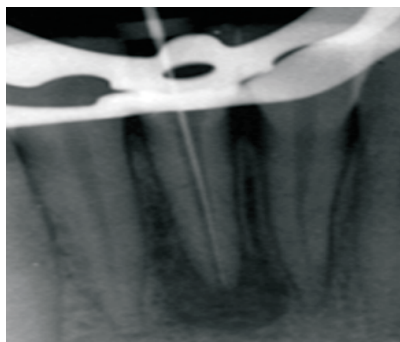


Figure 4. Working length Radiograph

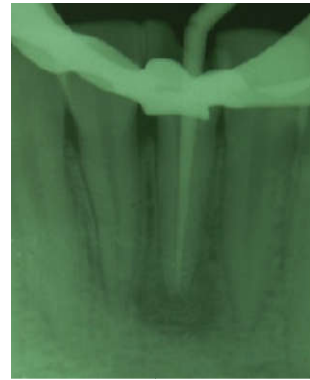

Figure 5. Master cone radiograph

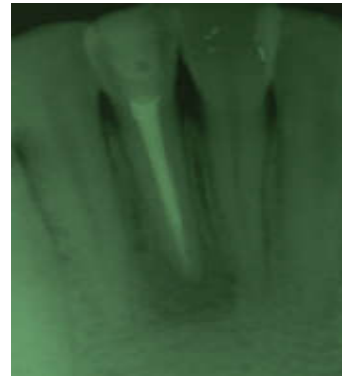


Figure 6. Postoperative radiographs

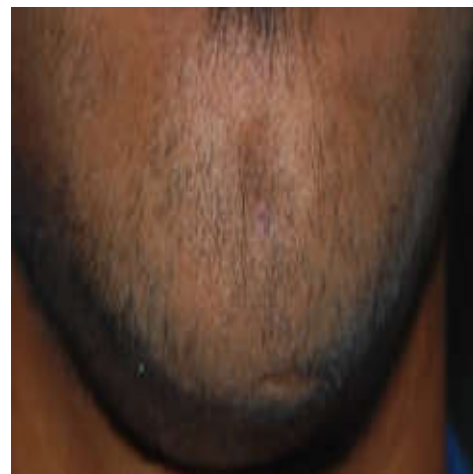


Figure 7. Complete heal of the sinus tract

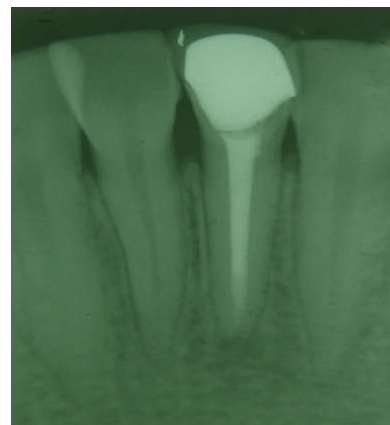


Figure 8. Eighteen months follow-up

DISCUSSION

The sinus tracts of dental origin have been reported previously. But, still present a diagnostic challenge to a clinician. Therefore misdiagnoses of sinus tract of dental origin by a physician often undergoing a couple of antibiotic regimens, more than one surgical excisions (Tian, J. *et al.*, 2015). The management of such lesions is to remove the infection. Traditional root canal therapy and sometimes tooth extraction and surgery are useful in disappear the sinus tract within two weeks (Kansa, R. 2013). The prosperity of the non-surgical endodontic treatment method is predicated on opportune cleaning, shaping, asepsis and filling of the root canal. It has been reported that the sterilization of the root canal and periradicular region results in good rejuvenating of periapical diseases (Gautam P. Badole. 2014). Coronal microleakage has been identified as another major cause of assiduous periradicular disease and failure in endodontic therapy (Brown, R. *et al.*, 2010). Along with disinfection, the adequate obturation of the root canal space ideally averts the emergence of endodontic disease and emboldens periapical rejuvenating when pathosis is present. This process can only prosper if the sealed root canal space obviates further ingress of bacteria, entombs remaining microorganisms and averts their survival by obstructing the nutrient supply (Sunandan Mittal. *et al.*, 2014). In the present case, only non-surgical endodontic therapy was carried out and the sinus tract was prosperously treated with minimal scar formation. Ca(OH)₂ Calcium hydroxide was utilized as an intracanal medicament in the present case due to its propitious effects

Conclusion

The Prosperous management of extraoral sinus tracts by means of pulpal necrosis relies upon felicitous diagnosis as well as elimination of the source of infection abstraction of etiological factors by congruous bio plus chemomechanical preparation and 3-dimensional obturation.

REFERENCES

- Abuabara, A., Schramm, C. A., Zielak, J. C., & Baratto-Filho, F. 2012. Dental infection simulating skin lesion. *Anais Brasileiros de Dermatologia*, 87(4), 619-621.
- Brown, R. 2010. Cutaneous sinus tracts (or emerging sinus tracts) of odontogenic origin: a report of 3 cases. *Clinical, Cosmetic and Investigational Dentistry*, 63.
- Gautam P. Badole, Rajesh Kubde, Dr. Mohit Gunwal & Dr. Shital G. Badole. 2014 Nonsurgical Management of Cutaneous Sinus Tract of Odontogenic Origin: A Case Report. *Global Journal of Medical Research: Dentistry and Otolaryngology*. Volume 14 Issue 4 Version 1.
- Gijo John, Tejal Singh., Ahtesham Aleem & Niyati Singh Thakur 2015. Non surgical endodontic treatment of cutaneous extraoral sinus tract. Report of 2 cases. *Asian Pacific Journal of Health Sciences*, 2(4S): 11-14.
- Kansal, R., Kaushik, A., Talwar, S., & Nawal, R. 2013. Non Surgical Management of Cutaneous Sinus Tract of Dental Origin: A Report of Three Cases. *Journal of Evolution of Medical and Dental Sciences*, 2(46), 9042-9047.
- Roland A Barrowman., Mehdi Rahimi., Mark D Evans., Arun Chandu. & Peter Parashos. 2007 Cutaneous sinus tracts of dental origin. *MJA*. Volume 186 Number 5.
- Sunandan Mittal, Tarun Kumar, Shifali Mittal, Jyotika Sharma. 2014 Management of Cutaneous Sinus Tract of Endodontic Origin: - Two Case Reports. *Journal of Nepal Dental Association - JNDA | Vol 14, No 2*.
- Swales, K. L. Rudralingam, M., & Gandhi, S. 2015. Extraoral cutaneous sinus tract of dental origin in the paediatric patient. A report of three cases and a review of the literature. *International Journal of Paediatric Dentistry*, 26(5), 391-400.
- Tian, J., Liang, G., Qi, W., & Jiang, H. 2015. Odontogenic cutaneous sinus tract associated with a mandibular second molar having a rare distolingual root: a case report. *Head & Face Medicine*, 11(1).
