



RESEARCH ARTICLE

SIGNIFICANCE OF ANTERIOR LOOP OF THE INFERIOR ALVEOLAR NERVE: A CBCT STUDY FOR IMPLANT PLANNING

^{*1}Dr. Saraswathi Gopal, K., ²Dr. J. K. Singh Kshatri and ³Dr. Mahesh Kumar, P.

HOD¹, Post graduate student², Reader³,

Dept of Oral Medicine and Radiology, Meenakshi Ammal Dental College and Hospital, Chennai, Tamilnadu, India

ARTICLE INFO

Article History:

Received 19th February, 2017
Received in revised form
21st March, 2017
Accepted 14th April, 2017
Published online 23rd May, 2017

ABSTRACT

The aim of the present study was to assess the presence and length of the anterior loop in the mental foramen region using CBCT. Both the right and left sides were retrospectively studied in 50 patients. Axial, sagittal, cross-sectional and panoramic images were evaluated and three-dimensional images were reconstructed and evaluated as necessary. The morphology, course and length of the anterior loop were measured. An anterior loop was found in about 25% of the scans. The mean anterior loop proximal edge was 3.24 mm.

Key words:

Cone Beam CT (CBCT), Anterior Loop,
Mandibular Canal, Retrospective Study,
Anatomy.

Copyright©2017, Dr. Saraswathi Gopal et al. This is an open access article distributed under the Creative Commons Attribution License, which permits unrestricted use, distribution, and reproduction in any medium, provided the original work is properly cited.

Citation: Dr. Saraswathi Gopal, K., Dr. J. K. Singh Kshatri and Dr. Mahesh Kumar, P. 2017. "Significance of anterior loop of the inferior alveolar nerve: A CBCT study for implant planning." *International Journal of Current Research*, 9, (05), 50884-50886.

INTRODUCTION

The inferior alveolar neurovascular bundle containing the inferior alveolar nerve is located in the mandibular canal of the lower jaw and leaves canal from the mental foramen in anterior wall of the premolar region of alveolar bone. The final portion of the inferior alveolar nerve sometimes passes below the inferior border and the anterior wall of the mental foramen and, after giving off a small incisive branch, it curves back to enter the foramen and emerge to the soft tissues becoming the mental nerve (Hakan Eren, 2016). This anatomical feature is also known as "anterior loop" of the inferior alveolar nerve. Correct placement of dental implants in the mental region may be limited by this anatomic structure and its violation can lead to a neurosensory disturbance in the area of the lower lip. Although it is a benign anatomical variation, its accurate identification is essential for surgical planning, particularly for dental implant placement, in order to prevent iatrogenic complications and to ensure the effectiveness of surgical procedures performed in this region (Eduarda Helena Leandro do Nascimento, 2016). Strikingly variable results regarding the prevalence of anterior loops of the inferior alveolar nerve have been reported in the literature, ranging from 22%-28%, 6 to 88%, and a maximum length of 11 mm has been reported.

Usually the panoramic radiography (PR), together with the clinical examination has been used as the only preoperative diagnostic tool in treatment planning of implant placement in interforaminal region (Sakhdari, 2016). Even though the magnification shown by PR is small in the anterior region, the distortion and the magnification of the anatomical structures is often present, and results in either over or underestimation of the real size (Aleksandar Vujanovic-Eskenazi, 2015). Other diagnostic techniques such as intraoral periapical radiographs and CT do not allow exact measurements nevertheless CT provides more reliable data and can be used to obtain detailed information using a three dimensional analysis. A new possibility for improved diagnostic imaging is the Cone Beam Computed Tomography (CBCT). The images obtained when performing CBCT are similar to those found on CT. CBCT is an advanced digital imaging technique that allows to generate multiplanar slices of a region of interest and is capable to reconstruct a 3D image using a cone-shaped rotating x-ray beam via a series of mathematical algorithms. Currently it is being increasingly used based on the good relation cost effectiveness, shorter time of acquisition, high power resolution and 1/15 less radiation exposure compared to CT (Jacobs *et al.*, 2005). Studies focusing on checking the accuracy of the measurements taken by CT and CBCT on patients versus those taken in cadavers, CBCT showed the lowest magnification and there is no significant difference in image magnification depending on tooth location either vertical or mesio-distal

*Corresponding author: Dr. Saraswathi Gopal. K

HOD, Dept of Oral Medicine and Radiology, Meenakshi Ammal Dental College and Hospital, Chennai, Tamilnadu, India.

dimension (Mardinger *et al.*, 2000). Also it is possible to determine a relative quality of bone, select a smaller field of view and have the possibility to manufacture a CBCT-surgical guide with the aid of a software package, all as an in-office modality. There is a Consensus Report about the use of CBCT in implant dentistry with the intent of providing a scientifically based guidance to clinicians regarding its use as an adjunct to traditional imaging modalities. Hence we planned to do a study on CBCT related analysis of IAN and its looping at mental foramen (Wismeijer, 1997). The aim of the present study was to assess the presence and length of the anterior loop in the mental foramen region using CBCT (Ngeow Wei Cheong, 2009).

Objectives

- To assess the presence of anterior loop
- To assess the length of anterior loop
- To compare the presence of anterior loop in males and females
- To compare the presence of anterior loop in right and left side of mandible.

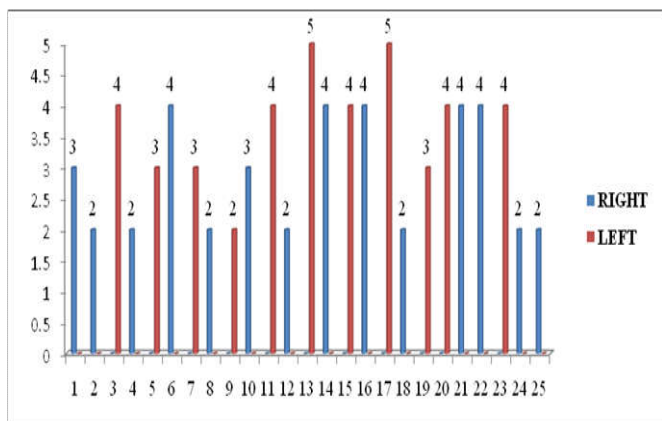
MATERIALS AND METHODS

The study cohort comprised 50 images of mandibles [100 hemi mandibles] were retrospectively evaluated. CBCT images were included if they were of adequate diagnostic quality, without fractures and/or bone disease that compromised the region of the mental foramen. The exclusion criterion was the presence of implants or metal artifacts located in the foramen region. CBCT scans were obtained using a Planmeca Promax 3D mid proface unit. Despite the fact that recent studies have indicated that small variations in head position do not influence measurement accuracy using three-dimensional CBCT, each CBCT scan obtained in our clinics undergoes a strict, standardized scanning protocols.

All CBCT images were retrospectively evaluated by 2 dento maxillofacial radiologist using CBCT device Romexis software. Axial, sagittal, cross-sectional and panoramic images were reconstructed for all mandibles and three-dimensional reconstructions were used as necessary. The presence of anterior looping and its length were measured.

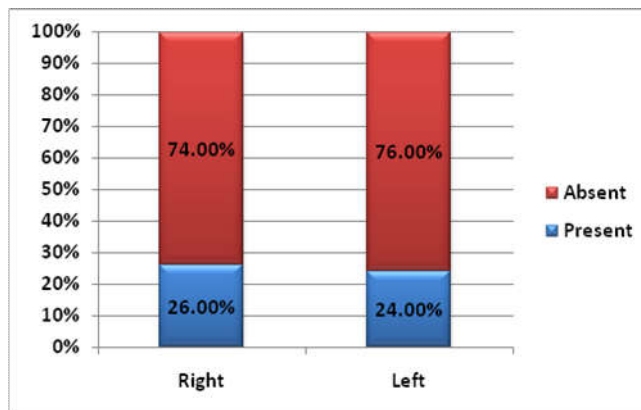
RESULTS

ANTERIOR LOOP was identified in 25% of the cases and the mean length was 3.24 mm (Graph 1).

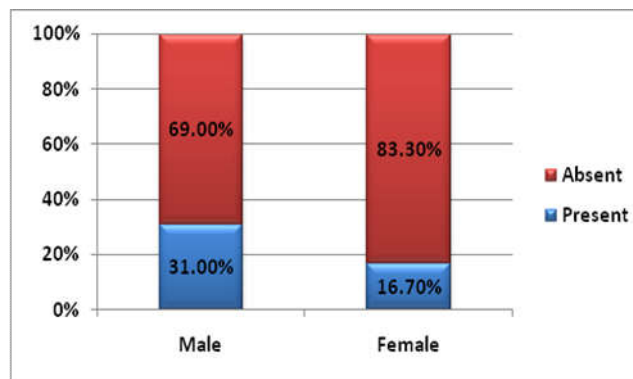


Graph 1: Presence of anterior looping in 25 sides (out of 100 sides)

The side that demonstrated maximum anterior looping was right side with 26% and left side with 24% (Graph 2). There was a male predilection observed predominantly. Out of 100 sides evaluated, anterior looping was present 31% in males, 16.7% in females (Graph 3)



Graph 2. Percentage of anteriorloop of inferior alveolar nerve with respect to side



Graph 3. Percentage of anterior loop of inferior alveolar nerve according to Gender

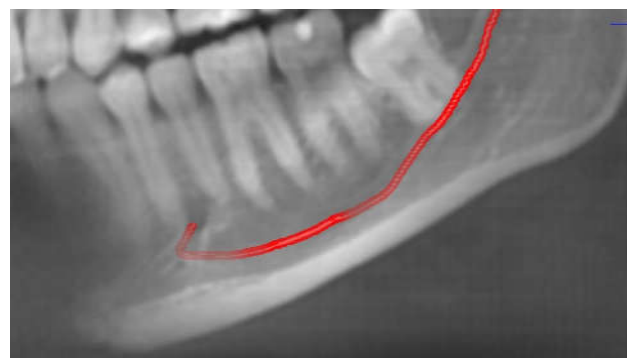


Figure 1. Showing the anterior loop of the mandibular nerve before exiting in to the mental foramen

DISCUSSION

The study of the anterior loop of the mandibular canal is a relatively new area of research, and most studies have been conducted in the last few years. The increased interest in the subject is directly related to the greater frequency of operations for the placement of dental implants. Several methods have been used to assess this type of anatomical variations, including panoramic radiography, CT, CBCT, anatomical measurements, and other related methods.

Our study showed that the anterior loop of the mandibular canal was present in 25% of all cases. The mean length of the anterior loops found in our study was 3.24 mm, a value close to those that have been reported in the literature (Couto-Filho, 2015). The largest anterior loop observed was 5 mm. Despite being clinically relevant in extent, this length was far lower than the maximum lengths of 9 mm reported by Uchida *et al* (2007) and 11 mm reported by Neiva *et al* (2004). Moreover, our research demonstrated that in most of cases, the length of the anterior loop was less than 4mm, similarly to the findings of Apostolakis (2012) and Brown and Filo *et al* (2014). that approximately 95% of cases showed lengths of up to 3 mm. We found that the anterior loop was longer on the left side and most common on the right side. Some authors, however, have found no significant relationships between these variables (gender, and side) and length or prevalence of anterior loops (AleksandarVujanovic-Eskenazi, 2015).

Although anatomical studies on cadavers provide important and accurate information about the prevalence and variation in length of the anterior loop, CT is the method that actually corresponds to clinical practice and adequately satisfies pre-surgical planning requirements. Furthermore, CT images have been proven to exhibit high precision and reliability in the diagnosis of the anterior loop and other anatomical landmarks in the mandible. As previously stated CT images are very effective exams for the diagnosis of anterior loops of the mandibular canal and can be used with great reliability to identify their presence and measure their length (Chun, 2015). However CBCT is preferable and is most often used in dental practice due to its advantages including a lower cost and a low radiation dose, in combination with the fact that CBCT image quality is comparable or even superior to that of multislice CT for evaluating dent maxillofacial structures (Leepong, 2014).

Conclusion

Clinicians should be careful during implant or minor surgical procedures in the mandibular premolar region to avoid possible complications resulting from damage of the nerve. For this purpose it is suitable to use the CBCT imaging method for implant planning to correctly identify the course of the mandibular nerve and accurately view the anatomical structures. Further studies are needed in order to obtain more reliable results and verifications.

REFERENCES

Aleksandar Vujanovic-Eskenazi *et al*. A retrospective radiographic evaluation of the anterior loop of the mental nerve: Comparison between panoramic radiography and cone beam computerized tomography, *Med Oral Patol Oral Cir Buccal.*, 2015 Mar; 20(2) :e239-e245

Aleksandar Vujanovic-Eskenazi *et al*. 2015. A retrospective radiographic evaluation of the anterior loop of the mental nerve: Comparison between panoramic radiography and cone beam computerized tomography, *Med Oral Patol Oral Cir Buccal.* Mar 1;20 (2):e239-45.

Chun-I Lu *et al*. 2015. Assessment of the Anterior Loop of the Mental Nerve Using Cone Beam Computerized Tomography Scan, *J Oral Implantol.* Dec;41(6):632-9.

Couto-Filho *et al*. 2015. Accuracy in the Diagnosis of the Mental Nerve Loop, A Comparative Study Between Panoramic Radiography and Cone Beam Computed Tomography, *Int. J. Morphol.*, 33(1):327-332.

Eduarda Helena Leandro do Nascimento *et al*, Assessment of the anterior loop of the mandibular canal: A study using cone-beam computed tomography, *Imaging Science in Dentistry* 2016; 46: 69-75

Hakan Eren *et al*. 2016. Cone beam computed tomography evaluation of mandibular canal anterior loop morphology and volume in a group of Turkish patients, *biotechnology & biotechnological equipment*, Vol. 30, NO. 2, 346-353

Jacobs, R., Mraiwa, N., Van Steenberghe, D. *et al*. 2004. Quirynen M. Appearance of the mandibular incisive canal on panoramic radiographs. *Surg Radiol Anatomy*, 26:329-333.

Leepong, N. *et al*. 2014. A comparison in size of mental foramen and anterior loop length of mental nerve between dentate and non-dentate jaw using CBCT, | *Clin. Oral Impl. Res.*, (Suppl. 10).

Mardinger, O., Chaushu, G., Arensburg, B., Taicher, S., Kaffe, I. 2000. Anterior loop of the mental canal: an anatomical-radiologic study. *Implant Dent*; 9:120-5.

Ngeow Wei Cheong *et al*. 2009. A radiographic study on the visualization of the anterior loop in dentate subjects of different age groups, *J Oral Sci* 51, 231-237

Sakhdari, S. *et al*. 2016. Prevalence of the inferior alveolar nerve's anterior loop and mandibular incisive canal by use of Cone Beam Computed Tomography (CBCT) in an Iranian population, *Journal of Research in Dental and Maxillofacial Sciences*, Vol 1, No 3, Summer.

Wismeijer, D., van Waas, M.A., Vermeeren, J.I., Kalk, W. 1997. at nts' r pt on of S nsory Disturbances of the Mental Nerve Before and After Implant Surgery: A Prospective Study of 110 patients. *British Journal of Oral Maxillofac Surgery*; 35:254-9.
