



CASE REPORT

REHABILITATION OF ATROPHIC MAXILLA WITH A HOLLOW MAXILLARY COMPLETE DENTURE

*¹Dr. Sanjay B Lagdive, ²Dr. Rupal J Shah, ³Dr. Dharmendra Sindha and ⁴Dr. Satyaprakash Shah

¹Professor, Dept. of Prosthodontics, Govt. Dental College and Hospital, Ahmedabad

²Professor and head, Dept. of Prosthodontics, Govt. Dental College and Hospital, Ahmedabad

^{3,4}Post graduate, Dept. of Prosthodontics, Govt. Dental College and Hospital, Ahmedabad

ARTICLE INFO

Article History:

Received 09th August, 2017

Received in revised form

04th September, 2017

Accepted 21st October, 2017

Published online 30th November, 2017

Key words:

Hollow maxillary denture,
Severely resorbed ridge,
Increased inter arch space,
Residual ridge resorption,
Double flask technique.

ABSTRACT

Objective: To fabricate a hollow maxillary complete denture in a patient with severely resorbed ridge and greater inter-arch space.

Background: Bulky prosthesis affects peripheral seal and causes poor retention of denture.

Material and Method: A hollow cavity was fabricated in the "rim" part of complete denture using two flask technique.

Result: Retention and stability lost due to heavy weight of denture was regained.

Conclusion: This case report describes a predictable technique to fabricate lightweight denture.

Copyright ©2017, Dr. Sanjay B Lagdive et al. This is an open access article distributed under the Creative Commons Attribution License, which permits unrestricted use, distribution, and reproduction in any medium, provided the original work is properly cited.

Citation: Dr. Sanjay B Lagdive, Dr. Rupal J Shah, Dr. Dharmendra Sindha and Dr. Satyaprakash Shah, 2017. "Rehabilitation of atrophic maxilla with a hollow maxillary complete denture- A case report", *International Journal of Current Research*, 9, (11), 60448-60451.

INTRODUCTION

Residual ridge resorption is a progressive and inevitable sequelae of prolonged edentulousness. Severely resorbed ridges further complicate prosthesis fabrication due to convoluted rehabilitating clinical presentations, namely minimal bone height, unfavourable residual ridge morphology, and/or unfavourable muscle attachments. Atrophic ridge along with increased inter-occlusal space mandates an increased volume of tissues to be rehabilitated adding to the bulk of prosthesis. Criticism arose that extra weight of denture may in fact cause accelerated resorption of the residual ridges (Brenon, 1973). Thus being a complex oral condition, ridge size reduction needs to be dealt with specialized prevention and treatment. A maxillary denture in atrophic maxillary arch with greater interocclusal distance, frequently loses its peripheral seal by virtue of its weight (Fattore, 1988). Ohkubo and Hosoi stated that retention or stability could be obtained by improving the fit of denture base. In an obturator, fabricated for the restoration of a large maxillofacial defect, hollowing to reduce the weight of a maxillary prosthesis, however, has shown to have beneficial effects. Holt *et al.* processed a shim of indexed acrylic resin and used auto polymerized acrylic resin

to lute the two parts together. Fattore *et al.* used a variation of the double flask technique for obturator fabrication. O'Sullivan *et al.* described a modified method using a clear matrix of the trial denture base and silicone putty as spacer which was later retrieved through holes.

Case Report

In this entailed case report, a 60 year old edentulous male patient reported to department of prosthodontics with chief complaint of dentures with poor retention. Examination revealed severely atrophied maxillary ridge (ACP class IV) (McGarry, 1999), increased inter-ridge distance and heavy denture with poor retention. After authentication and approval from the ethical committee, and having undertaken a prior informed written consent from the patient, it was decided to treat him with a hollow maxillary denture, using double flask technique described by Chalian and Barnett with a modification by hollowing only the alveolar bulk of denture base material and fabricating teeth bearing section palateless, thus further reducing weight to improve the retention of denture.

Procedure

- All the steps of conventional complete denture fabrication were followed till the wax elimination stage.

*Corresponding author: Dr. Sanjay B Lagdive,

Professor, Dept. of Prosthodontics, Govt. Dental College and Hospital, Ahmedabad

Two identical varsity flasks were selected and marked "A" and "B" for easy identification and their cope and drag part A₁,B₁ and A₂,B₂ respectively. A double layer (1.2 × 2 = 2.4 mm) of modelling wax (Y-Dent, MDM corp., Delhi) of uniform thickness was adapted over the master cast conforming to the border extensions in the part A₂. Molten wax was often added to conform the roundness of border as per requirement. cold water was used during manipulation to avoid changes in thickness of wax (Fig.1).

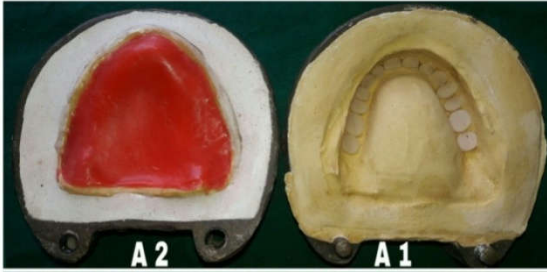


Figure 1 A. Baseplate wax adapted to the master cast for fabrication of permanent denture base. B. Wax shim over cast has been boiled out and cope part of identical flask used as counterpart

- An empty cope part B₁ was then kept over it and dental stone was poured after applying liquid separating media (Acralyn-H, Asian acrylates, Mumbai). Dewaxing was done (Fig. 2).

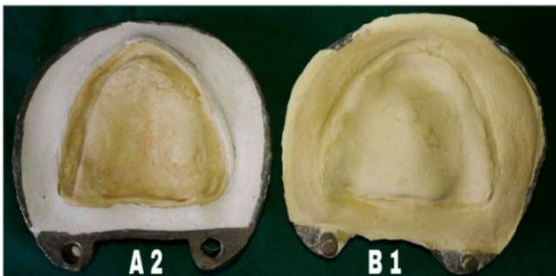


Figure 2 A. Processed heat cure denture base placed on master cast and wax shim was adapted to the denture section having teeth. B. Permanent denture base indexed, notches and groove marked and margin of wax shim adapted to indexes after repeated flask closure

- Heat cure resin (MELIODENT, Heraeus kulzer, mitsui chemicals group) was packed in flask containing denture base portion due to its high translucency.
- After curing permanent denture base was retrieved, excess flash is trimmed off. Another wax shim was adapted on the teeth portion in the cope part A₁ to correspond to the cameo surface of the denture (Fig. 3).

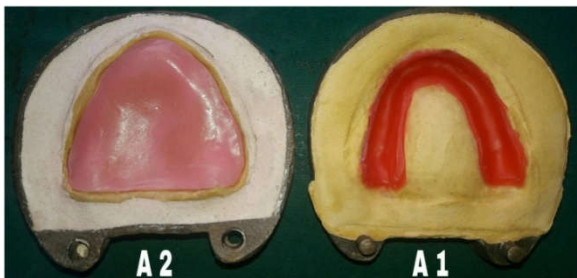


Figure 3 A. Wax shim has been boiled out, flask has been separated and drag part of identical flask used as counterpart B. Processed acrylic resin shims to be fused by adapting a rope of heat cured acrylic resin around the borders

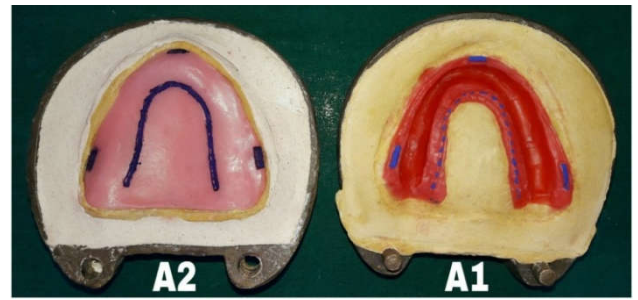


Figure 4. Intaglio surface of complete denture, hollow space of maxillary denture filled with povidone iodine solution demarcates the hollow portion

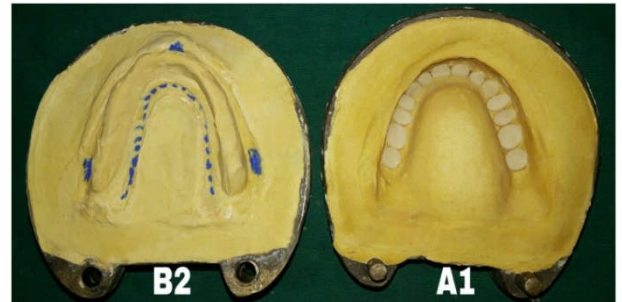


Figure 5. Brilliant transillumination of hollow denture in dark

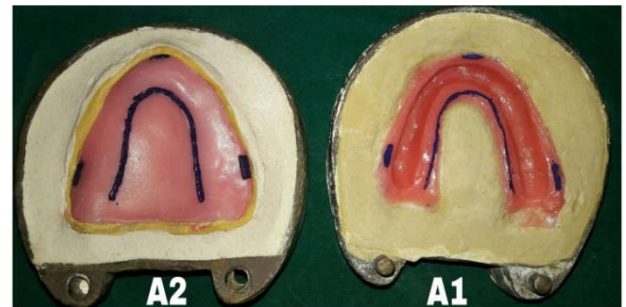


Figure 6. Floating denture ensuring complete seal and a hollow cavity within

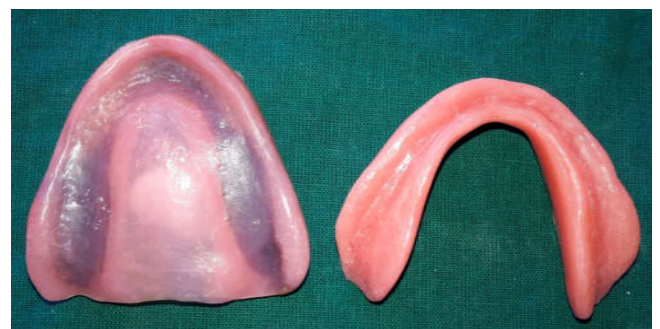

Figure 7. Intaglio surface of complete denture, hollow space of maxillary denture filled with povidone iodine solution demarcates the hollow portion

- Wax was not adapted over palatal part. Inner border of wax shim (on palatal side) became confluent with palatal portion of permanent denture base when two parts of originally same flask "A" are pressed together repeatedly.
- For a better indexing and accurate fit a "U" continuous groove of approx 1 mm x 1mm depth was made on palatal part where wax shim merges to it. Notches of dimension approx 6mm x 3mm x 2mm were made

bilaterally on buccal side and labially in centre on the pre- identified thickened peripheral areas of denture base. These indexes were marked for better differentiation (Fig. 4).

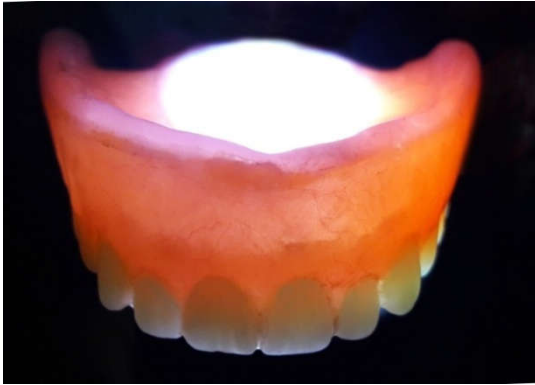

Figure 8. Brilliant trans-illumination of hollow denture in dark

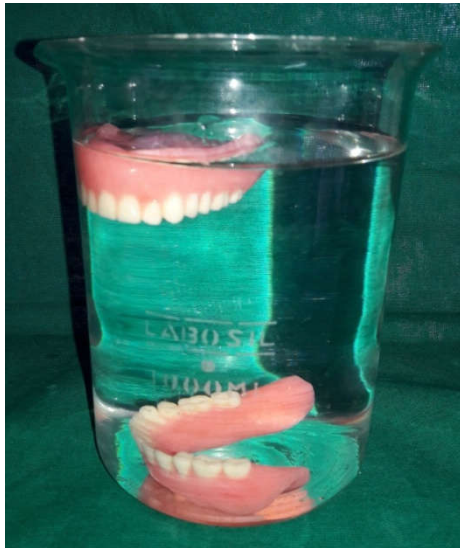

Figure 9. Floating denture ensuring complete seal and a hollow cavity within

- Permanent denture base was placed over master cast and the halves of the original flask were pressed together with a plastic sheet between them. Excess wax was removed to permit the flask to close completely. Repeated closing of original flask lead to formation of counter shapes on wax margin fitting snugly with a butt joint. Color marks were transferred to wax shim.
- Part B₂ was kept over the adapted wax shim in cope part A₁ and type 3 dental stone was vacuum mixed and poured in it in a very thin consistency and under continuous vibration. Dewaxing was done (Fig. 5).
- Packing was done using heat cure acrylic resin (ASHWIN-HS, Deccan dental depot, Hyderabad) in usual manner and processed.
- After curing both halves of originally same flask "A" contained a processed acrylic resin shell. Any acrylic resin tags that interfered with complete flask closure were removed using a sharp blade. Indices in both processed portions ensured proper positioning and a snug fit (Fig. 6).
- A "rope" of doughy, heat-cure, high-impact acrylic resin was made of thickness that of shim and adapted around the border of the cured acrylic resin of the tooth

side of the flask. A plastic sheet was used to trial pack, flash was trimmed and packing was continued until no flash was evident.

- The new acrylic resin was wetted slightly with monomer. The flask was closed and processed with a long-curing cycle. It was Cooled slowly and deflasked carefully. Cooling too quickly will cause more distortion than with a conventional denture.
- Polishing and finishing was done in usual manner. Denture was lab remounted on articulator and necessary occlusal adjustments were done.
- Povidone iodine was injected in the hollow cavity(Fig. 7) to get the exact volume (6ml) of space created in the prosthesis through a small hole. It was removed later by rinsing and vigorous shaking and hole was plugged.
- Verification of the sealed cavity was done by immersing the denture in water. If no bubbles are evident, an adequate seal is confirmed (Fig. 9).
- Denture was inserted and instructions regarding handling of the denture were given to the patient as the dentures are prone to fracture.

DISCUSSION

Despite of better available treatment modalities like implant supported overdenture and ridge augmentation procedures for a patient with severely resorbed ridges and long lip length; conventional complete denture continues to be a more better choice of rehabilitation due to economic constraints, systemic conditions, unwillingness for invasive surgical procedure, reluctance for a lengthy treatment procedure etc. Hollowing of the denture base, especially the alveolar portion reduces the prosthesis weight formed by an otherwise extensive volume of denture base material in large restorative spaces. It improves the cantilever mechanics of suspension and reduces overloading of remaining supporting structures. Holt *et al*'s technique of luting two processed parts of prosthesis using autopolymerized acrylic resin creates a long junction exposed in oral cavity. It leads to discoloration and increased risk of seepage of fluid into the denture cavity. Furthermore, this junction is a common site for post-insertion adjustment increasing the risk of leakage. It was also difficult to gauge resin thickness in the cope area. The procedure described in this article overcomes these inherent flaws. Heat-polymerizing one portion of the denture against the polymerized resin may reduce leakage at the junction of the two portions of the denture.

O'Sullivan's technique was useful in estimation of the spacer thickness, but removal of putty was found to be difficult especially from the anterior portion of the denture. Salt loss technique though provides easy hollowing due to high solubility of salt, but is uncertain about resin dimensions, control of salt flow under pressure during flask closure and pressing. Cavity formed by this double flask technique ensures a controlled weight reduction and adequate dimensions of acrylic resin for structural integrity of prosthesis (Mazaro, 2011). Taking inputs from the old techniques following minor modification was incorporated in laboratory steps of making hollow dentures. The section in cope part of the flask was fabricated palateless by not adapting wax shim on the palatal aspect, which further reduces the weight of the prosthesis and appropriate thickness in palate part improving the speech intelligibility. However, hollow denture is prone to fracture and requires more time to fabricate. This technique can be also

employed to fabricate salivary reservoir in patients with xerostomia.

Conclusion

Two flask technique for fabrication of hollow maxillary denture is described to reduce the weight of heavy maxillary complete denture in cases with severe ridge resorption and greater inter arch space. Hollowing of maxillary denture thus prevents residual ridge resorption, compensates and improves the retention lost due to virtue of its heavy weight.

REFERENCES

Brenon, E.F. 1973. Adding weight may promote retention of lower denture. *Dent Surv.*, 49(3):30.

Brown, K.E. 1969. Fabrication of hollow-bulb obturator. *J Prosthet Dent.*, 21(1); 97-103.

Fattore, L.D., Fine, L., Edmonds, D.C. 1988. The hollow denture: an alternative treatment for atrophic maxillae. *J Prosthet Dent.*, 59:514-516.

Mazaro, J.V., Gennari Filho, H., Vedovatto, E., Amoroso, A.P., Pellizzer, E.P., Zavanelli, A. 2011. Cinfluence of different base thicknesses on maxillary complete denture processing: linear and angular graphic analysis on the movement of artificial teeth. *J Craniofac Surg. Sep*; 22(5):1661-1665.

McGarry, T.J., Nimmo, A., Skiba, J.F., Ahlstrom, R.H., Smith, C.R., Koumjian, J.H. Classification system for complete edentulism. The American College of Prosthodontics. *J Prosthodont.*, 8: 27-39.
