



RESEARCH ARTICLE

BRUCELLA CAUSING SEPTIC ARTHRITIS IN THE SHOULDER: A CASE REPORT

\*<sup>1</sup>Alshareef, Hatim Mohammed A. and <sup>2</sup>Al Hasan, Ahmed Hassan A.

<sup>1</sup>Orthopedic Department, King Fahad Armed Forces Hospital, Jeddah, KSA

<sup>2</sup>College of Medicine, University of Jeddah, Jeddah, KSA

ARTICLE INFO

Article History:

Received 04<sup>th</sup> May, 2017  
Received in revised form  
29<sup>th</sup> June, 2017  
Accepted 20<sup>th</sup> July, 2017  
Published online 31<sup>st</sup> August, 2017

Key Words:

Brucellosis,  
Shoulder infection,  
Arthritis.

ABSTRACT

**Background:** Brucellosis is a zoonotic disease caused by a Gram negative rod named after Bruce in 1887. It is a zoonosis of worldwide distribution. In Saudi Arabia, the prevalence is high and is attributed to widespread animal husbandry and to the traditional drinking of raw milk. Shoulder brucellosis commonly seen in old population. We have recently treated an old patient diagnosed with brucellosis, who was seen with clinical, radioisotopic, microbiologic, and surgical evidence of shoulder septic arthritis, a rare site of Brucella involvement.

**Case presentation:** A 75 year old male presented with history of fever for the past 10 days with associated right shoulder pain. He was admitted under internal medicine for further investigations for fever of unknown origin. Right shoulder pain was described as generalized dull ache of with gradual onset. Patient Denied any contact with any sheep, animal urine or dairy products, there was no obvious source of ongoing infection and no history of recent trauma. Patient was admitted, orthopedic department was consulted to assess the right shoulder after 24 hour from admission. MRI done which showed joint effusion suggestive of intraarticular collection in support of infective process. Patient was scheduled for Incision and drainage on the same day. Culture was taken intra operative and was sent for microbiology assessment. Wash out was done and a drain was placed and antibiotic started. Infectious disease was then consulted as the patient didn't improve and they advised to do a full septic screen. Brucella titre was positive for Brucella Melitensis 1:80 and Brucella Abortus Agglutinins 1:160. Patient started on doxycycline 100mg PO BID for 12 weeks and streptomycin 1g IM OD for 3 weeks. Two weeks later patient was seen on a follow up appointment at OPD, had no complaints, wound was clean and range of motion of the left shoulder had improved Serial follow up in clinic also showed no recurrent episodes of shoulder pain and there was no active issues and the patient was discharged from the orthopedic service.

**Conclusion:** Musculoskeletal brucellosis is endemic in areas such as Saudi Arabia. Shoulder considered to be a rare site of involvement. Brucellosis should be considered in the line of differential diagnosis, especially in older patients with shoulder arthritis. Early recognition and adequate treatment reduce the suffering of the patients as well as the frequency of relapses.

Copyright©2017, Alshareef, Hatim Mohammed and Al Hasan, Ahmed Hassan. This is an open access article distributed under the Creative Commons Attribution License, which permits unrestricted use, distribution, and reproduction in any medium, provided the original work is properly cited.

Citation: Alshareef, Hatim Mohammed, A. and Al Hasan, Ahmed Hassan, A. 2017. "Brucella Causing Septic Arthritis In The Shoulder: A Case Report", International Journal of Current Research, 9, (08), 55897-55900.

INTRODUCTION

Brucellosis is still a major health problem in many geographical areas including the Mediterranean and Middle East regions. Brucellosis is a zoonotic disease caused by a Gram negative rod named after Bruce in 1887. It is a zoonosis of worldwide distribution. In Saudi Arabia, the prevalence is high and is attributed to widespread animal husbandry and to the traditional drinking of raw milk. (Madkour *et al.*, 1985) Human brucellosis may be caused by one offour species: Brucella abortus, B suis, B canis,

And B melitensis, the last being the most virulent and the most invasive. (Salata *et al.*, 1985) Brucellosis is a disease presented either as generalized febrile illness, without affection of organ systems, or as a focal disease, when one or more organs are involved. (Bosilkovski and Rodriguez-Morales, 2014) Osteoarticular brucellosis is the commonest focal form, with a frequency of 19–69 % of the total number of brucellosis patients. (Aygen *et al.*, 2002; Geyik *et al.*, 2002) According to some studies, the most common is sacroiliitis. (Gotuzzo *et al.*, 1982; Tasova *et al.*, 1999; El-Desouki, 1991) In literature review of previous studies done they found that Patients with shoulder arthritis were the oldest. In the series of pediatric articular brucellosis, patients with shoulder arthritis are rarely found (Turan *et al.*, 2011; Benjamin and Khan, 1994) or there

\*Corresponding author: Alshareef, Hatim Mohammed, A.  
Orthopedic Department, King Fahad armed forces hospital, Jeddah, KSA.

are none (Shalaan *et al.*, 2002; Sharda and Lubani, 1986) We have recently treated a patient diagnosed with brucellosis, who was seen with clinical, radioisotopic, microbiologic, and surgical evidence of shoulder septic arthritis, a rare site of Brucella involvement.

### Case Report

A 75 year old male known hypertensive on regular medications otherwise well. Had presented with history of fever for the past 10 days with associated right shoulder pain. He was admitted under internal medicine for further investigations for fever of unknown origin. Right shoulder pain was described as generalized dull ache, with gradual onset, with no radiation. Pain gets worse with range of motion and improves with rest. The patient denied any contact with any sheep, animal urine or dairy products, there was no obvious source of ongoing infection and no history of recent trauma. On examination, Patient is generally in good condition, alert, oriented, BP 124/69mmHg, HR 82 bpm, RR 19 breaths per minute, Temp 38.3.C there was no documented enlarged lymph nodes, Chest was clear, equal air entry bilaterally and abdomen is soft non tender, with no organomegaly. Shoulder had no obvious swelling and no erythema, range of motion was extremely limited due to pain with little active movement and having only 40 degree passive Abduction and 30 degree passive internal and external rotation.

### Investigation:

WBC 5.9, CRP 113, ESR 95, Albumin 32, Hb 13.8 , CK 238

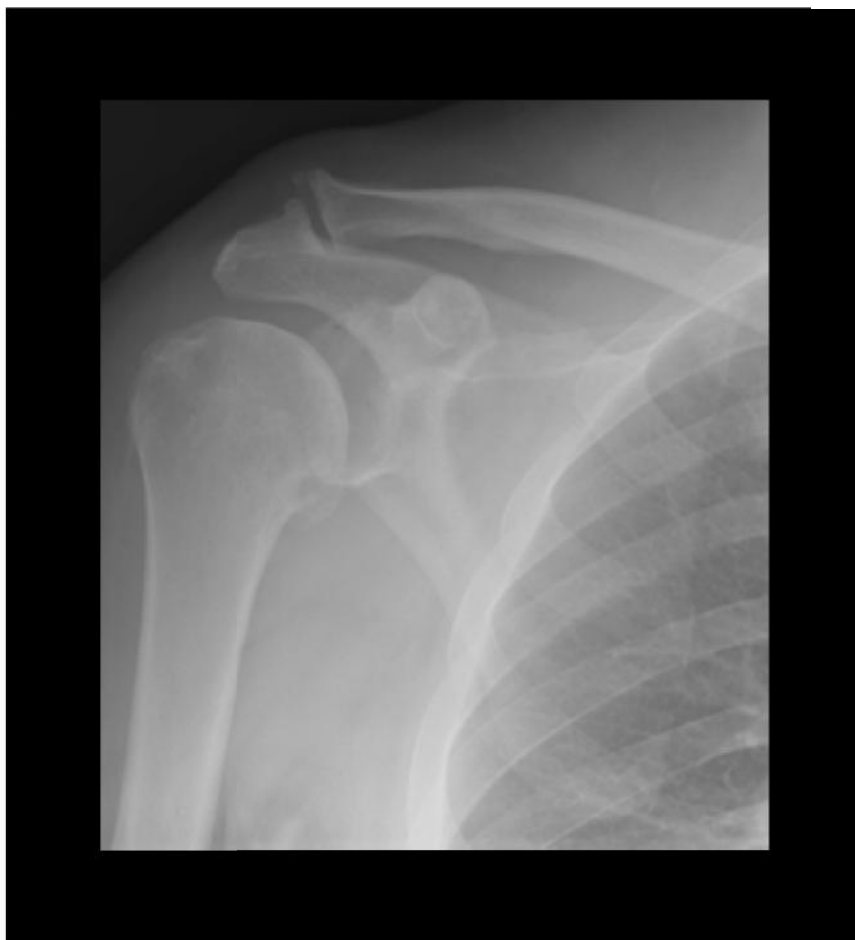### Hospital course and intervention:

Orthopedic department was consulted to assess the right shoulder after 24 hour from admission. Initial assessment was suspicious of septic arthritis. We advised an MRI and this is what we found:

Patient was scheduled for Incision and drainage on the same day, with a sub acromial lateral deltoid splitting approach, intra-op findings were intra articular pus collection, incidentally we also found that the patient had complete tear of supraspinatus tendon. Culture was taken intra operative and was sent for microbiology assessment. Wash out was done and a drain was placed.

He was started on cefuroxime 1.5g IV Q8h.

Post-op, he had persistent spikes of fever 38.7.C, drain had 20 cc turbid discharge. Intra operative culture showed no growth over 48 hours. Infectious disease was then consulted and advised to do a full septic screen, serology Hep B, Hep C and HIV, Brucella antibody titre, AFB, and microbacterial culture.



**Fig. 1. x ray of right shoulder shows degenerative changes and widening of sub acromion space indicate of possible intraarticular collection**

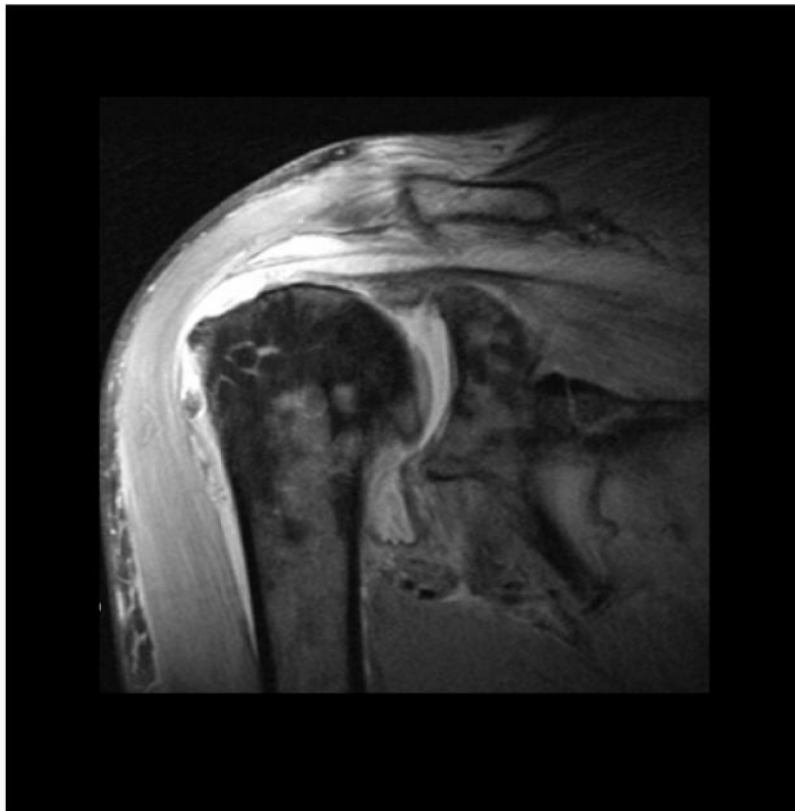


Fig. 2. MRI Gadolinium coronal cut shows moderate joint effusion with thick synovial enhancement suggestive infectious process

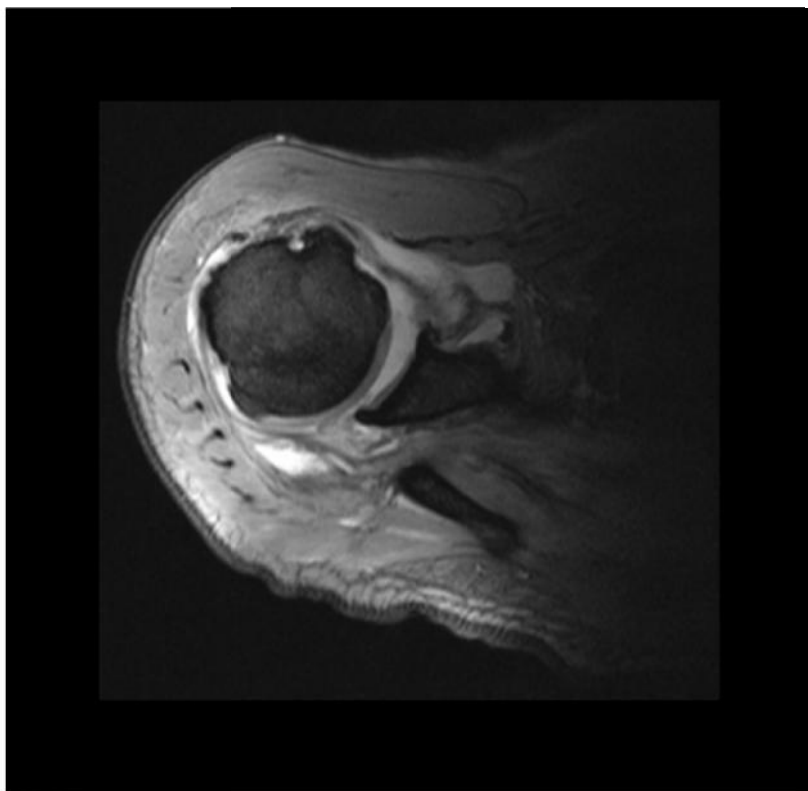


Fig. 3. MRI Gadolinium axial cut shows similar joint effusion which is also suggestive of intraarticular collection in support of infective process

**Table 1. Inflammatory marker changes throughout the admission and follow up period**

Days	CRP	ESR	WBC
Zero	113	95	5.9
Day 1 post op (1 <sup>st</sup> washout)	157.4	105	4.9
Day 3 post op	149.5	113	8
Day 1 post op (2 <sup>nd</sup> washout)	208.3	119	4.4
Day 3 post op (2 <sup>nd</sup> washout)	138.4	-----	5.4
Day 5 post op (2 <sup>nd</sup> washout)	83.9	35	-----
Day 10 post op (2 <sup>nd</sup> washout)	6.5	21	4.8
6 weeks post op (2 <sup>nd</sup> washout)	0.7	17	5

Cefuroxime was stopped and Ceftriaxone 1g IV OD + Vancomycin 1g IV Q12h was started. After 3 days, the patient continued to have persistent spiking temperature and a decision was made to go in and have a second wash out. After the second wash out there was no persistent spiking temperature. Brucella titre was positive for Brucella Melitensis1:80 and Brucella Abortus Agglutinins 1:160. It was recommended by the infectious disease team to start the patient on doxycycline 100mg PO BID for 12 weeks and streptomycin 1g IM OD for 3 weeks. He had no episodes of spiking temperature and inflammatory markers started trending down. Patient was discharged after completing 3 weeks of streptomycin and continued to take doxycycline for a total of 12 weeks. Two weeks later patient was seen on a follow up appointment at OPD. Patient had no complaints, he was afebrile, Wound was clean, no discharge, Range of motion of the left shoulder had improved with no painful arc. Serial follow up in clinic also showed no recurrent episodes of shoulder pain or symptoms of infection. After 1 year follow up the patient was seen and clinically assessed, there were no active issues and the patient was discharged from the orthopedic service.

## DISCUSSION

Brucellosis is a zoonosis of worldwide distribution. In Saudi Arabia, the prevalence is high and is attributed to widespread animal husbandry and to the traditional drinking of raw milk.<sup>1</sup> A careful history is helpful tool in the diagnosis of brucellosis. The history should include both assessment of risk factors and evaluation of any symptoms reported. Fever is the most common symptom and sign of brucellosis, occurring in 80-100% of cases. It is intermittent in 60% of patients with acute and chronic brucellosis and undulant in 60% of patients with subacute brucellosis. Fever can be associated with a relative bradycardia. Fever of unknown origin (FUO) is a common initial diagnosis in patients in areas of low endemicity. (Sharda and Lubani, 1986) In literature review of previous studies done they found that Patients with shoulder arthritis were the oldest. In the series of pediatric articular brucellosis, patients with shoulder arthritis are rarely found (Turan *et al.*, 2011; Benjamin and Khan, 1994; Al-Eissa *et al.*, 1990) or there are none (Shalaan *et al.*, 2002; Sharda and Lubani, 1986) Timely recognition and adequate treatment reduces the suffering of the patients as well as the frequency of relapses. The principle rule in the treatment of brucellosis is use of a combination of antibiotics to avoid relapses. Complications are rare in the patient who is treated appropriately, though relapse of infection may occur in 10% of patients.

## Conclusion

Musculoskeletal brucellosis is endemic in areas such as Saudi Arabia. Shoulder considered being a rare site of involvement.

Brucellosis should be considered in the line of differential diagnosis, especially in older patients with shoulder arthritis. Early recognition and adequate treatment, suffering of the patients can be reduced as well as the frequency of relapses.

## REFERENCES

- Al-Eissa, Y.A., Kambal, A.M., Alrabeeah, A.A., Abdullah, A.M.A., Al-Jurayyan, N.A. and Al-Jishi, N.M. 1990. Osteoarticular brucellosis in children. *Ann Rheum Dis.*, 49:896-900
- Aygen, B., Doganay, M., Sumerkan, B., Yildiz, O. and Kayabas, U. 2002. Clinical manifestations, complications and treatment of brucellosis: a retrospective evaluation of 480 patients. *Med Malad Infect*, 32:485-493
- Benjamin, B. and Khan, M.R.H. 1994. Hip involvement in childhood brucellosis. *J Bone Joint Surg (Br)*, 76-B:544-547
- Bosilkovski, M. and Rodriguez-Morales, A.J. 2014. Brucellosis and its particularities in children travelers. *Recent Pat Antiinfect Drug Discov.*, 9:164-172
- El-Desouki, M. 1991. Skeletal brucellosis: assessment with bone scintigraphy. *Radiology*, 181:415-418
- Geyik, M.F., Gur, A., Nas, K., Cevik, R., Sarac, J., Dikici, B., *et al.* 2002. Musculoskeletal involvement in brucellosis in different age groups: a study of 195 cases. *Swiss Med Wkly* 132:98-105
- Gotuzzo, E., Alarcon, G.S., Bocanegra, T.S., Carrillo, C., Guerra, J.C., Rolando, I. and Espinoza, L.R. 1982. Articular involvement in human brucellosis: a retrospective analysis of 304 cases. *Semin Arthritis Rheum.*, 12:245-255
- Madkour, M.M., Mohamed, A.R., Talukder, M.S. and Kudwah, A.M. 1985. Brucellosis in Saudi Arabia. *Saudi Med J.*, 6:324-332.
- Salata, R.A. and Ravdmn, J. 1985. Brucella species (brucellosis). In: Mandell GL, Douglas RG, Bennet JE, eds. Principle and practice of infectious disease. New York, NY: Wiley, 1283-1290.
- Shalaan, M., Memish, Z.A., Al Mahmoud, S., Alomari, A., Khan, M.Y., Almuneef, M. *et al.* 2002. Brucellosis in children: clinical observations in 115 cases. *Int J Infec Dis.*, 6:182-186
- Sharda, D.C. and Lubani, M. 1986. A study of brucellosis in childhood. *ClinPediatr (Phila)* Oct. 25:492-495
- Tasova, Y., Saltoglu, N., Sahin, G. and Aksu, H.S.Z. 1999. Osteoarticular involvement of brucellosis in Turkey. *Clin Rheumatol.*, 18:214-219
- Turan, H., Serefhanoglu, K., Karadeli, E., Togan, T. and Arslan, H. 2011. Osteoarticular involvement among 202 brucellosis cases identified in Central Anatolia region of Turkey. *Intern Med.*, 50:421-428