



## REVIEW ARTICLE

### IMMEDIATE VS DELAYED IMPLANT LOADING: THE CURRENT STATUS OF THE LITERATURE

**\*Imane Boujoual and Abderrahman Andoh**

Department of Fixed Prosthodontics, Faculty of Dentistry Hassan II University, Casablanca, Morocco

#### ARTICLE INFO

##### Article History:

Received 15<sup>th</sup> June, 2017  
Received in revised form  
17<sup>th</sup> July, 2017  
Accepted 11<sup>th</sup> August, 2017  
Published online 30<sup>th</sup> September, 2017

##### Key words:

Dental implants,  
Oral implants,  
Immediate loading,  
Delayed loading.

#### ABSTRACT

**Purpose:** Lately immediate loading of implants at the time of placement is becoming a viable treatment alternative, mainly in the aesthetic zone when replacing one or two teeth in the anterior maxilla. The main advantages are the reduction of patient discomfort, treatment duration and costs. In fact the patient could enter with an edentulism and leave the same day with an aesthetically acceptable implant-supported crown. The aim of this study is to compare the success rates and complications of immediately loaded implants with those of implants that were leaved to osseointegrate prior to loading.

**Materials and Methods:** A systematic review of the literature was conducted through the MEDLINE (PubMed) database between 03/01/2007 and 03/01/2017 and completed by a hand search in ebsco database. Only the randomised controlled trials (RCT) were included.

The following combination of MeSH terms was used: "Immediate Dental Implant Loading"[Majr] AND delayed implant loading AND complications. Two reviewers achieved screening and data abstraction.

**Results:** The first search through PubMed provided 17 papers. Then, after selecting only the randomised controlled trials we obtained 7 papers, the hand search yielded 7 (RCT) out of which only 5 met the inclusion criteria after full text selection. Therefore we obtained 12 articles were found potentially right to be included (after full text selection).

The most significant results were:

It was suggested to under dimension the drilling to achieve a higher torque value leading to stability of the implant and thus to a better outcome for immediate loading. The occurrence of complications depended on bone quality, implant type, implant dimensions, site and timing of placement, and splinting. Most of the authors concluded no statistically significant differences between the immediate and the delayed procedure, and stated that both of them are viable options.

**Conclusion:** Within the limitations of our review, it can be concluded that implants are, nowadays, able to obtain high torque values and acceptable success rates with excellent soft tissue healing when immediately loaded, as long as the patient selection is appropriate

Copyright©2017, Imane Boujoual and Abderrahman Andoh. This is an open access article distributed under the Creative Commons Attribution License, which permits unrestricted use, distribution, and reproduction in any medium, provided the original work is properly cited.

**Citation:** Imane Boujoual and Abderrahman Andoh, 2017. "Immediate VS delayed implant loading: The current status of the literature", *International Journal of Current Research*, 9, (09), 58141-58146.

## INTRODUCTION

Initially implant were left to osseointegrate and remain unloaded for 3 to 4 months in mandibles and 6 to 8 months in the maxillae. Recently immediate loading of implants at the time of placement (or within the first 72h) has become a viable treatment alternative, mainly in the aesthetic zone; this approach allows decreasing the patient's discomfort, the treatment's duration and costs. In fact the patient could enter with an edentulism and leave the same day with an aesthetically acceptable implant-supported provisional crown, which makes this approach very attractive. However, it is necessary to clarify its outcomes and compare them with the ones of the delayed loading method.

**\*Corresponding author: Imane Boujoual,**  
Department of Fixed Prosthodontics, Faculty of Dentistry Hassan II University, Casablanca, Morocco.

## MATERIALS AND METHODS

### Systematic Search Strategy

Before the beginning of the systematic literature search, the protocol was agreed by the authors and registered in PROSPERO under the number: 42017059833. An electronic search was performed through MEDLINE database (PubMed) (<https://www.ncbi.nlm.nih.gov/pubmed>). We meant to include only RCT published in English from "03/01/2007" to "03/01/2017" The following combination of MeSH terms was used in PubMed: "Immediate Dental Implant Loading"[Majr] AND delayed implant loading AND complications. Then a hand search was performed in ebsco database. Only the randomised controlled trials (RCT) were included. Two independent reviewers achieved the screening and data

abstraction. The literature search was conducted following the steps as seen in the flow chart below (Figure 1). The first step concerned entering the research equation followed by setting methodological filters. The second step was based on the hand searching. The third one was achieved by full-text selection.

### Inclusion criteria

Articles were included if all of the following inclusion criteria were existing:

- Randomised controlled trials of parallel group design and of split-mouth design reporting on immediate or early implant loading and their outcomes and complications.
- In each group in the study, at least the following outcomes were detailed: marginal bone loss, implant failure or survival rate, aesthetic outcome, and prosthetic complications.
- The type of edentulism, the site and the jaw must be detailed.
- The time of implant placement must be cited (post extractive or in a healed site).

### Exclusion criteria

Articles were excluded if they met one of the next exclusion criteria:

- Not RCT study.
- The patients enrolled in the study present a parafunctional habit.
- Articles reporting on the outcomes of sinus lift and short implants.
- Studies that concentrated on immediate placement of implant not loading.

Two authors extracted the data, and if there was a disagreement, the study was checked and discussed until consensus was reached.

## RESULTS

The first search through PubMed provided 17 papers. Then, after selecting only the randomised controlled trials we obtained 7 papers, the hand search yielded 7 (RCT) out of which only 5 met the inclusion criteria after full text selection. Therefore we obtained 12 articles were found potentially right to be included (after full text selection). The most significant results were:

### Insertion torque

It has been reported by many publications that high insertion torques guaranty a good initial stability of the implant leading to increase the osseointegration. (Al-Nawas B. 2013, Cannizzaro G. 2012)

### Underdrilling

To increase the implant primary stability, it has been recommended to under prepare the implant site using under dimensioned drills. Schincaglia and al.2016 suggested to use, the 3.2mmtwist drill as a final drill for Class III and IV of bones and the 3.7mm twist drills as the final drill for Class I and II quality bone respectively. Esposito and al. 2015 proposed

to use in case of hard bone quality the sequence of drills suggested by the manufacturer. However, in case of medium bone quality, they recommended under preparing the site using a final drill of one size smaller than the one suggested; and in case of soft bone, under preparing the site using a final drill of two diameters smaller than suggested.

### Quality of bone

It was stated that in case of critical bone quality some precautions are necessary such as: underpreparation of the implant sites, use of implant designs favouring achievement of high insertion torques (35 Ncm or more), and correct control of loading (Esposito and al. 2016). In accordance to the guidelines for the specific implant, tapping was not recommended in D IV bone. (Al-Nawas B. 2013)

### The role of design and surface modification

Several improved features have been proposed, regarding the geometry of the implant body or the surface modification

### Design's modification

Slightly tapered implant design and adjusted implant surface texture, has revealed to be an effective treatment substitute in sites exhibiting bone of poor quality. Also, the use of progressive thread implant design was shown to be a successful way to achieve good primary stability in these areas. (Meloni 2012, Schincaglia 2016)

### Surface modification

The latest generation of implant surfaces are characterized by a moderately rough configuration that has demonstrated higher bone-to-implant contact and faster bone deposition during the early healing phase. The use of an osteoconductive porous anodised surface promotes faster bone healing (Meloni 2012). Recently, a sandblasted surface treated with fluoride ions was introduced. In vitro and preclinical animal studies showed a faster rate of bone formation around implants with the fluoridated surface compared to the same surface without fluoride ions (Schincaglia 2016).

## DISCUSSION

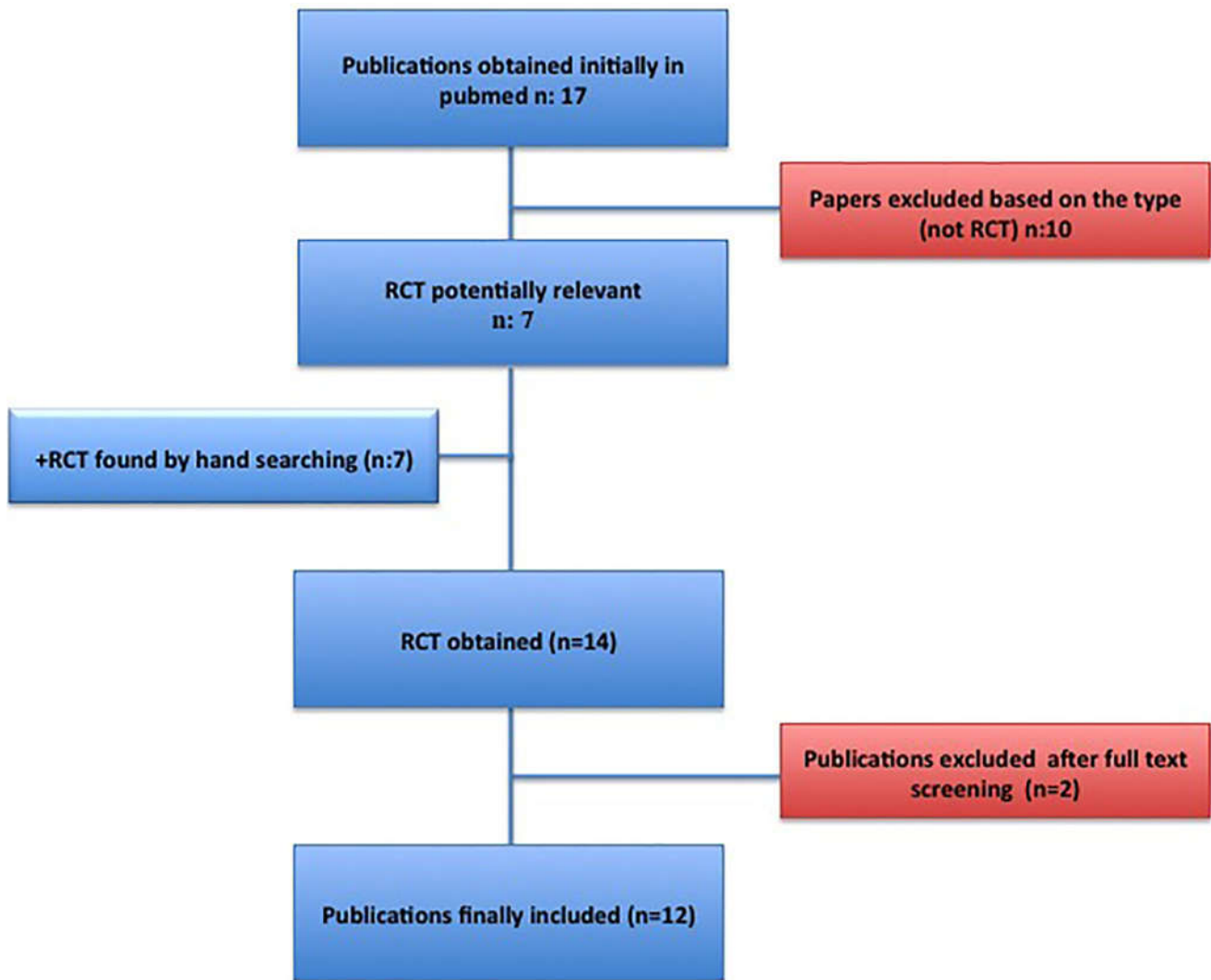
The aim of our review was to compare the outcomes of immediately loaded implants with those of implants that were leaved to osseointegrate prior to loading. During the analyse of the literature we faced some limitations such as:

- The small number of RCT published regarding the immediate loading.
- Most of these RCT were conducted by the same research groups
- The heterogeneity regarding the time of placement of the implant: immediately in post-extractive site or after bone healing.
- The heterogeneity concerning the variety of prostheses: single fixed, partial fixed, Implant-supported removable overdenture.
- The various sites: maxillary or mandibular jaw, posterior or anterior.
- The lack of information concerning the feature of loading: occluding or non-occluding.

Table 1. Table that resumes all the included articles with their respective outcomes

Authors	year	Population	Type of implant and/or prostheses	Time of loading	Design of the study	Comparison of outcomes	Results
Al-Nawas B. <i>et al.</i>	2012	104 patients	275 implants	163 Early loading 4 weeks 112 Conventional loading 12 weeks	Non blinded multicenter RCT	1-year failure rates were estimated 3.1% (5/163 implants) in the early loaded group (4 weeks) versus 3.6% (4/112 implants) in the 12 weeks group which demonstrated a statistically significant prognostic equivalence of 4 and 12 weeks loading.	Loading of standard SLA implants in the maxilla 4 weeks versus 12 weeks after insertion resulted in statistically equivalent failure patterns within a 1-year follow-up period
Cannizzaro and al.	2012	50 patients	100 implants	All loaded immediately a group with a torque between 25 to 35 Ncm a group with a torque >80 Ncm	Split mouth RCT	Seven implants inserted with a torque between 25 to 35 Ncm failed versus none of the implants inserted with a torque >35 Ncm. With the exception of crown/implant failures (exact McNemar significance $P = 0.0156$ , difference in proportions: -0.12; 95% CI -0.21 to -0.02) there were no statistically significant differences between groups for the other outcome measures such as complications, peri-implant marginal bone level changes, postoperative pain and presence of peri-implant apical radiolucency.	It is preferable to insert single implants with a high insertion torque, to minimise early implant failures, when loading them immediately.
Cannizzaro <i>et al.</i>	2012	30 patients	60 implants all were placed with flapless surgery	29 implants were immediately loaded and 31 early loaded	Split mouth RCT	Two implants failed in 2 patients: one immediately and the other early loaded. Seven implants affected by complications were loaded immediately whereas 6 were early loaded.	Flapless-placed 6.5 mm-long single implants can be immediately loaded and remain successful up to 4 years after loading. There were no statistically significant differences between groups for implant losses, complications, mean marginal bone level changes and patient preference.
Esposito M.	2016	81 patients	27 single implants 27 partial fixed prostheses 27 total fixed cross-arch	27 immediate loading 27 early loading 27 conventional	Parallel groups three arms	No implant failure or complication was reported; therefore, all three procedures seem to be viable.  To qualify for immediate and early loading, implants had to be inserted with a torque superior to 40 Ncm. To achieve this in medium and soft bone quality, implant sites were underprepared with drills having a diameter one or two sizes smaller than the final implant diameter.	No patient dropped out up to 4-months post-loading. No implant or prosthesis failed or any complications occurred. All loading strategies were highly successful and no differences could be observed for implant survival and complications when loading implants immediately, early or conventionally.
Felice and al.	2011	106 patients	54 patients: immediate implant placement out of which 65% were immediately loaded.	35 immediately loaded 19 not loaded	Multicenter pragmatic RCT Parallel groups	Failure: the immediate group (6%) in the delayed no failure. difference no statistically significant. Minor complications occurred more in the immediate group (statistically significant $P = 0.028$ ) Bone loss: less bone loss in the immediate group (1 year after loading) even though it's statistically significant (0.27 mm versus 0.13 mm), a difference of 0.14 mm between the two groups cannot be considered clinically relevant The aesthetic outcome appears to be similar for both groups.	Six patients dropped out 4 months after loading from the delayed group The present study supports the notion that post-extractive implants, which were immediately loaded could be at a higher risk of failures
Esposito M.	2015		52 patients delayed placement out of which 25% were immediately loaded	13 immediately loaded 39 not loaded			
Felice and al.	2015	50 patients	25 patients: immediate implant placement out of which (64%) were immediately loaded.  25 patients delayed placement out of which 24% were immediately loaded	16 immediately loaded 9 not loaded  6 immediately loaded 19 not loaded	Parallel design group	Failure: 2 implants failed in the immediate group (8%) no statistical significance Three minor complications occurred in the immediate group and two in the delayed group (not statistically significant) The aesthetic score was 12.42 and 12.28 in the immediate and delayed groups, respectively. At 1 year after loading: 12.78 and 12.22 respectively. There were no statistically significant differences Marginal bone levels at implant insertion (after bone grafting) were 0.01 mm for immediate and 0.06 mm for delayed implants, One year after loading, patients of the immediate group lost on average 0.13 mm marginal bone and those in the delayed group lost 0.19 mm, however the difference was not statistically significant (mean difference = 0.05; 95% CI: -0.002 to 0.110; $P = 0.06$ ). All patients were fully satisfaction: 100% for both groups, both for function and aesthetics.	No significant differences were detected between the two procedures, although the only two implant failures were for immediate post-extractive implants immediately loaded. It seems challenging to obtain an implant insertion torque superior to 35 Ncm in sockets preserved with algae-derived bone substitute after a 4-month healing period than at immediate post-extractive sites.

Authors	year	Population	Type of implant and/or prostheses	Time of loading	Design of the study	Comparison of outcomes	Results
Grandi T.	2013	80 patients	fixed restorations supported by two implants	81 implants were immediately loaded and 80 were early loaded after 2 months,	multicenter RCT parallel design	Two immediately loaded patients and 1 early loaded patient dropped out at 3 years.No implant failed. Two complications occurred in the immediate loading group and 1 in the early loading group. Bone loss:There were no significant differences in bone levels changes at 36 months between the two groups (P = 0.67; difference 0.2 mm; 95% CI -0.23, 0.63). Immediately loaded implants lost 0.90 mm (95% CI 0.63, 1.17) and early loaded implants 1.10 mm (95% CI 0.81, 1.39).	If adequate primary stability was achieved, no statistically significant difference in failure rates, complications or bone level changes between implants loaded immediately or early were observed 3 years after placement in partially edentulous
Heinemann and al.	2016	50 patients	Partially edentulous patients treated with one to three dental implants	25 patients immediately loaded definitive screw-retained metal-ceramic prosthesis in occlusion within 1 week 25 patients immediate non-occluding loading with provisional acrylic reinforced prosthesis within 24 h after implant placement	Pragmatic multicenter RCT parallel design	No patient dropped out. Two immediately occlusally loaded implants with their related definitive prostheses (8%) failed early (difference in proportions = 0.08; 95% CI: -0.03 to 0.19; P = 0.490). Four complications occurred in the occlusal group versus one in the non-occlusal group; (difference in proportions = 0.12; 95% CI: -0.04 to 0.28; P = 0.349). Four months after loading, patients subjected to non-occlusal loading lost an average of 0.72 mm of peri-implant bone versus 0.99 mm of patients restored with occluding definitive partial fixed prostheses. There were no statistically significant differences for marginal bone level changes between the two groups (mean difference = -0.27 mm; 95% CI: -0.84 to 0.30; P = 0.349). The differences for aesthetic scores showed no statistical significance (8.26 versus 7.58; P = 0.445); the same was seen for aesthetics evaluated by patients (Mann-Whitney U test: P = 0.618). Patients in the non-occlusal group were significantly more satisfied with the function of their implant-supported prostheses (Mann-Whitney U test: P = 0.039).	The results of this study did not provide a conclusive answer on whether immediate non-occlusal loading may decrease implant failures when compared to immediate occlusal loading, but suggest that non- occlusal loading may increase patient functional satisfaction, chair time and the number of visits. Larger trials are needed to properly answer this question.
Meloni SM.	2012	20 patients	bilaterally missing first mandibular molars All the implants were inserted in healed healthy bone	20 implants immediate loading 20 implants conventional loading	RCT split mouth	No patients dropped out and no implant failed. Only minor prosthetic complications were observed (2 provisional acrylic crown fractures in the immediate loading group and 2 ceramic chipping in the delayed loading group). Mean marginal bone loss was $0.83 \pm 0.16$ mm (95% CI 0.75 to 0.91) in the immediate loading group and $0.86 \pm 0.16$ mm (95% CI 0.78 to 0.94) in the conventional loading group and no statistically significant differences between the two groups were observed (P = 0.530). Mean PPD and BOP values were, respectively, $2.76 \pm 0.48$ (95% CI 2.55 to 2.97) and $1.30 \pm 0.73$ (95% CI 0.98 to 1.62) in the immediate loading group, and $2.70 \pm 0.37$ (95% CI 2.54 to 2.86) and $1.40 \pm 0.75$ (95% CI 1.07 to 1.73) in the conventional loading group. Also, a statistical comparison of BOP and PPD did not show any significant difference (P = 0.163 and P = 0.652, respectively).	the clinical outcome of immediate versus delayed loading of implants in single mandibular molar sites is comparable.
Schincaglia GP.	2016	30 patients	Implant-supported mandibular overdentures (2 unsplinted implants per patient)	15 patients received 30 Immediately loaded implants and 15 patients received 30 conventionnally loaded implants	Single blind parallel arms RCT	Thirty participants (15 in the IL and 15 in the DL groups) were evaluated at 12 months. The implant cumulative survivalrates were 100% and 93% for DL and IL, respectively. The mean RBL from baseline to 1 year was $0.54 (\pm 0.5)$ mm and $0.25 (\pm 0.5)$ mm for DL and IL, respectively. A statistically significant difference was observed at 12 months, with less radiographic bone loss (RBL) in the IL group, insertion torque and implant length were not correlated with RBL. Also, no difference in frequency of maintenance visits and prosthetic complications was reported between the groups.	Immediate loading of two unsplinted implants supporting a Locator-retained mandibular OVD seems to be a suitable treatment option. Significantly less radiographic bone loss was observed after 1 year of loading around IL implants than around DL implants. Furthermore, neither implant length nor insertion torque seemed to affect RBL 1 yearaftersurgicalplacement.
Shibly and al.	2010	60 patients	60 single implant immediately placed (in post-extractive sites)	30 immediately loaded 30 not loaded	Single blind parallel arms RCT	In the immediate loading group the implant survival rate at 2 years was 96.7%, and the mean bone gain was 1.19 mm. The corresponding figures in the conventional loading group were 93.3% and 1 mm. The gain in bone level occurred mainly from baseline to 1 year postoperatively in both groups (P <0.001). The papilla index decreased from baseline to 1 year in both groups (P <0.001) and changed only slightly thereafter. There were no significant differences between the two groups in the amount of bone gain or papilla index change during 2 years.	Immediate loading of a single implant placed in a fresh extraction site in periodontally compromised patients resulted in similar bone gain and soft tissue esthetic outcomes compared to delayed loading. Primary closure and delayed loading to ensure bone regeneration around implants were not critical in this study.



**Figure 1. Flow chart that shows the articles selection process**

It is known that the actual tendency in the dental field is to shorten the treatment duration and decrease the treatment costs, immediate implant loading has proven to be a reliable method with no significant differences regarding the clinical outcomes, complications, and patient's satisfaction, when compared to the conventional implant loading. Still it is crucial to emphasize on some precautions like, under drilling the implant sites particularly in the presence of critical bone quality, achieving a good primary stability by a high insertion torque and adjusting the occlusal loading. Conversely, Alnawas and al. concluded that under dimensioned drilling showed no significant influence on the success rate (1). Cannizzarro and al. 2012 indicated that in order to be effective in a predictable way, higher insertion torques are required, but we are unable yet to specify how much higher the insertion torque should be. However, torques of approximately 35 Ncm appear to be sufficient to achieve good clinical results. Although some authors have raised concerns on the dangerous effect of high insertion torques as a possible cause of compression necrosis of the bone, animal and RCT human studies have shown no detrimental effect of high insertion torques (> 50 Ncm or even to 80 Ncm) on peri-implant bone healing. (Schincaglia GP. 2016, Cannizzarro and al. 2012, Esposito M. 2015). Implant modified surface have also been reported as a successful alternative. Cannizzarro and al. 2012 excluded in their trials patients with poor bone quality (soft bone). While others didn't mention the quality of bone in

their trials. Additionally, if considering early versus immediate implant loading, Esposito and al. 2016 specify that it might be wiser to load implants immediately, since there are no additional advantages or benefits to early loading, and patients are more likely to prefer immediate loading. An interesting trial of a medium-term follow-up (4 years after loading) (Cannizzarro and al. 2012) presented some interesting hints on whether it is possible to load immediately or early at 6 weeks short implants of 6.5 mm length placed according to a flapless procedure and concluded a success rate of 93.3% suggesting that immediate or early loading of flapless-placed implants are both viable procedures. During the follow-up, no implant failed, marginal bone levels remained virtually stable and the minor additional complications that occurred were related to insufficient levels of oral hygiene. There is still a debate regarding the difference between immediate occluding loading and non-occluding loading (immediate provisionalisation), we meant to ignore this parameter because even non-occluding restorations become essentially functionally occluding when masticating. Only one RCT investigated this trend, but the results of this study did not provide a conclusive answer on whether immediate non-occlusal loading may decrease implant failures when compared to immediate occlusal loading. (Heinemann F. 2016) Moreover, in all the RCTs reviewed the operators were highly experienced in immediate loading procedures. Thus the generalization of the findings should be handled with care.

There were no statistically significant differences between the immediate and the delayed loading for:

- Implant failures,
- Complications,
- Aesthetic scores,
- Andperi-implant marginal bone level changes.

By contrast, Schincaglia GP. 2016 reported that the marginal bone loss may decrease significantly with the immediate loading procedure and this was confirmed by many studies (in vitro and in vivo Qi MC, Duyck *et al*, Vandamme K, Grassi and al.), the biologic explanation of this positive effect of loading improving the primary phase of bone healing is linked to the response of mesenchymal stem cells to mechanical strain and their consequent gene expression patterns.

These findings suggested that mechanical strain might act as a stimulator to induce differentiation of stem cells into osteoblasts. Actually, cyclic tensile strain has been shown to increase osteoprotegerin synthesis and decrease soluble receptor activator of nuclear factor kappa-B ligand (RANKL), thus favoring bone formation. Duyck *et al* confirmed this theory in a rabbit model and concluded that mechanical loading stimulated bone formation and led to higher bone quality.

## Conclusion

Based on the findings and taking into account the limitations of our review, it can be concluded that implants are, nowadays, able to obtain high torque values and acceptable success rates with excellent soft tissue healing when immediately loaded, as long as the patient selection is appropriate. Decreasing the treatment's cost and duration.

## REFERENCES

- Al-Nawas B, Krummenauer, Büchter A, Kleinheinz J, Neukam F, G Petrin, K A Schlegel. 2013. Multicenter Randomized Clinical Trial: Early Loading of Implants in Maxillary Bonecid. *Clinical Implant Dentistry and Related Research*, Volume 15, Number 5: 625-36. DOI 10.1111/j.1708-8208.2011.00427.x
- Cannizzaro, G., Leone, M., Ferri, V., Viola, P., Federico, G. and Esposito, M. 2012. Immediate loading of single implants inserted flapless with medium or high insertion torque: a 6-month follow-up of a split-mouth randomised controlled trial. *Eur J Oral Implantol*. 5(4):333–342. PMID:23304687
- Cannizzaro, G., Felice, P., Leone, M., Ferri, V., Viola, P. and Esposito, M. 2012. Immediate versus early loading of 6.5 mm-long flapless-placed single implants: a 4-year after loading report of a split-mouth randomised controlled trial. *Eur J Oral Implantol*. Summer. 5(2):111-21. PMID: 22866288
- Esposito, M., Barausse, C., Pistilli, R., Jacotti, M., Grandi, G., Tucco, L. and Felice, P. 2015. Immediate loading of post-extractive versus delayed placed single implants in the anterior maxilla: outcome of a pragmatic multicenter randomised controlled trial 1-year after loading. *Eur J Oral Implantol*. 8(4):347–358 PMID:26669545
- Esposito, M., Siormpas, K., Mitsias, M., Bechara, S., Trullenque-Eriksson, A. and Pistilli, R. 2016. Immediate, early (6 weeks) and delayed loading (3 months) of single implants: 4-month post-loading from a multicenter pragmatic randomised controlled trial. *Eur J Oral Implantol*. 9(3):249-260. PMID: 27722223
- Felice, P., Pistilli, R., Barausse, C., Trullenque-Eriksson, A. and Esposito, M. 2015. Immediate non-occlusal loading of immediate post-extractive versus delayed placement of single implants in preserved sockets of the anterior maxilla: 1-year post-loading outcome of a randomised controlled trial. *Eur J Oral Implantol*. Winter. 8(4):361-72. PMID: 26669546
- Felice, P., Soardi, E., Piattelli, M., Pistilli, R., Jacotti, M. and Esposito, M. 2011. Immediate non-occlusal loading of immediate post-extractive versus delayed placement of single implants in preserved sockets of the anterior maxilla: 4-month post-loading results from a pragmatic multicenter randomised controlled trial. *Eur J Oral Implantol*. Winter. 4(4):329-44. PMID: 22282730
- Grandi, T., Guazzi, P., Samarani, R. and Grandi, G. 2013. A 3-year report from a multicenter randomised controlled trial: immediately versus early-loaded implants in partially edentulous patients. *Eur J Oral Implantol*. Autumn. 6(3):217-24. PMID: 24179976
- Heinemann, F., Grufferty, B., Papavasiliou, G., Dominiak, M., García, J.J., Trullenque-Eriksson, A. and Esposito, M. 2016. Immediate occluding definitive partial fixed prosthesis versus non-occluding provisional restorations - 4-month post-loading results from a pragmatic multicenter randomised controlled trial. *Eur J Oral Implantol*. Spring. 9(1):47-56. PMID: 27022636
- Meloni, S.M., De Riu, G., Pisano, M., De Riu, N. and Tullio, A. 2012. Immediate versus delayed loading of single lower molars. One-year results from a randomised controlled trial. *Eur J Oral Implantol*. 5:345-353.
- Schincaglia, G.P., Rubin, S., Thacker, S., Dhingra, A., Trombelli, L. and Ioannidou, E. 2016. Marginal Bone Response Around Immediate- and Delayed-Loading Implants Supporting a Locator-Retained Mandibular Overdenture: A Randomized Controlled Study. *Int J Oral Maxillofac Implants*. Mar-Apr. 31(2):448-58. doi: 10.11607/jomi.4118
- Shibly, O., Patel, N., Albandar, J.M. and Kutkut, A. 2010. Bone regeneration around implants in periodontally compromised patients: a randomized clinical trial of the effect of immediate implant with immediate loading. *J Periodontol*. Dec. 81(12):1743-51. doi: 10.1902/jop.2010.100162.

\*\*\*\*\*