



RESEARCH ARTICLE

SHORT-RANGE GUNSHOT INJURY TO LOWER PART OF FACE: A CASE REPORT

^{1,*}Ravi Kiran, B.S., ²Sachdeva, A., ³Sasank, V.K. and ⁴Mishra, A.

¹Senior lecturer, Dept of Oral and Maxillofacial Surgery, Sri Sai College of Dental Surgery, Vikarabad

²Consultant Prosthodontist, Jagadish Gouda Dental Hospital, Bengaluru

³Senior lecturer, Dept of Oral and Maxillofacial Surgery, Sri Sai College of Dental Surgery, Vikarabad

⁴Associate Professor, Dept. of Periodontics, Sri Sai College of Dental Surgery, Vikarabad

ARTICLE INFO

Article History:

Received 12th June, 2017

Received in revised form

26th July, 2017

Accepted 15th August, 2017

Published online 29th September, 2017

ABSTRACT

Foreign bodies that enter a patient as a result of trauma are contaminated and produce a range of symptoms. Gunshot injury are known to cause severe morbidity in head and neck region. The complex facial anatomy is a challenge to medical and oral surgeons in reconstruction. We report a case in which the patient gives history involving a gunshot injury to the chin. The patient did not have any major complaints relating to the bullet injury in his mandible or any symptoms. However the bullet injury caused severe comminution of the lower border of the symphysis of mandible.

Key words:

Ballistic injuries,

Cavitation,

Mandibular symphysis,

Pellets.

Copyright©2017, Ravi Kiran et al. This is an open access article distributed under the Creative Commons Attribution License, which permits unrestricted use, distribution, and reproduction in any medium, provided the original work is properly cited.

Citation: Ravi Kiran, B.S., Sachdeva, A., Sasank, V.K. and Mishra, A.. 2017. "Short-range gunshot injury to lower part of face: a case report", International Journal of Current Research, 9, (09), 57213-57215.

INTRODUCTION

Gunshot wounds to the face present serious challenges to the oral and maxillofacial surgeons. These injuries result from assaults, accidents or suicide attempts. In contrast to blunt facial trauma, ballistic injuries result in significant bone and soft tissue loss, whose severity is not always apparent at initial presentation. Reconstruction of these defects is often complicated by tissue ischaemia, necrosis and infection (Thorne, 1992; Clark et al., 1996). Ballistic injuries can be classified as low-velocity or high-velocity. Generally, low-velocity injuries are from projectiles travelling at less than 1200 feet/s. High-velocity missiles are those travelling at greater than 1200 feet/s. The degree of surrounding tissue injury from a gunshot wound is related to the mass of the projectile and the square of its velocity (kinetic energy = $1/2 mv^2$) (DeMuth, 1971). Low-velocity injuries cause limited damage along the missile path and result in little bone and soft tissue loss. These are generally treated similarly to blunt facial trauma, with limited debridement, immediate bony reconstruction and primary soft tissue closure (Vayvada et al., 2005).

Case report

A 34 year-old male reported to the department of Oral and Maxillofacial surgery of Oxford Dental College and Hospital, Bangalore 4 hrs after sustaining a bullet injury on the face. The patient was shot with the hand gun at a very short distance. The bullet entrance wound was in right submandibular region. Possible exit wound for the bullet could be identified in submental region. The patient was fully conscious, well oriented to time, place and person. His vital signs were within normal limits. There was no derangement in occlusion. On inspection, there was submental lacerating injury. Multiple fractured segments were visible in lower symphysis area of mandible. Provisional diagnosis was comminuted middle symphysis fracture lower border. Initial debridement of the lacerated non-vital soft tissue wound was done under local anesthesia and soft tissue closure was done primarily where it was possible and within limits. The patient was then admitted in our ward and planned for operation under local anesthesia and all the necessary routine investigations were advised along with orthopantomogram. In the operation room, surgical site was prepared and the surgical site was approached through the existing lacerated wound in the submental region. Fracture site was exposed and after careful exploration, bullet fragments/pellets were removed.

*Corresponding author: Ravi Kiran, B.S.,

Senior lecturer, Dept of Oral and Maxillofacial Surgery, Sri Sai College of Dental Surgery, Vikarabad

The wound was then closed in 2 layers using 3-0 vicryl sutures and 3-0 mersilk for skin closure.

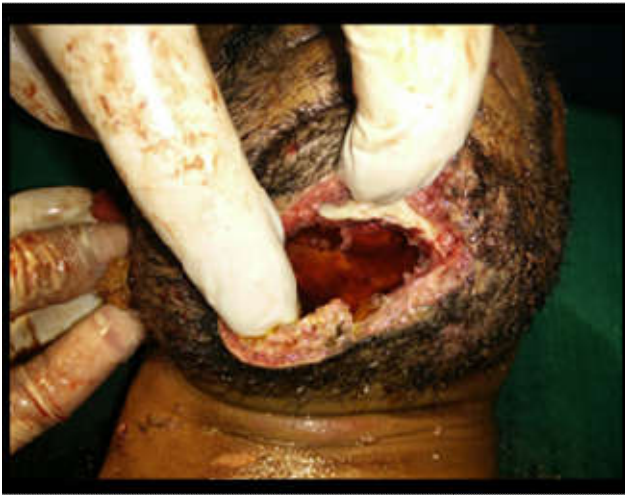

Fig.1. Exit point of the Bullet

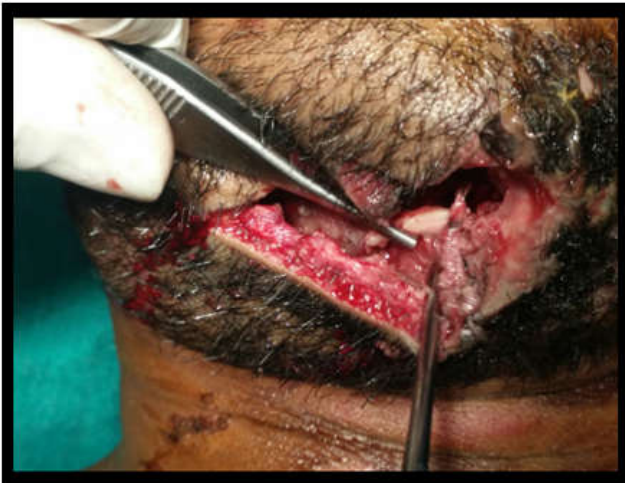

Fig.2. Removal of the bony fragments




Fig.3. Retrieval of the bullet pellets from the site

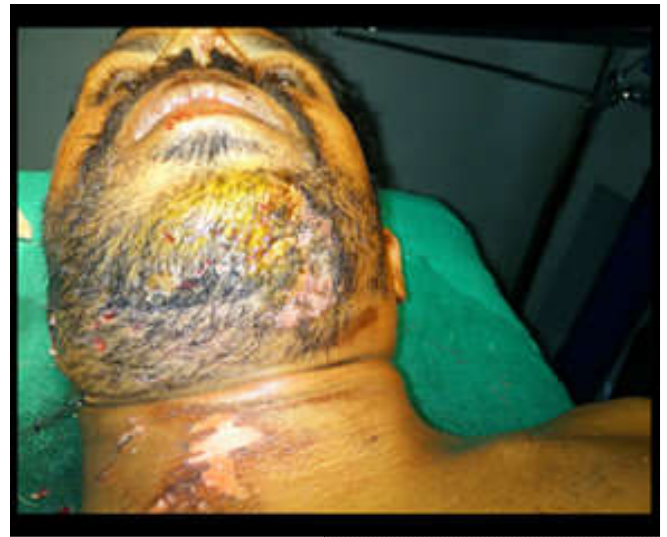

Fig. 4. Approximation of the surgical site

DISCUSSION

From the patient's history, it can be deduced that the weapon used must have had a very low wounding capacity. The home-made gun which is also known as the muzzleloader, may be considered to be the most primitive kind of firearm. It carries pellets (charge) detonated by gunpowder in a ratio enough for its propulsion out of the weapon and to strike the target at high velocity causing serious damage. This high velocity shot from such a weapon at close range would cause fatal injuries (Wilson, 1999; Bahador, 2006), but such circumstances were not seen in our patient. Hence, we assumed that the charge gunpowder proportion must have been so high that the explosion of the small amount of gunpowder did not allow the pellets to gain sufficient velocity to overcome the resistance of the subcutaneous tissues (Wilson, 1999), resulting in a cone like spread of bullets with a heavy concentration of them in the mental area with no evidence of a fatal exit wound causing them to remain lodged in the maxillofacial area.

Bullets crushes structures along its path thus causing temporarycavitation, shearing and compression of the structures and sometimes tears the structures (as with solid abdominal viscera) or stretching inelastic tissue (the brain). As tissues recoil and hot gases dissipate, soft tissue collapses inwards, and hence, a permanent cavity is formed. Additionally, kinetic energy transfer occurs during retardation of the bullet and this may cause damage outside the tract. There are several factors influencing the efficiency of kinetic energy transfer which are 1.the kinetic energy of a body 2. proportional to mass and velocity 3.Projectile's deformation and fragmentation 4.Entrance profile and path travelled through the body and biological characteristics of the tissues (Newgard, 1992). High-velocity injuries have traditionally been assumed to cause more damage than low-velocity ones have, an assumption that is still under dispute. A close-range, high-velocity gunshot wound can result in devastating facial disfigurement and disability in those who survive. Airway management is a major concern in patients with maxillofacial ballistic injuries because a compromised airway can lead to death. Although there are many options to secure airway, each has specific indications, and the choice ultimately depends on the patient's situation and the expertise of the trauma team (Lindsey, 1980; Hollier *et al.*, 2001).

In general, endotracheal intubation is usually not a viable option in cases of profuse bleeding from oronasalcavity. Cricothyroidotomy, tracheostomy or percutaneous needle tracheostomy are preferred to secure airway in emergencies. Other procedures for consideration are the submental or submandibular intubation techniques, which can provide a clearfield for facial surgeries. An early and comprehensive surgical management of soft tissue at the first stage with less aggressive debridement can decrease morbidity. A primary closure or local flaps are preferred over secondary healing as it may cause excessive scarring. Antibiotics play a major role in preventing infections in both hard and soft tissues after primary closure of class IV wounds. Appropriate wound debridement, immobilization and fixation, detailed wound closure, drainage and maintenance of clean dressings, nutrition and circulating fluid volume are equally important. The haemodynamics of the patient should be addressed as the oxygen-carrying capacity influences both wound healing and prevention of infection (Osborne, 1991; Shelton, 1992). The penetrating injuries to the face can cause minor or major devastating consequences. The general condition of the patient, timing and treatment sequencing, extent of damage, proper reconstruction method and rehabilitation are helpful for the final functional and aesthetic outcome (Motamedi, 2007).

Conclusion

Even with a comprehensive primary management approach, penetrating maxillofacial injuries are associated with a significant number of residual problems. The majority of these, however, can be addressed as an outpatient basis. Treatment options necessitate clinical judgement and no strict protocol can be uniformly applied to all patients. With the antibiotics and surgical hardware at hand, the majority of maxillofacial penetrating injuries can be treated definitively at the time of debridement when the general status of the patient permits and when this is in the best interest of the patient.

REFERENCES

- Ayvada H, Menderes A, Yilmaz M, Mola F, Kzlkaya A, Atabey A. 2005. Management of close-range, high energy shotgun and rifle wounds to the face. *J Craniofac Surg.*, 16:794-804.
- Bahador A. 2000. Chest injury in close-range shot by Muzzle Loader gun: report of two cases. *Irn J MedSci.*, 25:153-155
- Clark N, Birely B, Manson PN, Slezak S, Kolk CV, Robertson B *et al.* 1996. High energy ballistic and avulsive facial injuries: classification, patterns, and an algorithm for primary reconstruction. *Plast Reconstr Surg.*, 98:583-601.
- DeMuth Jr WE. 1971. The mechanism of shotgun wounds. *J Trauma.*, 11:219-229.
- Hollier L, Grantcharova EP, Kattash M. 2001. Facial gunshot wounds: a 4-year experience. *J Oral Maxillofac Surg.*, 59:277-282
- Lindsey D. 1980. The idolatry of velocity, or lies, damn lies, and ballistics. *J Trauma.*, 20:1068-1069
- Motamedi MH. 2007. Primary treatment of penetrating injuries to the face. *J Oral Maxillofac Surg.*, 65:1215-1218.
- Newgard K. 1992. The physiological effects of handgun bullets: the mechanisms of wounding and incapacitation. *Wound Ballist Rev.*, 1:7-12
- Osborne TE, Bays RA. 1991. Pathophysiology and management of gunshot wounds to the face. In: Fonseca RJ, Walker RV, eds. *Oral and Maxillofacial Trauma*. vol. 2. Philadelphia, PA: Saunders, 672-679.
- Shelton DW. Gunshot wounds. 1992. In: Peterson LJ, Indresano AT, Marciani RD, eds. *Principles of Oral and Maxillofacial Surgery*. Vol.2. Philadelphia, PA: JB Lippincott; 596-614.
- Thorne, CH. 1992. Gunshot wounds to the face. Current concepts. *Clin Plast Surg.*, Jan; 19(1):233-44.
- Wilson A J. 1999. Gunshot injuries: what does a radiologist need to know? *RadioGraphics*, 19:1358-1368.
