



CASE REPORT

KNOTTED ELECTRICAL WIRE AS A FOREIGN BODY IN A MALE URETHRA: A CASE REPORT

*Dr. Sohail Anwar Azami

Katihar Medical College, India

ARTICLE INFO

Article History:

Received 05th August, 2017
Received in revised form
23rd September, 2017
Accepted 13th October, 2017
Published online 30th November, 2017

Key words:

Urethral Injury, SPC

*Corresponding author:

Dr. Sohail Anwar Azami,
Katihar Medical College, India.

ABSTRACT

Introduction: Self-insertion of foreign bodies into the male urethra and urinary bladder for autoerotic stimulation is a rather rare emergency condition that an urologist may encounter. A case of a knotted electrical wire inserted in the male urethra and tip of the wire seen in external urethra and other end in the bladder is presented.

Case presentation: A 16 year old male presented with the inability to void and bloody urethral discharge after having introduced an electrical wire into his urethra for masturbation 24 hours earlier. He had made several unsuccessful attempts to remove it. During the physical examination, one end of the wire was observed in the urethral meatus. An x-ray of kidney, ureter, bladder (KUB) demonstrated a coiled up radiopaque wire inside the bladder. The patient was unmarried with father accompanying him. It was the first time he had ever self-inflicted a foreign body in his urethra and he had history of psychiatric illness and no drug addiction. CT scan was showing a knotted wire inside the penile urethra. After giving his formal consent, the patient was taken to the operating room.

Under spinal anesthesia, an unsuccessful trial was made to pull the wire. Then a suprapubic cystostomy was performed and the wire was removed. The patient was discharged on the 8th postoperative day with the urethral catheter in situ. Patient was called in OPD after 2 weeks and Foley's catheter removed. A very few cases of self-inflicted foreign bodies have been reported in the male urethra and urinary bladder. The variety of these objects is really impressive, including sharp and lacerating objects (e.g. needle, pencil, wire), wire-like objects (cable, rubber tube), parts of animals (bones) or plants and vegetables (hay, cucumber), fluids (e.g. glue) and powders (e.g. cocaine). The most common reason for self-insertion of a foreign body into the male urethra is of erotic or sexual nature, especially masturbation or sexual gratification. A mental illness or drug intoxication may also be the reason. Masturbation in males is very frequent with a rate close to 100%. In the majority of cases, the patient feels guilty and humiliated, therefore he postpones the search for medical help. In our case, the patient was expressing repentance for his action. A few very interesting psychiatric-psychoanalytic theories have been postulated. According to Kenney's theory, the initiating event is the coincidentally discovered pleasurable stimulation of the urethra, followed by repetition of this action with objects of unknown danger, driven by a particular psychological predisposition to sexual gratification. Wise considered urethral manipulation as a paraphilia combining sadomasochistic and fetishistic elements where the orgasm of the individual depends on the presence of the fetish. He believed it shows a regression to a urethral stage of erotism due to a traumatic event or a strong libidinal drive. From the clinical view, many authors advocate the psychiatric evaluation of these patients, based on theories that consider this act as an indication of an impulsive behavior, self-punishing in nature that may aggravate to suicide. The psychiatric evaluation is controversial as many of these patients are psychologically normal. Clinical presentation may vary from asymptomatic to swelling of external genitalia, dysuria, poor urinary stream or retention, bloody or purulent urethral discharge and ascending urinary tract infection. Depending on the type of foreign body and its location, various methods of removal have been described, including meatotomy, cystoscopy, internal or external urethrotomy, suprapubic cystostomy and injection of solvents. Removal of the foreign body may be quite challenging requiring imagination and high-level surgical skills. Endoscopic therapy is the standard. The most suitable method is relevant to the size and mobility of the object. In the majority of mobile objects inside the urethra, the mobility is towards the bladder where, after having been pushed, the foreign body can be grasped by forceps or retrieval baskets. Nephroscopes have been used for the retrieval of screws as well as magnetic retrievers for galvanic objects. The YAG laser has also been used lately. In cases where endoscopic procedures are unsuccessful, then open surgery is recommended. For objects stuck in the penile urethra, external urethrotomy is recommended, while for intravesical foreign bodies, a suprapubic cystostomy is the treatment of choice.

Conclusion: A self-inflicted foreign body in the urethra and bladder is a rare situation. Endoscopic manipulation is the preferred first-line treatment and if unsuccessful, open procedures may be necessary.

Copyright©2017, Dr. Sohail Anwar Azami. This is an open access article distributed under the Creative Commons Attribution License, which permits unrestricted use, distribution, and reproduction in any medium, provided the original work is properly cited.

Citation: Dr. Sohail Anwar Azami, 2017. "Knotted electrical wire as a foreign body in a male urethra: A case Report", *International Journal of Current Research*, 9, (11), 61365-61367.

INTRODUCTION

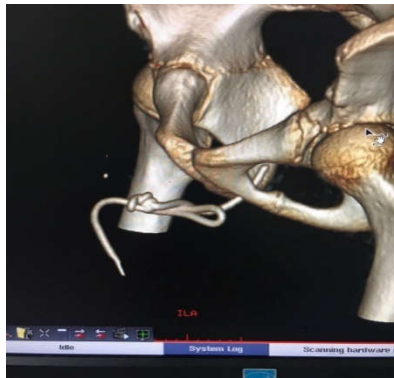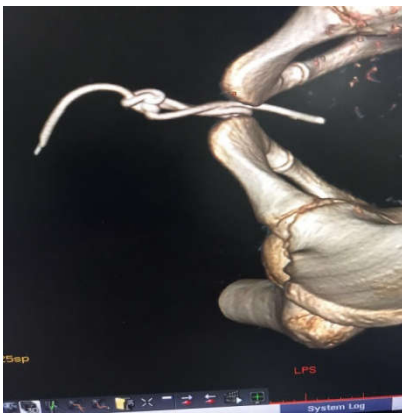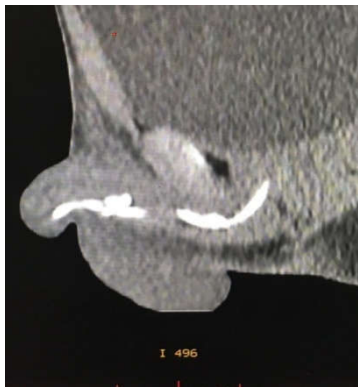Self-insertion of foreign bodies into the male urethra and urinary bladder for autoerotic stimulation is a rather rare emergency condition that an urologist may encounter. A case of a knotted electrical wire inserted in the male urethra and

tip of the wire seen in external urethra and other end in the bladder is presented.

Case Presentation

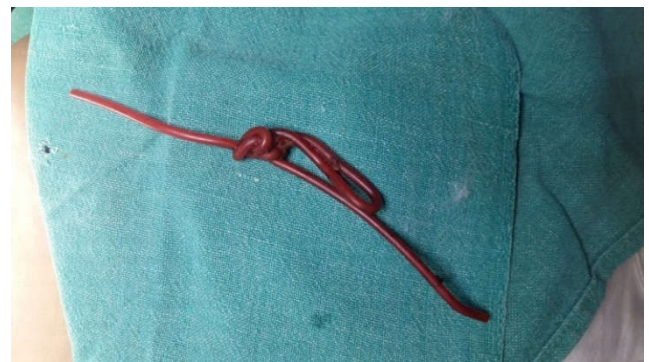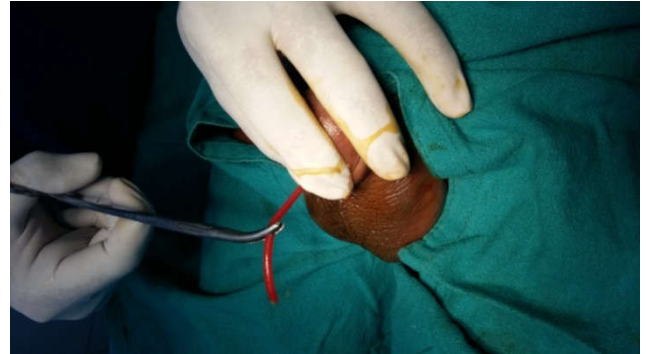
A 16 year old male presented with the inability to void and bloody urethral discharge after having introduced an electrical

wire into his urethra for masturbation 24 hours earlier. He had made several unsuccessful attempts to remove it.



During the physical examination, one end of the wire was observed in the urethral meatus. An x-ray of kidney, ureter, bladder (KUB) demonstrated a coiled up radiopaque wire inside the bladder. The patient was unmarried with father accompanying him. It was the first time he had ever self-inflicted a foreign body in his urethra and he had history of psychiatric illness and no drug addiction. CT scan was

showing a knotted wire inside the penile urethra. After giving his formal consent, the patient was taken to the operating room. Under spinal anesthesia, an unsuccessful trial was made to pull the wire. Then a suprapubic cystostomy was performed and the wire was removed. The patient was discharged on the 8th postoperative day with the urethral catheter in situ. Patient was called in OPD after 2 weeks and Foley's catheter removed.



DISCUSSION

A very few cases of self-inflicted foreign bodies have been reported in the male urethra and urinary bladder. The variety of these objects is really impressive, including sharp and lacerating objects (e.g. needle, pencil, wire), wire-like objects (cable, rubber tube), parts of animals (bones) or plants and vegetables (hay, cucumber), fluids (e.g. glue) and powders (e.g. cocaine). The most common reason for self-insertion of a foreign body into the male urethra is of erotic or sexual nature, especially masturbation or sexual gratification. A mental illness or drug intoxication may also be the reason. Masturbation in males is very frequent with a rate close to 100%. In the majority of cases, the patient feels guilty and humiliated, therefore he postpones the search for medical help.

In our case, the patient was expressing repentance for his action. A few very interesting psychiatric-psychoanalytic theories have been postulated. According to Kenney's theory, the initiating event is the coincidentally discovered pleasurable stimulation of the urethra, followed by repetition of this action with objects of unknown danger, driven by a particular psychological predisposition to sexual gratification. Wise considered urethral manipulation as a paraphilia combining sadomasochistic and fetishistic elements where the orgasm of the individual depends on the presence of the fetish. He believed it shows a regression to a urethral stage of erotism due to a traumatic event or a strong libidinal drive. From the clinical view, many authors advocate the psychiatric evaluation of these patients, based on theories that consider this act as an indication of an impulsive behavior, self-punishing in nature

that may aggravate to suicide. The psychiatric evaluation is controversial as many of these patients are psychologically normal. Clinical presentation may vary from asymptomatic to swelling of external genitalia, dysuria, poor urinary stream or retention, bloody or purulent urethral discharge and ascending urinary tract infection. Depending on the type of foreign body and its location, various methods of removal have been described, including meatotomy, cystoscopy, internal or external urethrotomy, suprapubic cystostomy and injection of solvents. Removal of the foreign body may be quite challenging requiring imagination and high-level surgical skills. Endoscopic therapy is the standard. The most suitable method is relevant to the size and mobility of the object. In the majority of mobile objects inside the urethra, the mobility is towards the bladder where, after having been pushed, the foreign body can be grasped by forceps or retrieval baskets. Nephroscopes have been used for the retrieval of screws as well as magnetic retrievers for galvanic objects. The YAG laser has also been used lately. In cases where endoscopic procedures are unsuccessful, then open surgery is recommended. For objects stuck in the penile urethra, external urethrotomy is recommended, while for intravesical foreign bodies, a suprapubic cystostomy is the treatment of choice.

Conclusion

A self-inflicted foreign body in the urethra and bladder is a rare situation. Endoscopic manipulation is the preferred first-line treatment and if unsuccessful, open procedures may be necessary.

REFERENCES

Campbell, R.J. 1981. *Psychiatric Dictionary*. 5. New York: Oxford University Press.

- Gonzalzo, M.L., Chan, D.Y. 2003. Endoscopic basket extraction of a urethral foreign body. *Urology*, 62:352. doi: 10.1016/S0090-4295(03)00362-5. [PubMed] [Cross Ref]
- Kenney, R.D. 1988. Adolescent males who insert genitourinary foreign bodies: is psychiatric referral required? *Urology*. 32:127. doi: 10.1016/0090-4295(88)90313-5. [PubMed] [Cross Ref]
- Lee, J.D., Jeng, S.Y., Hsieh, D.S. 1995. Self-introduction of unusual foreign body into the urethra: a case report. *Zhonghua Yi Xue Za Zhi*. 56:440–442. [PubMed]
- Rahman, N.U., Elliott, S.P., McAninch, J. 2004. Self inflicted male urethral foreign body insertion: endoscopic management and complications. *BJU Int*. 94:1051–1053. doi: 10.1111/j.1464-410X.2004.05103.x. [PubMed] [Cross Ref]
- Sukkarieh, T., Smaldone, M., Shah, B. 2004. Multiple foreign bodies in the anterior and posterior urethra. *Int Braz J Urol*. 30:219–220. doi: 10.1590/S1677-55382004000300009. [PubMed] [Cross Ref]
- van Ophoven, A., De Kernion, J. 2000. Clinical management of foreign bodies of the genitourinary tract. *J Urol*. 164:274–287. doi: 10.1016/S0022-5347(05)67342-9. [PubMed] [Cross Ref]
- Wise, T.N. 1982. Urethral manipulation: an unusual paraphilia. *J Sex Marital Ther*. 8:222. [PubMed]
- Wyatt, J., Hammontree, L.N. 2006. Use of holmium YAG laser to facilitate removal of intravesical foreign bodies. *J Endourol*. 20:672–674. doi: 10.1089/end.2006.20.672. [PubMed] [Cross Ref]
