



RESEARCH ARTICLE

TELESCOPIC DENTURE – A TREATMENT MODALITY FOR PRESERVING NATURAL
TEETH AND AUGMENTING RETENTION AND STABILITY

*Bikash Kumar Pattanaik, Girish S Nazirkar, Ahmed Faraz M.A Farooqui
and Prasad Ramesh Padiyar

S.M.B.T Dental College and Hospital, India

ARTICLE INFO

Article History:

Received 23rd July, 2017
Received in revised form
26th August, 2017
Accepted 11th September, 2017
Published online 31st October, 2017

Key words:

Primary coping,
Secondary coping,
Double crown,
Telescopic crown.

ABSTRACT

Objective: This case report aims at highlighting the importance of preserving natural remaining teeth followed by the fabrication of telescopic denture as an alternative to conventional removable dentures. It is easy, less technique sensitive and a cost effective alternative to conventional over dentures and helps to minimize the problems associated with conventional dentures regarding retention and stability.

Background: Telescopic dentures consist of an inner or primary telescopic coping on a root canal treated tooth which is permanently cemented to an abutment and an outer or secondary telescopic coping which is attached to the prosthesis. These copings protect the abutment from dental caries and also provide retention and stabilization of the secondary coping. The secondary coping engages the primary copings to form a telescopic unit and it provides retention and stability to the prosthesis.

Materials and Methods: An impression was made with a polyvinyl siloxane elastomer after the preparation of the abutments, the primary copings were fabricated on the cast which was obtained from the impression. The copings were checked for parallelism using a surveyor incorporated with a micro milling unit. After assessing the parallelism of the coping it was finished and polished ensuring a 0.5mm margin. The fit of the primary copings on the abutments was evaluated, they were cemented with glass ionomer cement. An impression of the cemented primary copings was made for the fabrication of secondary copings, which were attached to the prosthesis.

Conclusion: Telescopic overdentures have better retention and stability as compared to complete dentures, they improve the chewing efficiency and the comfort of the patient and they also decrease the alveolar bone resorption. They can be used as an alternative to conventional overdenture techniques as it does not require attachments, is easy to fabricate less technique sensitive and cost effective.

Copyright©2017, Bikash Kumar Pattanaik et al. This is an open access article distributed under the Creative Commons Attribution License, which permits unrestricted use, distribution, and reproduction in any medium, provided the original work is properly cited.

Citation: Bikash Kumar Pattanaik, Girish S Nazirkar, Ahmed Faraz M.A Farooqui and Prasad Ramesh Padiyar, 2017. "Telescopic denture – A treatment modality for preserving natural teeth and augmenting retention and stability", *International Journal of Current Research*, 9, (10), 59964-59967.

INTRODUCTION

A telescopic denture is a prosthesis which consists of a primary coping fabricated with a 0.5mm margin which is cemented to the abutments in a patient's mouth and a secondary coping which is attached to the intaglio surface of the prosthesis and which fits on the primary coping. It augments the retention and stability of the prosthesis. A telescopic denture as per the GPT definition is also called as an overdenture, which is defined as any removable dental prosthesis that covers and rests on one or more of the remaining natural teeth, on the roots of the natural teeth, and/or on the dental implants. It is also called as overlay denture, overlay prosthesis, and superimposed prosthesis. Telescopic crowns were initially introduced as retainers for the removable partial dentures at the beginning of the 20th century. They were also known as a Double crown, a crown and sleeve coping or as Konuskron (Langer, 2000), a German term that described a cone shaped design. These crowns are an effective means for retaining the RPDs and dentures.

They transfer forces along the long axis of the abutment teeth and provide guidance, support and protection from the movements that dislodge the denture. The double crown systems are usually distinguished from each other by their differing retention mechanisms (Wenz, 1998).

The various types of double crown systems are as follows:

- Telescopic crowns which-achieve retention by using friction mechanism.
- Conical crowns or tapered telescope crowns which exhibit friction only when they are completely seated by using a "wedging effect." The magnitude of the wedging effect is mainly determined by the convergence angle of the inner crown: the smaller the convergence angle, the greater is the retentive force.
- The double crown with a clearance fit (also referred to as a hybrid telescope or a hybrid double crown) exhibits no friction or wedging during its insertion or removal. The retention is achieved by using additional attachments or functional molded denture borders.
- Marburg double crown systems on mandibular molars wherein the copings have friction based retention.

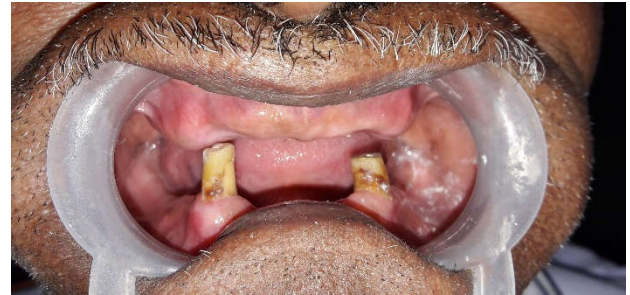The telescopic denture which was supported by the natural teeth gained significant popularity as an alternative to the conventional dentures during the 1970s and the 1980s. The retained teeth that support the overdentures, preserve the bone and they minimize the downward and forward settling of a denture, which otherwise occurs with alveolar bone resorption. The overdenture occlusion is maintained rather than shifting forward to simulate the appearance of a prognathic mandible. The telescopic denture philosophy postulated a transfer of occlusal forces to the alveolar bone through the periodontal ligament of the retained roots. A proprioceptive feedback from the periodontal ligament prevents the occlusal overload and it consequently avoids the residual ridge resorption which is adjacent to the roots and the rest of the ridge, due to excessive forces. They also provide improved functions as compared to the conventional dentures, such as an improved biting force, chewing efficiency and even phonetics. The impairment of these functional parameters which are created by edentulism, reflects the significant role of the periodontal receptors for a sensory feedback and a discriminatory ability from the retained roots. Tooth loss results in loss of the proprioception mechanism that has been a part of the sensory programme throughout life.

Clinical Case Report

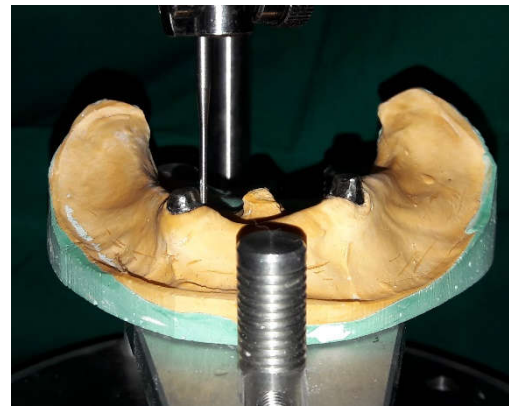
A 71-year old male reported to the Department of Prosthodontics, S.M.B.T dental college and hospital, Sangamner for a prosthetic evaluation. The patient was an existing denture wearer, maxillary complete denture and lower removable partial denture. The patient on examination reported complaints of difficulty in chewing due to ill-fitting lower dentures. Intra-oral examination revealed ill-fitting removable partial denture, poor design and poor fit in spite of a clasp being incorporated in the prosthesis. The bone support of the tooth to be selected as abutments for receiving primary coping was assessed using an intra-oral periapical radiograph, no periapical pathology was seen. The teeth were periodontally sound with no mobility. After abutment selection and radiographic interpretation, intentional root canal treatment of the abutment tooth was done (Table/Fig 1) they were prepared with a tapered round end diamond rotary bur (TR-21 EF series diamond rotary burs) with a chamfer finish line for the primary coping. The finish line was equi-gingival. The long abutments were prepared with tapered walls (2-5°). After the preparation of the abutments, the impression was made by using poly vinyl siloxane elastomeric impression material (Aquasil soft putty and light body, Dentsply) by a double step putty wash technique. The impression was poured using Type IV die stone (GC Fuji Rock EP; GC Europe, Leuven, Belgium) following the water/powder as per the manufacturers' instructions to obtain the cast, on which the primary copings were fabricated.

The wax pattern fabricated for both the abutments was checked on the surveyor for parallelism to not alter the path of insertion of the prosthesis in any way, parallelism of the finished coping was again checked using a surveyor by placing it on the cast and fit of the primary coping was evaluated in the patient's mouth, (Table/Fig 2 a, b) after which they were cemented on the abutments with glass ionomer cement (GC fuji /GC Corp) (Table/Fig 3). The fit of the secondary copings over the primary copings was evaluated in the patient's mouth. The frictional contact between the primary and secondary copings helped in the retention of the prosthesis. Maxillary mandibular

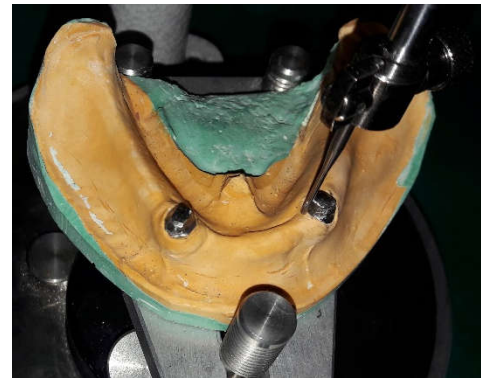impressions were made with alginate, an irreversible hydrocolloid impression material (Tropicalgin) followed by fabrication of record base with cold cure acrylic (DPI-RR cold cure) and wax rims. Tentative jaw relation was recorded to view if there was sufficient inter-arch space for the copings, the denture base and the teeth. (Table/Fig 4).



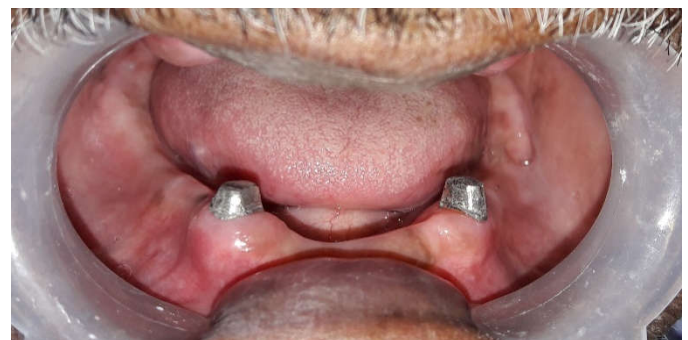Table/Fig. 1. Natural remaining teeth



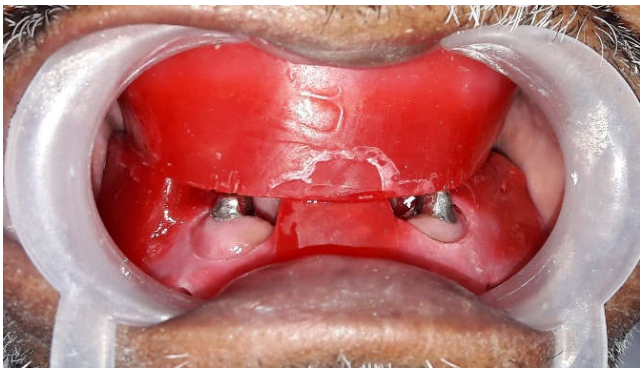
Table/Fig 2 a. Coping fabricated and checked on surveyor for parallelism



Table/Fig. 2b. Coping fabricated and checked on surveyor for parallelism

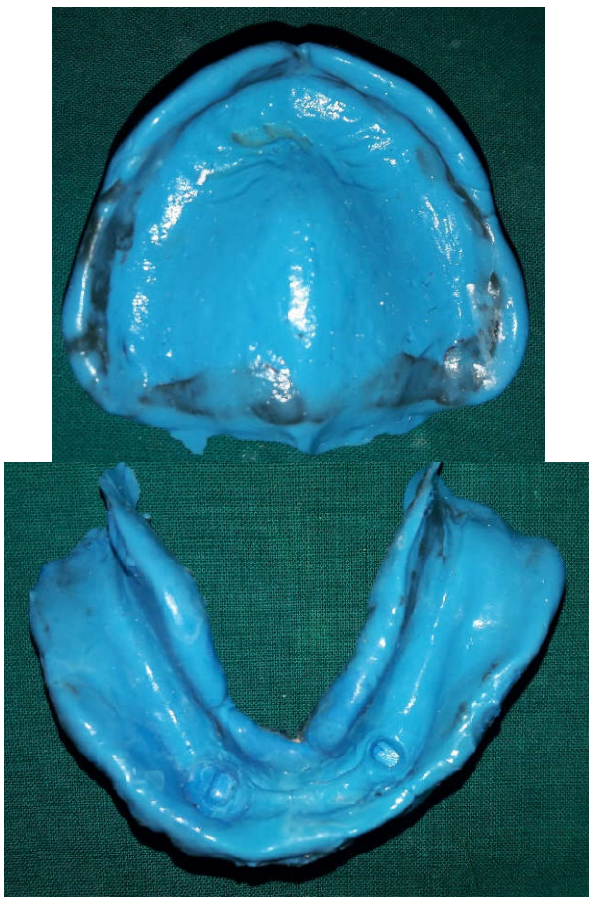


Table/Fig. 3. Primary copings cemented on abutments

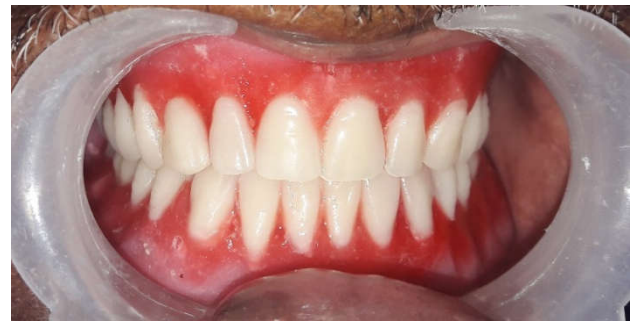

Table/Fig 4. Tentative jaw relation

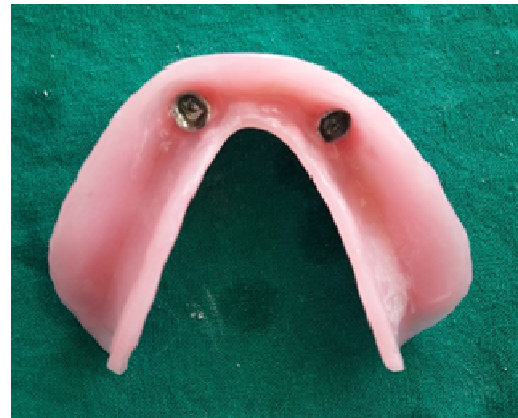Upper lower functional border moulding was done and final impression was made using regular body (Reprosil, Dentsply). (Table/ Fig 5). Casts were fabricated along with record base and occlusal wax rims to record jaw relation. Horizontal and vertical maxillomandibular records were obtained with the record bases and the occlusion rims and these were transferred to a semiadjustable articulator (Hanau wide-vue, whip mix) by using a face bow. The artificial teeth (acry rock) were selected and arranged on the record bases for a trial denture arrangement and they were evaluated intraorally for phonetics, aesthetics, occlusal vertical dimension and centric relation. (Table/ Fig 7) After the wax up, the dentures were processed, finished, polished and delivered to the patient (Table/ Fig 9). The patient was scheduled for follow-up visits every 3 months and he reported no complaints during the 1 year of follow-up. (Table/ Fig 8) shows the secondary copings inside the intaglio surface of the mandibular denture.



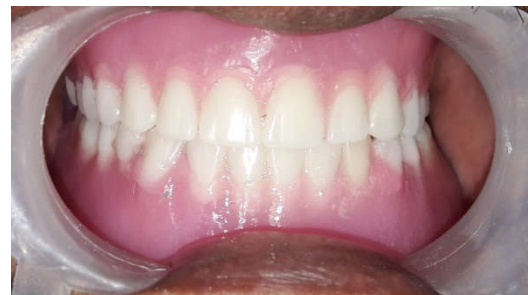Table/ Fig 5. Final impression



Table/ Fig. 6a. Try-in



Table/ Fig 8. Intaglio view of completed mandibular denture with secondary coping



Table/ Fig. 9c. Intraoral view of dentures

DISCUSSION

Telescopic crowns have been used mainly in RPDs to connect dentures to the remaining dentition (Langer, 1981), but these can be used effectively to retain complete dentures which receive their support partly from the abutments and partly from the underlying residual tissues. Telescopic crowns have also been used successfully in RPDs and FPDs, supported by endosseous implants, in combination with the natural teeth, which includes the overdentures (Laufer, 1998 and Besimo, 1994). The retention and the stability of the telescopic denture are directly related to the number and the distribution of the abutments along the dental arch and the taper of the wall of the primary coping. The tapered configuration of the contacting walls generates a compressive inter surface tension. The tension should be sufficiently strong enough to sustain the prosthesis in its place. An increase in the tapering of the coping walls reduces the retention between the copings. The smaller the degree of the taper, the greater is the frictional retention of the retainer. In case of the abutments with short clinical height, the walls should be kept parallel or the taper of the wall should be reduced (2-5°) to improve the retention. The taper of the walls of the primary coping can be adjusted to a predetermined

angle, according to the special requirements of each patient. Telescopic crowns can also be used as effective direct retainers for RPD (Langer, 1980). Their degree of retention can be planned to suit different situations by modifying their designs. The amount of intersurface friction depends on the configuration of the taper angle and the area of the surface contact. Telescopic crowns can also be used as indirect retainers to prevent the dislodgement of the distal extension base away from the edentulous ridge. The resistance to this movement is built-in in rigid telescope retainers with cylindrical or conical primary copings, which are designed with no free space between both the components. One of the main advantages of the telescopic retainers is that, being pericoronal devices, they transmit the occlusal forces in the direction of the long axes of the abutment teeth. This has proven to be the least damaging application force. The lateral forces exert traumatic pressure on the abutments. Careful assessment of the interarch space is very important for the successful fabrication of the telescopic dentures. Sufficient space must be present to accommodate the primary and secondary copings, to have a sufficient denture base thickness to avoid fracture, space for the arrangement of the teeth to fulfill the esthetic requirements and to have an inter-occlusal gap. The space consideration usually requires intentional root canal treatment of the abutments (Preiskel, 1996). The selected abutments should be periodontally sound with adequate bone support and no/minimal mobility. There should be at least one healthy abutment in each quadrant. An even distribution of the abutment in each quadrant of the arch is preferable for better stress distribution and for increased retention and stability of the prosthesis.

The interocclusal gap/ interarch distance should be ≥ 10 mm, in order to have sufficient space for the copings, denture base, teeth placement and adequate closest speaking space. The contours and the degree of taper of the outer aspect of the primary coping determine the path of insertion and the amount of retention of the prosthesis. The retention varies inversely with the taper of the coping. Even copings of minimal taper (approximately 5 degrees) require a height of about 4mm to achieve a significant retention (Langer, 1981). The height and size of the inner coping also influence the retention. The essential requirements for the long service of the telescopic prosthesis are, to provide adequate height of the vertical walls (at least 4mm), sufficient thickness of the copings (never less than 0.7mm for each casting) and a taper of around 6°. Adaptation to the conventional removable complete dentures is a complex learning process. Patients who have originally adapted to wearing complete dentures may become maladaptive with time, due to the continual residual ridge resorption, intra oral physiological changes and the development of an altered muscle pattern. It has been found that the telescopic dentures which are supported by the roots of natural teeth have more predictable prosthodontic outcomes because of increased support, stability and retention and decrease in rate of the residual ridge resorption. Patients with natural teeth can masticate more effectively than when they are edentulous. This is due in part to their degree of accuracy in the functional jaw movements, which are possible with a better neuromuscular feedback mechanism from the periodontal ligaments. The proprioceptive nerve endings in the periodontal ligaments feed information into the neuromuscular mechanism. In the absence of teeth, this information is missing.

By retaining the roots of some teeth, it may be possible to use this proprioceptive apparatus with complete dentures. If this is so, a higher degree of accuracy in the jaw movements and the masticatory performance could result. By this means, teeth that normally might have a very short life span can be retained for long periods of time. This can thus benefit the patients in their denture function. It has been found that telescopic dentures have better retention, stability, support and chewing efficiency as compared to the conventional complete dentures and also, there is a decrease in the rate of the residual ridge resorption because of proprioception, better stress distribution and the transfer of compressive forces into the tensile forces by the periodontal ligament, which effects rate of bone remodeling. A clinical study which was conducted by Bo Bergman et al on conical crown retained dentures, concluded that most of the patients were very satisfied with the restorations, both functionally and aesthetically and it found their chewing comfort to be better after the treatment with the conical crown retained dentures (Bergman, 1996). Complete denture fabrication for maladaptive elderly patients becomes difficult. Therefore, they are the group of patients who will benefit most with telescopic dentures. Overdentures which are supported and/or retained with a few remaining teeth or implants can be a predictable treatment that will fulfill most of the demands of the elderly denture patients.

Conclusion

Tooth-supported, removable over dentures with telescopic crowns may be considered as a good alternative to the conventional removable dentures, because they provide better retention, stability, support, stable occlusion, decrease in the forward sliding of the prosthesis and better control of the mandibular movements because of the proprioception feedback which increases the chewing efficiency and even phonetics, as compared to the conventional complete dentures. Also, the rate of the residual ridge resorption was decreased because of the transfer of compressive forces into the tensile forces by the periodontal ligament and better stress distribution.

REFERENCES

- Bergman, B., Ericson, Á., Molin, M. 1996. Long-term clinical results after treatment with conical crown-retained dentures. *Int J Prosthodont.*, 9:533–39.
- Besimo, C., Graber, G. 1994. A new concept of overdentures with telescope crowns on osseointegrated implants. *Int J Periodontics Restorative Dent.*, 14:486-95.
- Langer, A. 1980. Telescope retainers and their clinical applications. *J Prosthet Dent* 44:516-22.
- Langer, A. 1981. Telescope retainers for removable partial dentures. *J Prosthet Dent.*, 45:37-43.
- Langer, Y., Langer, A. 2000. Tooth-supported telescopic prostheses in compromised dentitions: A clinical report. *J Prosthetic Dent*, Aug; 84 (2): 129-32.
- Laufer, B.Z., Gross, M. 1998. Splinting osseointegrated implants and natural teeth in the rehabilitation of partially edentulous patients. Part II: principles and applications. *J Oral Rehabil.*, 25:69-80.
- Preiskel, H. W. Overdenture made easy – a guide to implant and root supported prostheses. page 61.
- Wenz, H.J., Lehmann, K.M. 1998. A telescopic crown concept for the restoration of the partially edentulous arch: the Marburg double crown system. *Int J Prosthodont* 11:541–50.