



## RESEARCH ARTICLE

### PRIMARY DUODENAL ADENO CARCINOMA: A CASE REPORT AND LITERATURE REVIEW

**\*Sudheer Kanchodu and Manjusha Madhusudan Litake**

Department of General Surgery, BJ Government Medical College, Pune, Maharashtra

#### ARTICLE INFO

##### Article History:

Received 26<sup>th</sup> September, 2017  
Received in revised form  
23<sup>rd</sup> October, 2017  
Accepted 20<sup>th</sup> November, 2017  
Published online 31<sup>st</sup> December, 2017

##### Key words:

Primary duodenal adeno carcinoma,  
Whipple's.

Copyright © 2017, Sudheer Kanchodu and Manjusha Madhusudan Litake. This is an open access article distributed under the Creative Commons Attribution License, which permits unrestricted use, distribution, and reproduction in any medium, provided the original work is properly cited.

Citation: Sudheer Kanchodu and Manjusha Madhusudan Litake, 2017. "Primary duodenal adeno carcinoma: A case report and literature review", *International Journal of Current Research*, 9, (12), 63264-63266.

#### ABSTRACT

Although uncommon, most common site for adenocarcinoma of small bowel is duodenum. In duodenum, it is found most commonly in second part secondary to a villous adenoma in periampullary region. Carcinoma of third and fourth part is extremely rare. We had 60 year old lady presented with history of vomiting following food intake for 15 days and generalised weakness and loss of weight since 6 months. Patient was diagnosed adenocarcinoma duodenum in third and fourth part with regional lymph node metastasis via CT scan, OGD scopy and biopsy. Patient underwent a curative resection by Whipple's procedure with lymph node excision.

#### INTRODUCTION

Malignancy of small bowel is very rare, of which duodenal adeno carcinoma accounts for 0.35% of all GI tumors and 37% of small bowel malignancy. Only 15-35% of the patients present with obstruction due to tumor infiltration and adhesion (Sabiston textbook of surgery). GI bleed manifests as anemia. Treatment is determined by location of the tumor. Complete resection with negative margin with resection of loco-regional lymph node is mandatory for good five year survival. Pancreaticoduodenectomy is the standard of care for tumor in the second part and also infiltrating tumor of proximal and distal duodenum (Markogiannakis *et al.*, 2008). Segmental resection can only be attempted in tumor of third and fourth part provided there is no local infiltration (Nakano *et al.*, 2013). Our patient had tumor that was obstructing the lumen as well as infiltrating the wall with involvement of regional lymph node and metastasis to head of pancreas, not involving the major vessels, thus Whipple's procedure was done.

#### CASE REPORT

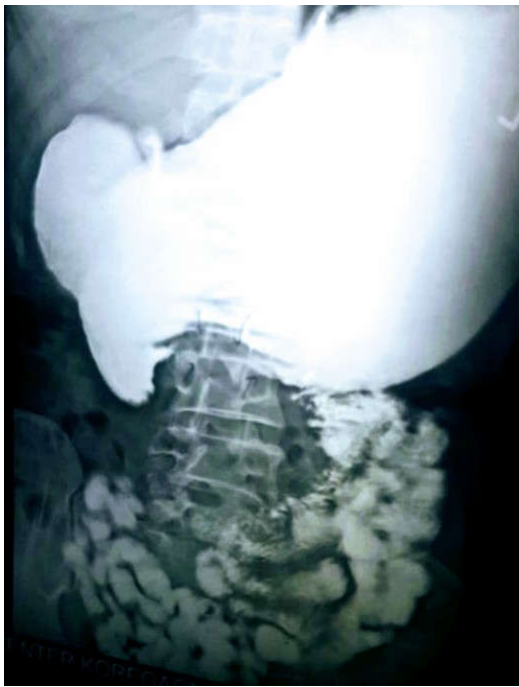60 year old lady presented with vomiting after taking food since 15 days associated generalised weakness and weight loss. Barium study revealed narrowing of lumen in junction of third and fourth part of duodenum. OGD scopy revealed villous mass nearly occluding the duodenum in third part of duodenum nearly occluding the lumen.

\*Corresponding author: Sudheer Kanchodu,  
Department of General Surgery, BJ Government Medical College, Pune, Maharashtra

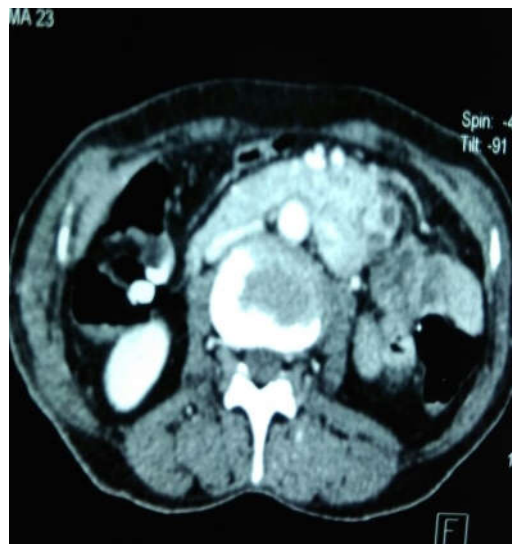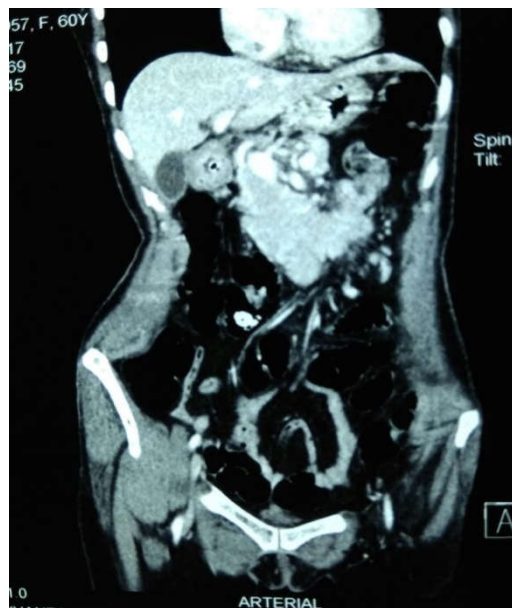Biopsy was taken, suggestive of duodenal adenocarcinoma. Contrast CT abdomen revealed short segment homogeneously enhancing, circumferential, asymmetric wall thickening involving fourth part of duodenum and proximal jejunum with few adjacent enlarged lymph nodes with central area of necrosis likely suggestive of infective more than neoplastic etiology. Patient was given TPN and albumin preoperatively for building the nutrition and then was taken for curative resection. Intra-operatively pancreatic head appeared to be involved by the mass and was resectable so a Whipple's procedure was done with regional lymph node excision. Final histopathology report came out to be duodenal adeno carcinoma with metastasis to regional lymph node and pancreatic head, margins free of tumor. Unfortunately patient succumbed on post operative day 12 due to ventilator associated pneumonia and malaria.

#### DISCUSSION

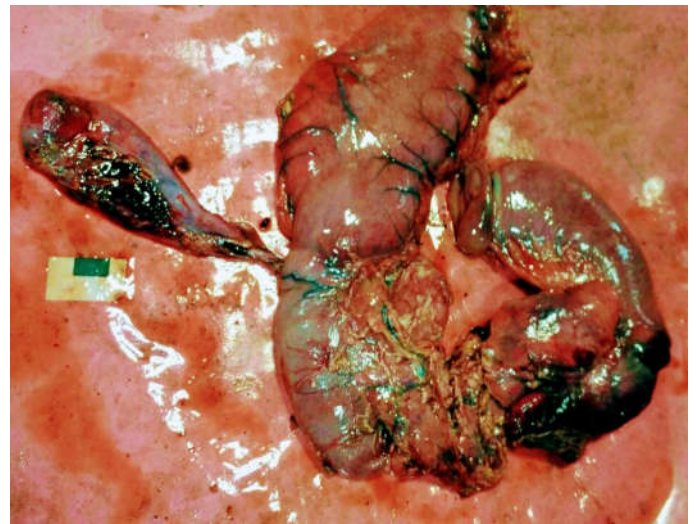
Small intestine malignancy itself being very rare, duodenal adeno carcinoma presents late with a latency of 2-12 months poses great challenge in the diagnosis (Sabiston textbook of surgery). Neuroectodermal tumors and adenocarcinoma account for the majority of all small bowel malignancy, 37% each (Sabiston textbook of surgery). It accounts for only 0.35% of GI malignancies. Predisposing factors are FPC, Gardner's syndrome and duodenal polyps (Markogiannakis *et al.*, 2008). Duodenal adenocarcinoma presents earlier compared to distal small bowel carcinoma and thus has good prognosis. Most common presenting features are pain in abdomen and weight loss.



Barium study



CT Scan



Photograph of the specimen

15 to 35% of the cases present with obstruction due to tumor infiltration and Adhesion as in our case (Sabiston textbook of surgery). Esophagogastroduodenoscopy and gastrointestinal barium radiography detect 88.6 and 83.3% of tumors (Zhang *et al.*, 2011), respectively. Even though they are effective in screening this rare tumor, their location is often inaccessible to endoscopic viewing, which may result in a failure to diagnose them endoscopically (Chung *et al.*, 2011; Tocchi *et al.*, 2003; Pozzetto *et al.*, 2002). USG is particularly useful for detecting duodenal carcinoma and determining vascular invasion. Lesions appear as irregularly marginated hypoechoic masses, although tumors smaller than 2 cm may not be detected. Thus, US can contribute significantly to the choice of the endoscopic procedure and patient management (Ishida *et al.*, 2001). Contrast-enhanced CT is a useful tool in the diagnosis of malignancy and resectability, with a sensitivity of 94% and a specificity of 82%, although, tumors smaller than 2 cm may not be detected in CT scan also (Markogiannakis *et al.*, 2008; Sista *et al.*, 2012). Features indicative of malignancy are an exophytic or intramural mass, central necrosis, and ulceration, whereas an entirely intra-luminal location indicates a benign tumor (Markogiannakis *et al.*, 2008). Vascular encasement, invasion of contiguous organs other than the head of the pancreas, distal lymphadenopathy, or metastasis precludes curative resection (Markogiannakis *et al.*, 2008).

Early-stage duodenal carcinoma should be considered for endoscopic mucosal resection (Nakano *et al.*, 2013). Endoscopic polypectomy using information from endoscopic US would appear to be a safe and effective method for the diagnosis and treatment of pedunculated early duodenal cancers (Shinoda *et al.*, 2010). Surgical treatment is then indicated for more advanced disease with intention of R<sub>0</sub> resection (Sabiston textbook of surgery). Worldwide, there is no general agreement as regards the optimal surgical procedure for the treatment of primary non ampullary adenocarcinoma of the duodenum, especially for early-stage disease. Some surgeon's prefer local excision or segmental resection whereas others perform duodenopancreatic resection, even in the case of early stage duodenal cancer, in order to avoid tumor recurrence, as with Whipple's procedure adequate curative resection can be achieved. Amongst the surgical procedures available, pancreaticoduodenectomy is recommended for tumors located in the 1st and 2nd portion of the duodenum, and segmental resection may be appropriate for selected patients,

especially for tumors of the distal duodenum (Han *et al.*, 2010). In contrast, duodenocephalopancreatectomy remains the standard treatment for adenocarcinomas of the 1st and 2nd portion of the duodenum. Patients with locally advanced (N1) tumors (stage III) can benefit from this aggressive approach with good long-term results (Nakano *et al.*, 2013). Some studies have reported good survival results following segmental duodenectomy, despite limited lymphadenectomy occurring during the surgical procedure, and considerably lower postoperative morbidity (Nakano *et al.*, 2013). Segmental duodenectomy is the preferred resection method for patients with adenocarcinoma of the 3rd and 4th portions of the duodenum (Nakano *et al.*, 2013). In advanced disease, and particularly in duodenal obstruction, palliative resection, gastrojejunal bypass or duodenal stents may be indicated. The role of adjuvant chemotherapy is still unclear, with some studies showing important statistical benefits as regards medium- and long-term survival. The regimens used in the trial are FOLFOX (oxaliplatin, 5-FU, and leucovorin) and FOLFIRI (irinotecan, 5-FU, and leucovorin) (Sabiston textbook of surgery). In our patient, she had adenocarcinoma in third and fourth part with intra-operative finding suggestive of tumor involving pancreatic head, thus we had to proceed with Whipple's the tumor was resectable.

## Conclusion

This is to report case of primary duodenal adeno carcinoma because of its rarity. It is challenging in diagnosis, in spite of availability of modern diagnostic modality as in our case it can mimic infective etiology which can change entire treatment plan in a country like India where tuberculosis also come to picture. Thus it requires high index of suspicion and aggressive approach in diagnosis of the disease.

## REFERENCES

- Chung, W.C., Paik, C.N., Jung, S.H., Lee, K.M., Kim, S.W., Chang, U.I., Yang, J.M. 2011. Prognostic factors associated with survival in patients with primary duodenal adenocarcinoma. *Korean J Intern Med.*, 26:34–40.
- Han, S.L., Cheng, J., Zhou, H.Z., Zeng, Q.Q., Lan, S.H. 2010. The surgical treatment and outcome for primary duodenal adenocarcinoma. *J Gastrointest Cancer*, 41:243–247.
- Ishida, H., Konno, K., Sato, M., Naganuma, H., Komatsuda, T., Yamada, N., Hamashima, Y., Ishida, J., Segawa, D., Watanabe, S. 2001. Duodenal carcinoma: sonographic findings. *Abdom Imaging*, 26:469–473.
- Markogiannakis, H., Theodorou, D., Toutouzas, K.G., Gloustanou, G., Katsaragakis, S., Bramis, I. 2008. Adenocarcinoma of the third and fourth portion of the duodenum: a case report and review of the literature. *Cases J.*, 1:98.
- Nakano, T., Sugawara, K., Hirau, K., Hirano, Y., Hashimoto, M., Kaiho, T., Ohuchi, N. 2013. Primary adenocarcinoma of the fourth portion of the duodenum: 'a case report and literature review'. *Int J Surg Case Rep.*, 7:619–622.
- Pozzetto, B., Guarino, G., Tonello, C., Liguori, G. 2002. [Treatment of adenocarcinoma of the duodenum: presentation of 4 clinical cases and review of the literature] *Chir Ital.*, 54:195–201. [PubMed]
- Sabiston textbook of surgery, duodenal adeno carcinoma, first south east asian edition, vol 2, pg 1276-77.
- Shinoda, M., Makino, A., Wada, M., Kabeshima, Y., Takahashi, T., Kawakubo, H., Shito, M., Sugiura, H., Omori, T. 2010. Successful endoscopic submucosal dissection for mucosal cancer of the duodenum. *Dig Endosc.*, 22:49–52.
- Sista, F., De Santis, G., Giuliani, A., Cecilia, E.M., Piccione, F., Lancione, L., Leardi, S., Amicucci, G. 2012. Adenocarcinoma of the third duodenal portion: case report and review of literature. *World J Gastrointest Surg.*, 4:23–26.
- Tocchi, A., Mazzoni, G., Puma, F., Miccini, M., Cassini, D., Bettelli, E., Tagliacozzo, S. 2003. Adenocarcinoma of the third and fourth portions of the duodenum: results of surgical treatment. *Arch Surg.*, 138:80–85. [PubMed]
- Zhang, S., Cui, Y., Zhong, B., Xiao, W., Gong, X., Chao, K., Chen, M. 2011. Clinicopathological characteristics and survival analysis of primary duodenal cancers: a 14-year experience in a tertiary centre in South China. *Int J Colorectal Dis.*, 26:219–226.

\*\*\*\*\*