



RESEARCH ARTICLE

TREATMENT FOR SKIN OF RENAL CISTS

Giorgio Maria Paolo Graziano, Antonio Di Cataldo and Antonino Graziano

¹Research fellow University of Catania Italy, Dpt Sciences Medical of Surgery and Technologies Advanted

^{2,3}University of Catania, Medical School Italy, Dpt Sciences Medical of Surgery and Technologies Advanted
via S Sofia 86 cap 95125 Catania

ARTICLE INFO

Article History:

Received 22nd August, 2017

Received in revised form

14th September, 2017

Accepted 20th October, 2017

Published online 30th November, 2017

Key words:

Sclerotherapy,
Percutaneous,
Cyst treatment.

ABSTRACT

Introduction: They represent the most common kidney mass in the adult; These are true cysts provided with a wall consisting of a monolayer epithelium and containing a liquid most similar to urine. Typically spherical and unilocular are present. They are equipped with a fibrous collagen tissue capsule that sometimes has calcium deposits. They are considered to be acquired. These cysts are often cortical, but there are also midollars. They generally do not communicate with renal pelvis. More often the size varies from 0.5 to 1 cm, but there can be cysts of 3 or 4 cm. The therapeutic approach to these cysts may be variable. Considering the reduced possibility of a neoplastic form, the surgical approach is uncommon and is therefore reserved for those cases where, due to today's diagnostic methods, there is certainty of the existence of a neoplasm. In this study we present percutaneous treatment with its indications and evaluations on the therapeutic efficacy of the method.

Materials and Methods: From January 2017 to Nov. 2017 at the AOU Policlinico University of Catania studies, we received our observation n 10 middle age patients 67 (range 65-69) with renal cystic disease. These cases presented a symptom characterized by severe pain at the side of sn (70%) or ds (30%), nausea of periodic food vomiting, with episodes of microematuria, and hypertension. Transcutaneous stinging ecoguidated bite, which in most simple medium-sized cysts were aspirated (60% of cases); and only in cases where some cysts were of a size > 10cm (20% of cases) a sclerosing agent or a contrast medium with cysts of size < 4 cm is injected into the cavity to prevent recurrence. Unfortunately, sometimes this was not enough and therefore it was necessary to use open or laparoscopic surgery with Decortication (20% of cases). No drainage was performed with catheterization because of the infectious risks that this procedure can cause.

Results: 60% of the cases treated with peritoneal and cystic transplants were <100mm cytological examination excluded the lesion malignancy, and were discarded after 2 hours of treatment, and with antibiotic therapy for 3.4g.

Discussion: The first advantage of this peritoneal treatment of simple kidney cysts is to undertake ultrasound therapy by emptying voluminous renal cysts even in critical stages, then injecting alcohol or contrast media to make sclerosing cysts.

Conclusions: The aim of this study was to evaluate the efficacy of percutaneous treatment with aspiration needle, under ultrasound (US) or under CT guidance (computerized tomography), in symptomatic symptomatic renal cysts, also of considerable size > 13cm. Percutaneous treatment of symptomatic simple cysts represents in agreement with many authors the gold standard for this pathology.

Copyright © 2017, Giorgio Maria Paolo Graziano et al. This is an open access article distributed under the Creative Commons Attribution License, which permits unrestricted use, distribution, and reproduction in any medium, provided the original work is properly cited.

Citation: Giorgio Maria Paolo Graziano, Antonio Di Cataldo and Antonino Graziano, 2017. "Treatment for skin of renal cists", *International Journal of Current Research*, 9, (11), 61178-61181.

INTRODUCTION

They represent the most frequent kidney mass in the adult; These are true cysts provided with a wall consisting of a monolayer epithelium and containing a liquid most similar to urine. Typically spherical and unilocular are present. They are equipped with a fibrous collagen tissue capsule that sometimes has calcium deposits. They are considered to be acquired. These cysts are often cortical, but there are also midollars. They generally do not communicate with renal pelvis. More often the size varies from 0.5 to 1 cm, but there can be cysts of 3 or 4 cm. They are most commonly found in adults. They are mostly asymptomatic and constitute an occasional ultrasound

finding; sometimes they can cause lumbar pain, hematuria, hypertension and the most voluminous can be palpable. (Griffiths *et al.*, 1975; Dalla Palma *et al.*, 2005) The few cases of hypertension attributed to the presence of a renal cyst sometimes disappeared after aspiration of the same, in these cases in fact developed hyperinemia due to compression of the vessels adjacent to the cyst, with selective renal ischemia and hence increased production of renin. A simple cyst that loses some of its peculiarities can have: an alteration of the shape (no spherical or oval) and the presence of small subtle and fine eches inside the ecotomographic examination. However, a cyst that can go to hemorrhage (possible hemorrhage) to infection (sometimes pain and fever) or rupture (pain, abdominal resection, hematuria) or the formation of a neoplasm from the epithelium of the cyst (exceptionally) such as M. von Hippel-Lindau syndrome includes cerebellar and retinal

*Corresponding author: Giorgio Maria Paolo Graziano,
Research fellow University of Catania Italy, Dpt Sciences Medical of Surgery and Technologies Advanted

hemangioblastoma, cysts and pancreatic carcinoma, cysts and kidney tumors. This disease is transmitted as a dominant autosomal character and is usually manifested in the 3rd 4th decade of life with disorders affecting the central nervous system and the visual system. Or tuberous sclerosis complex disease characterized by the presence of amartomatosis in the skin, brain, retina, skeleton, lungs and kidneys. The disease is transmitted with dominant autosomal character. Finally, there is another non-hereditary malformation, the cystic polycystic kidney characterized by the presence of cysts of varying magnitude with the reduction or even disappearance of renal parenchyma and constituting one of the most frequent causes of abdominal masses in the infant. It is generally unilateral. Renal cysts may be inherited from developmental anomalies or acquisitions. About the pathogenesis of these abnormal renal formations theories in the past have been different (De Sanctis *et al.*, 1998; Bakker *et al.*, 1998). To date, we can summarize the origin of the cysts with the following pathogenetic theories:

- o 1) tubular obstruction resulting in increased intratubular pressure;
- 2) formation of an abnormal and highly deformable tubular basal membrane;
- 3) or laproliferation of new cellular elements and regeneration of a new tubular basal membrane.

An important role is the hyperplasia of the tubular epithelium, focal or diffuse, followed by the extension of the inner surface of the cysts. In addition, the cyst cavity is always filled with liquid, so another fundamental requirement is the development of a new secretory mechanism (Graziano Giorgio Maria Paul and Anthony Di Cataldo, ?; Giorgio Maria Paul Graziano *et al.*, 2016). It is not yet clear, however, which of the two mechanisms comes first. The therapeutic approach to these cysts may be variable. In view of the reduced possibility of a neoplastic form, the surgical approach is uncommon and is therefore reserved for those cases where, thanks to today's diagnostic methods, there is certainty of the existence of a neoplasia. The purpose of this study is that to evaluate the percutaneous treatment of cysts and sclerotherapy with its indications and evaluations on the therapeutic efficacy of the method.

MATERIALS AND METHODS

From January 2017 to November 2017 at the AOU Clinical Hospital of the University of Catania, our observation received n 10 mid-age patients 67 (range 65-69) with renal cyst disease. These cases presented a symptom characterized by severe pain at the side of sn (70%) or ds (30%), nausea of periodic food vomiting, with episodes of microematuria, and hypertension. Instrumental Investigations: Ultrasound is the main non-invasive diagnostic study in abnormal renal abnormalities and cystic diseases, (Fig. 1) which instrumental diagnosis was diagnosed with the presence of large right renal cysts (in 30% of cases) and sn (in 70 % of cases) with an average cross-sectional diameter > 10 to 13cm; Malformations were occasional finds. In relation to the high volume of cystic formations, it was not possible to be certain of the benign nature of the lesion found for which the diagnosis was further investigated, requiring a differential diagnosis with neoplastic formations, thus using diagnostic techniques such as TAC (Fig. 2) and magnetic resonance imaging. These examinations described the massive cystic formations occupying the middle and lower right kidney (65mm for 130mm vol max) (30%), or sn, (70% 40mm -100mm vol max) by pointing and dislodging the corresponding pelvic calico system and the lumbar ureter, there were also slight calcifications in the context and a slender slit in the caudal portions. Both methods were also associated

with a cytological and / or histological examination during transubstitution of ecoguidated transcutaneous puncture. Treatment in most simple medium medium cysts was aspirated (60% of cases); and only in cases where some cysts were in size > 10cm (20% of cases) a sclerosing agent or alternatively a contrast medium in the presence of cysts whose size was <4 cm was injected into the cavity in order to prevent it the recurrence. Unfortunately, sometimes this was not enough, so it was necessary to use open or laparoscopic surgery with Decortication (20% of cases). No drainage with catheterization was carried out due to the higher risk of infection that this procedure may cause.

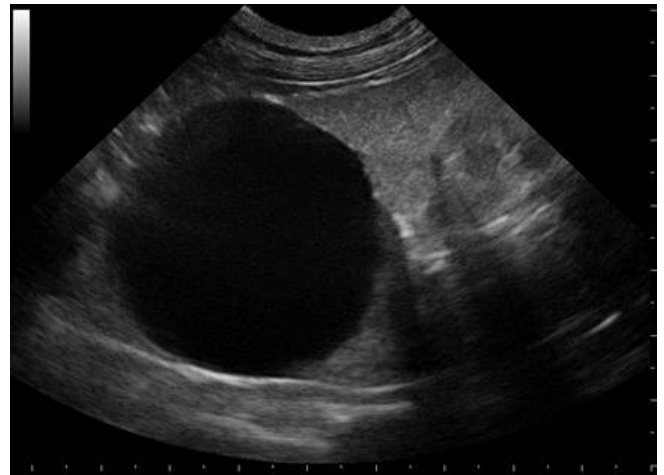


Fig. 1. US renal abnormalities and cystic diseases

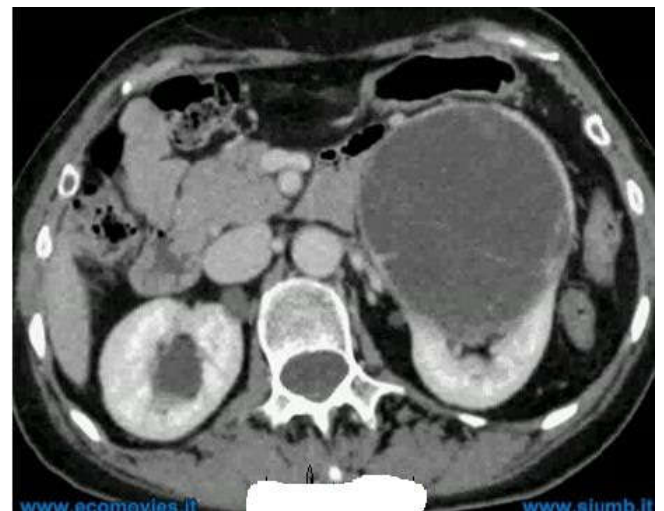

Fig. 2. TAC renal cystic diseases

RESULTS

The use of renal ultrasonography in the first approach of patients with newly diagnosed cystic renal disease and their follow-up was due to the ability of the method to obtain information on the presence / absence of the kidneys in both the normal and ectopic sites; 2) on renal morphological assessment; 3) on the measurement of interpolated and transverse diameters 4) with a measurement of thickness and parenchymal ecogenicity, 5) A renal morphological assessment to identify occupational injuries (cysts and neoplasms), 6) an evaluation of the presence of lithiasis; 7) An ecocolor-power evaluation of renal vascularization with regard to symptomatology 8) An evaluation of Intrarenal Resistance

Indices (IR) of interlobular and / or arciform arteries; 9) A guide to renal abnormal kidney disease is in the course of kidney disease and solid occupational injury injury.) 10 Finally, a guide to kidney puncture is underway in hydronephrosis as well as in cysts. In the differential diagnosis of neoplasia, TAC and MRI defined the benign nature of the lesion (80% of the cases treated) by describing precisely the minute calcifications in the context and a subtle disruption in the caudal portions. In the remaining 20%, laparoscopic surgery with the decortication of cysts proved to be fairly easy with 40 minutes of average execution time confirming histologic examination of the absence of neoplasia. (Fig. 3) Finally, in the presence of renal cysts > 13 cm for Possible presence of flogic adherence preventing laparoscopic access to an open surgery with removal of cysts became a necessity procedure. The outcome of the histological examination confirmed that he was also free of neoplasia. 60% of the cases treated with peritoneal and cystic transplants were <100mm cytological examination excluded the lesion malignancy, and were discarded after 2 hours of treatment, and with antibiotic therapy for 3.4g. in 40% cases where the cyst was > 10 cm thick with hypertension, a decrease in pressure peaks was normalized in the 10 days following the emptying of the cysts. single sclerotherapy treatment with 95% alcohol for 40-60 minutes was performed in simple symptomatic renal cysts that included this group of patients. The method (aspiration without drainage) was chosen independently of the size and depth of the cyst. The cyst volume reduction was 100%, in cases under US guidance and 93.3% in CT-guided methods. All procedures have been successfully performed. No major complications or recurrences were reported to a semi-annual follow-up.

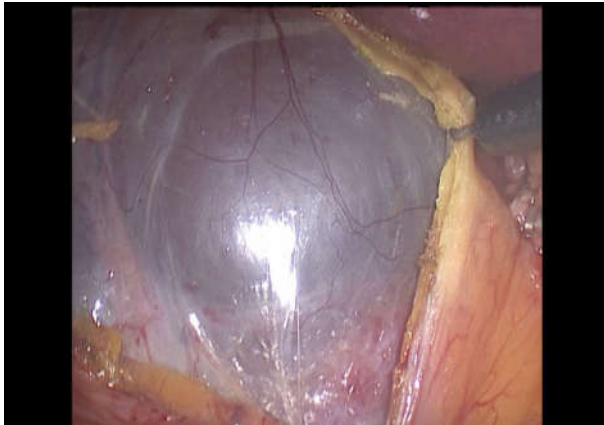


Fig. 3. Laparoscopy cyst renal

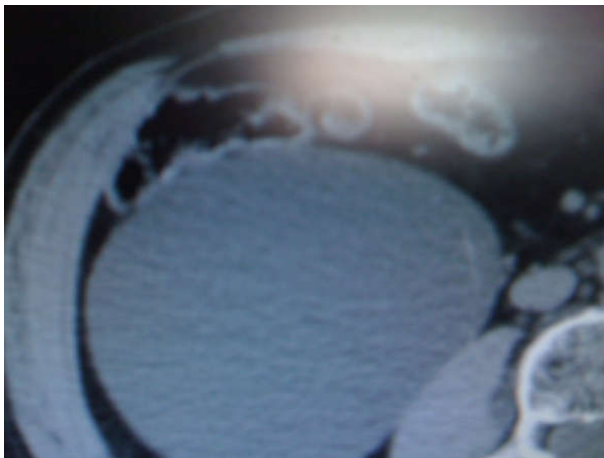


Fig. 4. TAC renal cystic diseases

DISCUSSION

In the first advantage of this peritoneal treatment of simple kidney stones, this procedure is performed under the guidance of the ultrasound, with the emptying of bulky renal cysts even in the critical phase, then injecting alcohol doses or the contrast medium for the purpose of make the sclerosis cyst. Thus, the pressure exerted by the cyst on the kidneys with the displacement of the organ and the ureter and its ischemic vascular suffering, is effectively eliminated, with the resumption of uniform renal perfusion and the consequent resumption of functionality renal failure that was partially compromised, as well as preventing possible complications such as infection, and bladder bleeding (Giorgio Maria Paolo Graziano *et al.*, 2016; Giorgio Maria Paolo Graziano *et al.*, 2016; Graziano Giorgio Maria Paolo *et al.*, 2016). The most obvious advantages with percutaneous treatment of renal cysts are due to the achievement and reduction of peripatetic risks and complications due to the failure to perform open or laparoscopic surgery with less tissue damage, less pain for patients, beyond repeated use of the method. Limiting the use of both open and laparoscopic surgery to those cases where image diagnostics does not rule out the possibility that cysts may mask a cancer. Percutaneous treatment in accordance with a nerve AA is confirmed as the "gold standard" method for treating simple kidney cysts, including 13cm volume (Giorgio Maria Paolo Graziano *et al.*, 2016; Giorgio Maria Paul Graziano *et al.*, 2016; Paul Graziano *et al.*, 2016). The disadvantages of this simple treatment of simple kidney cysts is the high recurrence rate of cysts, reported in the literature, which characterizes the method and predisposes how this treatment is repeated several times. However, in our experience a 95% sclerotherapy for 40-60 minutes was performed in symptomatic symptomatic renal cysts of both medium-sized and voluminous cysts. At the semestrial follow-up we have not had any recurrence *yet* although it is premature to express the results obtained, a first indication tells us how prolonging the duration of such sclerotherapy can result in a success with a reduction in recurrences (Giorgio Maria Paul Graziano, 2016; Hricak and Lieto, 1983). They also associate with some complications and side effects: first and lasting perutaneous treatment, there is the possibility of major bleeding up to the formation of hematoma even if severe, whose risk increases or decreases when you have or do not high-definition eodoppler capable of visualizing the passage of the translucent echo-guided needle. The second complication is due to the infection, which we avoided because we do not use the cystic drainage, as well as establishing an antibiotic prophylaxis for gram-negative. In order to avoid the complication of high blood pressure, the patient must first be evaluated holter 36 hours prior to percutaneous treatment in addition to the renin dosage (Derchi *et al.*, 1994; Partik *et al.*, 2002; Brandt *et al.*, 1982; Emamian *et al.*, 1995). And in agreement with cardiologists, if the patient had elevated renal hypertension, he proceeded to apply a therapeutic protocol that provides a combined use of sartans, beta-blockers, and diuretics. Ultimately, and not less severe, is the complication of hematuria. Ematus that will dissolve several days, even though it causes anxiety or kidney colic, and that, with the passing of time, it becomes microscopic.

Conclusion

The aim of this study was to evaluate the efficacy of percutaneous treatment with suction needle, under ultrasound

(US) or under CT guidance (computerized tomography), in symptomatic symptomatic renal cysts, also of considerable size > 13cm. Percutaneous treatment of symptomatic simple cysts represents in agreement with many authors the gold standard for this pathology. Representing an effective and safe method. However, in the presence of anatomic and vascular abnormalities or following a clinical history that presents inflammatory processes in the renal site of the cyst that may be a difficulty in accessing the renal loggia or in the presence of suspicious diagnostic neoplasms that the cyst may conceal and the image diagnostic has not clarified, the indication for treatment with open surgery remains

REFERENCES

- Bakker J, Olree M, Kaatee R *et al.* 1998. In vitro measurement of kidney size: comparison of ultrasonography and MRI. *Ultrasound in Medicine & Biology*, 24(5):683-8
- Brandt TD, Neiman HL, Dragowski MJ *et al.* 1982. Ultrasound assessment of normal renal dimensions. *Journal of ultrasound in medicine : Official Journal of the American Institute of Ultrasound in Medicine*, 1(2):49-52
- Dalla Palma L, Morra A, Grotto M *et al.* 2005. CT-Urography. *La Radiologia medica*, 110(3):170-8
- De Sanctis JT, Connolly SA, Bramson RT *et al.* 1998. Effect of patient position on sonographically measured renal length in neonates, infants, and children. *AJR American Journal of Roentgenology*, 170(5):1381-3
- Derchi LE, Martinoli C, Saffioti S *et al.* 1994. Ultrasonographic imaging and Doppler analysis of renal changes in non-insulin-dependent diabetes mellitus. *Academic Radiology*, 1(2):100-5
- Emamian SA, Nielsen MB, Pedersen JF *et al.* 1995. Intraobserver and interobserver variations in sonographic measurements of kidney size in adult volunteers. A comparison of linear measurements and volumetric estimates. *Acta radiologica (Stockholm, Sweden : 1987)* 36(4):399-401
- Giorgio Maria Paolo Graziano *et al.* 2016. Clinical and Molecular Anatomy of Gastrointestinal Stromal Tumors (GIST) *International Journal of New Technology and Research (IJNTR) I*, Volume-2, Issue-4, Pages 110-114 39.
- Giorgio Maria Paolo Graziano, *et al.* 2016. On Traumatic Lesions of The Pancreas *World Journal of Research and Review (WJRR)* ISSN: 2455-3956, Volume-2, Issue-6, Pages 24-28
- Giorgio Maria Paolo Graziano, *et al.* 2016. Which Treatment for Abdominal Trauma in Pediatric Age. *International Journal of New Technology and Research (IJNTR)*, Volume-2, Issue-6, Pages 24-28
- Giorgio Maria Paolo Graziano¹, *et al.* 2016. A Descriptive Study of Differentially Placed Hydatid cysts *International Multispecialty Journal of Health (IMJH)*, Vol-2, Issue-5.
- Giorgio Maria Paul Graziano *et al.* 2016. Early Epithelial Ovarian Carcinoma Treatment. *International Journal of New Technology and Research (IJNTR)*, Volume-2, Issue-5, Pages 69-74
- Giorgio Maria Paul Graziano, *et al.* 2016. Renal Ureterscopy Treatment of Kidney and Bladder Stones *International Journal of New Technology and Research (IJNTR)*, Volume-2, Issue-5, Pages 135-138
- Giorgio Maria Paul Graziano, 2016. Diagnostic and Therapeutic In The Intestinal Duplication *International Journal of Recent Scientific Research*, Vol. 7, Issue, 8, pp. 13000-13003.
- Giorgio Maria Paul Graziano¹ *et al.* Vascular Thoracic Fibrous Adipose Tissue (New Disease) *J Pharm Biomed Sci | Vol. 06 No. 07 | 419-424.*
- Giorgio Maria Paul Graziano, 2016. Which treatment in cystic tumors of the pancreas: conservative or resection. *International Journal of Current Advanced Research*, Vol 5, Issue 8, pp 1190-1198.
- Graziano Giorgio Maria Paolo, *et al.* 2016. Which Therapeutic Treatment in Gastric Lymphoma *World Journal of Research and Review (WJRR)*, Volume-2, Issue-6, Pages 06-09
- Graziano Giorgio Maria Paolo, *et al.* 2016. Humanization of Care Ethical and Social in Clinical-Care *World Journal of Research and Review* Volume-3, Issue-6, Pages 01-08
- Graziano Giorgio Maria Paul and Anthony Di Cataldo, Congenital anomalies of the kidney and urinary tract neoplasms and in the elderly. *Int. J. Adv. Res.*, 5(3), 265-273.
- Griffiths GJ, Cartwright G, McLachlan SF *et al.* 1975. Estimation of renal size from radiographs: is the effort worthwhile? *Clinical radiology*, 26(2):249-56
- Hricak H, Lieto RP, 1983. Sonographic determination of renal volume. *Radiology*, 148(1):311-2
- Partik BL, Stadler A, Schamp S *et al.* 2002. 3D versus 2D ultrasound: accuracy of volume measurement in human cadaver kidneys. *Investigative radiology*, 37(9):489-95
- Paul Graziano GM, Santo C, Luigi S, *et al.* 2016. One Time Surgery in Contemporary Diseases of the Abdominal Wall and Pelvis in the Elderly. *J Surg Surgical Res.*, 2(1): 018-020.
