



ISSN: 0975-833X

Available online at <http://www.journalcra.com>

International Journal of Current Research  
Vol. 9, Issue, 12, pp.63380-63385, December, 2017

INTERNATIONAL JOURNAL  
OF CURRENT RESEARCH

## RESEARCH ARTICLE

### RIGID EXTERNAL DISTRACTOR FOR CORRECTING MIDFACE DEFECTS IN REPAIRED CLEFT LIP-PALATE PATIENTS

**1,\*Dr. Roopav Nargotra, <sup>2</sup>Dr. Satvinder Singh, <sup>3</sup>Dr. Ritesh Gupta and <sup>4</sup>Dr. Shivangi Nargotra**

<sup>1</sup>Assist Prof, Dept of Oral and Maxillofacial Surgery, Indira Gandhi Govt Dental College, Jammu

<sup>2</sup>Assist. Prof, Dept of Oral Medicine and Radiology, Indira Gandhi Govt Dental College, Jammu

<sup>3</sup>Dental Surgeon, Dept of Orthodontics, Indira Gandhi Govt Dental College, Jammu

<sup>4</sup>Private Dental Practitioner, Jammu

#### ARTICLE INFO

##### Article History:

Received 04<sup>th</sup> September, 2017

Received in revised form

23<sup>rd</sup> October, 2017

Accepted 09<sup>th</sup> November, 2017

Published online 31<sup>st</sup> December, 2017

##### Key words:

Distraction Osteogenesis,  
Craniofacial Reconstruction,  
Esthetics,  
Rigid External Distractor.

#### ABSTRACT

**Introduction:** The present study was done to evaluate the effectiveness of distraction osteogenesis as a treatment modality in case of midfacial deformity associated with cleft lip and palate patients and to suggest a modified protocol for distraction osteogenesis for midface and dentoalveolar segments in cleft lip and palate patients. Application of Rigid external distractor (RED). The distraction was carried out over a period of 6-13 days at a rate of 4.0 mm per day.

**Materials and Methods:** Ten patients with cleft lip and palate having midfacial deficiency and falling in ASA grade 1 and ASA grade 2 categories were selected and taken up for the necessary treatment with the use of a Le Fort 1 osteotomy a

**Results:** Advancement of the segment achieved at the end of one month fell in the range of 16 mm – 24 mm and 7 mm - 18 mm at the end of six months.

**Conclusion:** Distraction osteogenesis proved to be an effective treatment modality in case of craniofacial deformity associated with cleft lip and palate patients. We have also suggested a modified protocol for distraction osteogenesis for midface and dentoalveolar segments in such patients.

Copyright © 2017, Roopav Nargotra et al. This is an open access article distributed under the Creative Commons Attribution License, which permits unrestricted use, distribution, and reproduction in any medium, provided the original work is properly cited.

**Citation:** Dr. Roopav Nargotra, Dr. Satvinder Singh, Dr. Ritesh Gupta and Dr. Shivangi Nargotra, 2017. "Rigid external distractor for correcting midface defects in repaired cleft lip-palate patients.", *International Journal of Current Research*, 9, (12), 63380-63385.

## INTRODUCTION

With the increase in number of surgical procedures for the early repair of cleft lip and palate patients, there has been a concomitant increase in the secondary surgeries required for the large osseous defects of the alveolus and midface hypoplasias because of early repair and the consequent scarring. In most of these patients, normal growth of maxilla may be hindered in all the three planes but the mandibular growth appears normal. Other anomalies associated with the maxillary bone are deficient or absent maxillary or alveolar bone, residual fistulas, malocclusion and missing (Sinha *et al.*, 2011). One of the biggest limitation of traditional orthognathic surgery and craniofacial reconstruction which is employed as a standard procedure is relapse. The widely accepted cause for this if the inability of the soft tissue to stretch beyond a limit.

\*Corresponding author: Dr. Roopav Nargotra,

Assist Prof, Dept of Oral and Maxillofacial Surgery, Indira Gandhi Govt Dental College, Jammu.

Apart from this, other major concerns include speech problems, compromised function, selective age group and infection (Figueroa *et al.*, 2004). In short, traditional treatments despite obtaining a stable occlusal relationship fall short of expectations with respect to facial balance and esthetics (Swennen *et al.*, 2001). Distraction Osteogenesis utilizes the regenerative capacity of bone as its basic principle along with the soft tissue improvement. By doing so, it bypasses most of the hinderances associated with the orthognathic surgery and restores form and function.

## MATERIALS AND METHODS

10 cases with midface deficiency secondary to previous cleft lip and palate surgeries and falling in ASA grade 1 and ASA grade 2 categories were selected and taken up for the necessary treatment with the use of a Le Fort 1 osteotomy and application of Rigid external distractor (RED). Complete case history was taken along with general physical examination. Any syndromic patients were not taken up for the study.

## Photographic Records

Photographic records were maintained preoperatively, intraoperatively, during retention period and postoperatively in all the cases.

## Radiographic Records

Preoperative lateral cephalograms and orthopantomograms were taken to evaluate the midface deficiency and occlusal radiographs, intraoral periapical radiographs were taken to determine the position of the roots of the teeth. Immediate Postoperative lateral cephalograms, lateral cephalograms at the end of 1 month and lateral cephalograms at the end of 6 months were taken for the evaluation of advancement.

## Criteria for patient selection

The criteria governing the selection were as follows

- Patients with repaired cleft lip and palate with mid face deficiency.
- Patients falling in ASA grade 1 and ASA grade 2 categories.
- Patient of both sexes falling in the age group of 11 years and 18 years.
- Patient should agree to presurgical and postsurgical orthodontics

## Surgical Techniques

In Operation theatre after Intubation throat pack was placed in all patient and patient were scrubbed and draped as per routine.

### Le Fort 1 Osteotomy

The oral incision was placed high in the mucobuccal fold of the upper lip, and it extended from the zygomaticomaxillary buttress region across the midline. The incision traversed the mucosa, the muscles attached to the lateral wall of the maxilla, and the periosteum. The lateral walls of maxilla were exposed superior to the incision. By subperiosteal dissection to the orbital rim, the infraorbital nerve was exposed and protected. The anterior nasal spine and the piriform rim were identified and the septomaxillary ligament was removed from the anterior nasal spine. The nasal mucosa was then dissected from the lateral wall and the floor. The dissection of the posterior maxilla was tunneled to preserve a broad based mucosal pedicle. The direction of the posterior dissection was posterior and inferior to the zygomaticomaxillary buttress to the pterygoid plate. The osteotomy was initiated at the zygomaticomaxillary buttress region about 5 mm superior to the second molar to minimize the risk of devitalisation of teeth. The posterior lateral wall of maxilla was sectioned under the mucosal tunnel. The posterior osteotomy was directed inferiorly as it proceeded posteriorly from the zygomaticomaxillary buttress to the junction of the maxilla and the pterygoid plate in order to minimize the risk of damaging the maxillary artery. Then the osteotomy of the maxillary sinus was completed from inside to outside. Similar procedure was carried out on the contralateral side. Now the bone of the nasal septum and vomer from the maxilla was freed of the cartilage with the help of a septal osteotome. The osteotome was now placed at the piriform rim and directed posteriorly and inferiorly along the lateral nasal wall towards the perpendicular plate of the palatine bone and the palatine bone was sectioned off.

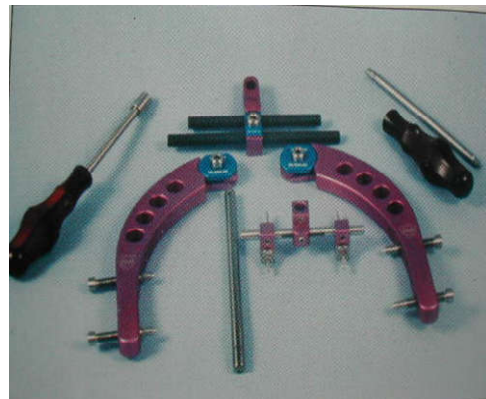
Now the maxilla was separated from the pterygoid plates. A curved osteotome was directed medially and anteriorly at the lowest part of the junction of the maxilla and the pterygoid plate. The osteotome was malleted to achieve bony separation and the tip was palpated after doing this. With hand pressure at the anterior aspect of the maxilla, the maxilla was downfractured. A prefabricated splint was now placed in the oral cavity and stabilized further, if required, with interdental wires. In the end, the head frame was centralized and attached to the cranium. Then the patient was extubated and shifted to recovery.

## Distraction Protocol

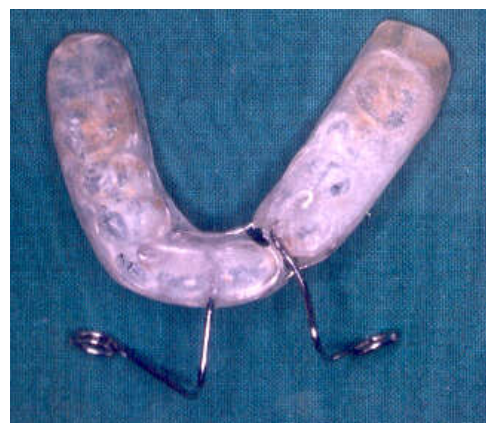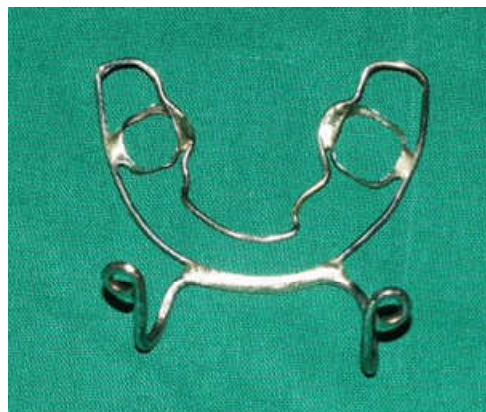Latency period of 2 days. Distraction at the rate of 4 mm / 2mm (2mm twice daily) for 4-7 days. Consolidation period of 3-6 months

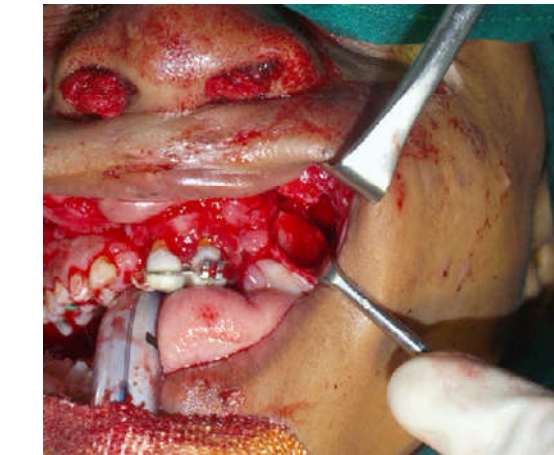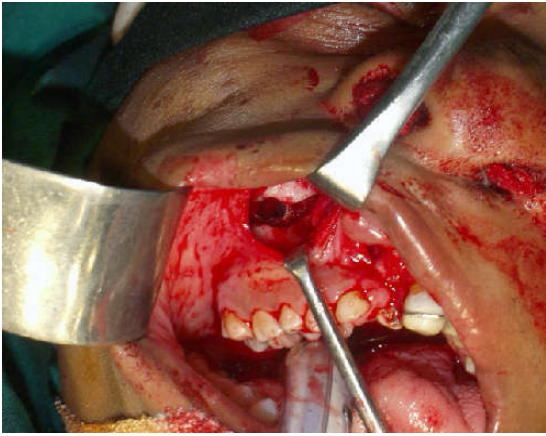
## Regular follow up

## Splints and Distractors

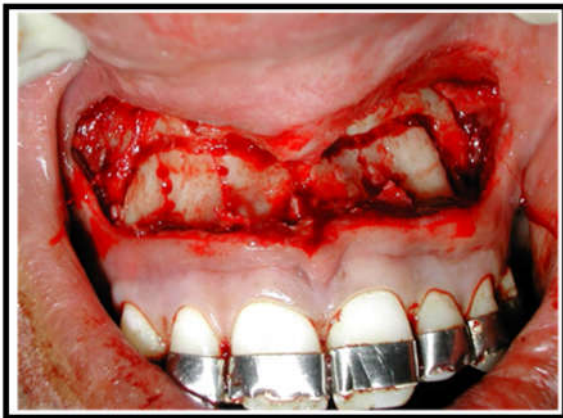

## Red System

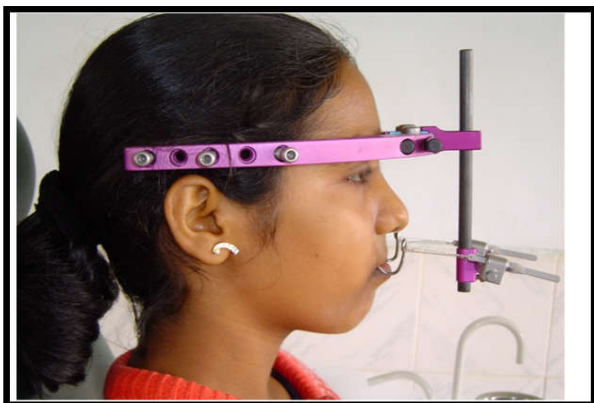




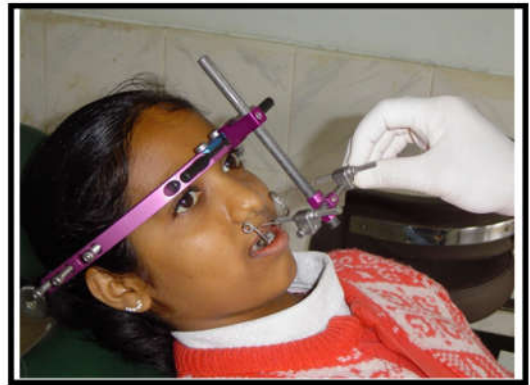Surgical photographs lefortiosteotomy by tunneling method



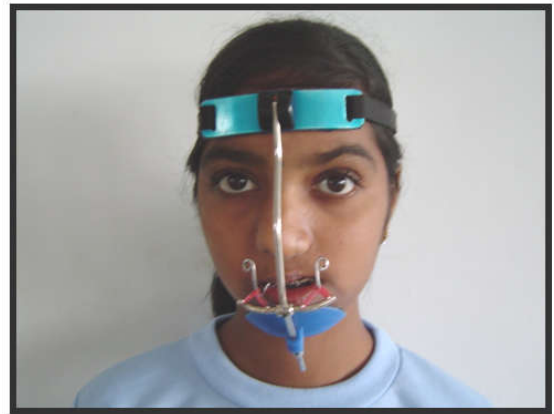
Le Fort I Osteotomy



Distractor In Position

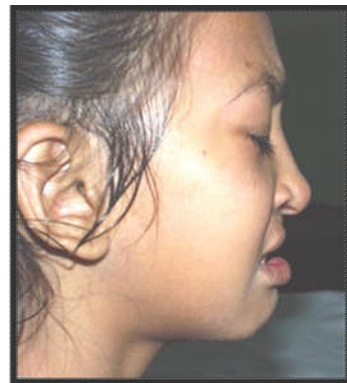

Activation of Distractor

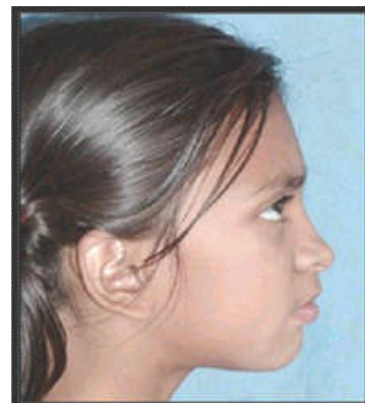

Elastic Traction

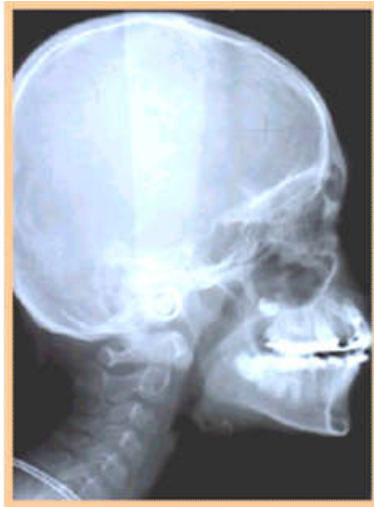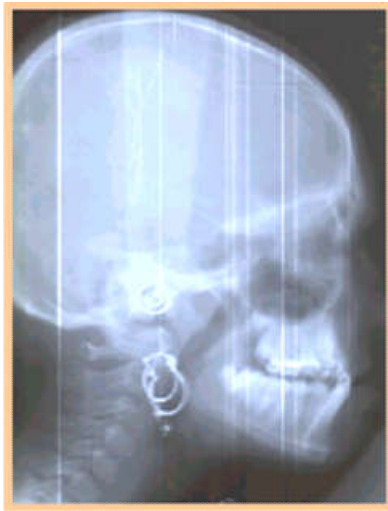Comparative Photographs And Lateral Cephalograms (Red Group)



Preoperative



Postoperative



## RESULTS

Out of ten patients treated, 6 (60%) were males and four (40%) were females. The average age for males was 16 years & the average age for females was 14 years.

### TOTAL ACTIVATION DONE

Sl. No.	Patient Name	Age	Sex	Activation done	Distraction rate Per day	No. of Days
1.	Vaishali	12	F	20 mm	4.0 mm	5
2.	Suchitra	13	F	24 mm	4.0 mm	6
3.	Vinayak	16	M	24 mm	4.0 mm	6
4.	Ashish	14	M	24 mm	4.0 mm	6
5.	Mahesh	17	M	28 mm	4.0 mm	7
6.	Benazir	12	F	18 mm	2.0 mm	9
7.	Sarita	14	F	20 mm	2.0 mm	10
8.	Vaibhav	14	M	26 mm	2.0 mm	13
9.	Pinka	16	M	18 mm	2.0 mm	9
10.	Shakeel	17	M	20 mm	2.0 mm	10

### ADVANCEMENT AFTER 6 MONTHS

Sl. No.	Patient name	Age (yrs)	Sex	1 month advancement	6 month advancement	Relapse
1.	Vaishali	12	F	18 mm	15 mm	3 mm
2.	Suchitra	13	F	22 mm	18 mm	4mm
3.	Vinayak	16	M	21 mm	17 mm	4 mm
4.	Ashish	14	M	20 mm	7 mm	13 mm
5.	Mahesh	17	M	24 mm	18 mm	6mm
6.	Benazir	12	F	16 mm	12 mm	4 mm
7.	Sarita	14	F	18 mm	18 mm	0 mm
8.	Vaibhav	14	M	20 mm	15 mm	5 mm
9.	Pinka	16	M	16 mm	14 mm	2 mm
10.	Shakeel	17	M	18 mm	14 mm	4 mm

Distraction was carried out at a rate of 4.0 mm per day for FIVE patients (split over twice daily). FIVE patients were distracted at the rate of 2.0mm per day (split over twice daily). The distraction was carried out over a period of 5-13 days (avg 8.1 days). The total activation done varied from 20-28 mm (avg 21.8 mm). All the patients were followed up for a period of minimum six months. Advancement of the segment achieved at the end of one month fell in the range of 16mm - 24mm (avg 19.3 mm). Advancement at the end of six months was 7mm - 18 mm (avg 14.8 mm).

All the patients showed some amount of relapse that ranged from 2mm – 13 mm (avg 4.6 mm) after which the segments were stable. This relapse was measured by comparing the position of the maxilla at the end of six months with the position of maxilla at the end of one month. One (10%) patient showed poor compliance. Seven (70%) patients were satisfied with the results and two (20%) was partially happy. Relapse within normal limits (<5mm) was seen in seven (70%) patients. One (10%) patient showed a relapse of 13 mm. One patient had pin tract infection. Early consolidation was seen in two (20%) patients. Loosening of splint was seen in one (10%) patient. Tissue trauma (irritation of the tissue with the splint) was seen in one (10%) patient. However nine (90%) patients showed definite improvement in their profile and had better esthetics compared to the preoperative picture.

## DISCUSSION

Cleft lip and palate is one of the most common congenital defects found all over the world and is fairly common in India. The patients present with multiple problems such as speech effects, dental anomalies and also midfacial hypoplasias. It has been estimated that 25% - 50% of all patients born with unilateral cleft lip and palate will be candidates for maxillary advancement to correct functional deformities and improve aesthetic facial proportion. Other studies put this incidence to 25%-60% (Andersen *et al.*, 2012; Øland *et al.*, 2010). Traditionally Patients with severe cleft maxillary deficiency were treated with surgical/orthodontic approach.

## PATIENT COMPLIANCE DURING THERAPY

Sl. No.	Patient name	Age (yrs)	Sex	Compliance during therapy		
				Good	Average	Poor
1.	Vaishali	12	F	✓	-	-
2.	Suchitra	13	F	✓	-	-
3.	Vinayak	16	M	✓	-	-
4.	Ashish	14	M	-	-	✓
5.	Mahesh	17	M	✓	-	-
6.	Benazir	12	F	✓	-	-
7.	Sarita	14	F	✓	-	-
8.	Vaibhav	14	M	✓	-	-
9.	Pinka	16	M	✓	-	-
10.	Shakeel	17	M	✓	-	-

## PATIENT SATISFACTION

Sl. No.	Patient name	Age (yrs)	Sex	Patient satisfaction with results		
				Good	Average	Poor
1.	Vaishali	12	F	-	✓	-
2.	Suchitra	13	F	✓	-	-
3.	Vinayak	16	M	✓	-	-
4.	Ashish	14	M	-	✓	-
5.	Mahesh	17	M	✓	-	-
6.	Benazir	12	F	✓	-	-
7.	Sarita	14	F	✓	-	-
8.	Vaibhav	14	M	✓	-	-
9.	Pinka	16	M	✓	-	-
10.	Shakeel	17	M	✓	-	-

## COMPLICATIONS DURING THERAPY

Sl. No.	Patient name	Complications						
		Relapse	Infection	Necrosis	Early consolidation	Loosening of splint	Non compliance	Trauma to tissues
1.	Vaishali	✓	-	-	-	-	-	-
2.	Suchitra	✓	-	-	✓	-	-	-
3.	Vinayak	✓	-	-	-	✓	-	-
4.	Ashish	✓	-	-	-	-	✓	-
5.	Mahesh	✓	✓	-	-	-	-	✓
6.	Benazir	✓	-	-	-	-	-	-
7.	Sarita	-	-	-	-	-	-	-
8.	Vaibhav	✓	✓	-	-	-	-	✓
9.	Pinka	✓	-	-	-	-	-	-
10.	Shakeel	✓	-	-	-	-	-	-

However, due to maxillary hypoplasia in all the three dimensions along with thin and weak bones, there was severe incidence of relapse. Also severe maxillary hypoplasia contributed to compromised mastication, speech abnormalities and pharyngeal airway constriction (Polley *et al.*, 1997). Current protocols in treatment of maxillary hypoplasia rely upon a surgical/orthodontic approach, including a Le Fort I maxillary advancement with concomitant fistula closure and maxillary and alveolar bone grafting (Heggie *et al.*, 2013). Mean advancement in these patients has averaged between 5mm to 7mm and mean long-term horizontal relapse ranges from 20% to 25% (Hierl, 2001). The major problem in patients treated with cleft orthognathic surgery with a Le Fort I osteotomy is the tendency for medial, superior, and posterior drift of lesser segment in some patients. To combat this relapse pattern, planned surgical overcorrection, and long-term orthodontic retention techniques are required. There is also a less than ideal rate of successful fistula closure and premaxillary segment stabilization. Distraction seems to overcome most of these problems. One of the greatest advantages of distraction osteogenesis is that it can be done at any age (as early as 5 years) (Tong *et al.*, 2003). In this study, 10 consecutive patients underwent maxillary advancement at Le Fort I level using rigid external distractor (RED).

In ONE patient, an acrylic and wire splint covering the occlusal surface was prepared. But various problems were encountered in such a splint.

### These were

- No clinical guidance for assessment for movement was there.
- It was unhygienic and uncomfortable.
- Patient complained of difficulty in eating.
- In 9 patients, prefabricated 1.0 mm stainless steel wire splint was used for retention intraorally. The advantages of such a splint were
- It is custom designed, which is imperative, especially in patients with clefts that present with severe dental malpositions and collapsed cleft arch segments.
- It is hygienic, comfortable and nontraumatic.
- Simultaneous orthodontic movements, such as correction of dental rotations, as well as expansion, can be performed.
- The active and the retention intraoral devices are the same.

- The vectors of distraction can be changed at any time during the distraction process without discomfort to the patient, thus allowing for force vector changes as needed.

One patient showed a severe relapse of 13 mm. This was attributed to the non-compliance during therapy. RED uses a skeletally fixed device that allows rigid predictable control over the distraction process. This device is readily adjustable, offering the ability to change the vertical and horizontal vector of distraction at any time during the distraction. Distraction was carried out at a rate of 2 mm in the morning and 2 mm in the evening after a latency period of 4 days in all patients. A retention period of 4 weeks was given. The time of post distraction cephalometric analysis was 6 months. This is a protocol that is not followed in most centers. Mean advancement achieved at the end of 6 months in these patients was 14.8 mm. This was within the presurgical assessment limits. The use of RED can now gradually and in a very stable fashion reposition a hypoplastic maxilla to the exact position as desired. As autogenous bone is created during this process, there is no need a donor site. The expansion of the soft tissue yields the most pleasing long-term aesthetic facial balance (Meazzini *et al.*, 2012; Roopav Nargotra, 2014).

The only limitations we encountered with RED include presence of adequate dentition, either primary or secondary, for fixation of intraoral splint as well as ability of the patient to wear the device which is in accordance with those in a study conducted by Figueroa (Figueroa *et al.*, 2004).

### Summary and Conclusion

Patients with repaired cleft lip and palate present with large osseous defects of the alveolus and midface hypoplasias. Severe limitations with traditional orthognathic surgery and craniofacial reconstruction have been seen. Distraction osteogenesis – a recently developed technique seems to solve most of these problems. In our study, we tried to evaluate the effectiveness of distraction osteogenesis using RED System as a treatment modality in 10 cases of craniofacial deformity associated with cleft lip and palate patients. We have also tried to suggest a modified protocol for distraction osteogenesis for midface and dentoalveolar segments in cleft lip and palate patients. The overall results we achieved were encouraging. However, for these results to be clinically significant, it is necessary that the sample size is increased and speech studies are included. Also, a longer follow up is necessary to check for any relapse, long-term stability of bone.

### REFERENCES

- Andersen K, Nørholt SE, Kùseler A, Jensen J, Pedersen TK. 2012. A Retrospective Study of Cleft lip and palate Patients' Satisfaction after Maxillary Distraction or Traditional Advancement of the Maxilla. *J Oral Maxillofac Res.*, 3(2): 1-7.
- Figueroa AA, Polley JW, Friede H, Ko EW. 2004. Long-term skeletal stability after maxillary advancement with distraction osteogenesis using a rigid external distraction device in cleft maxillary deformities. *Plast Reconstr Surg.*, 114 (6):1382–1392.
- Heggie AA, Kumar R, Jocelyn MS. 2013. The role of distraction osteogenesis in the management of craniofacial syndromes. *Ann Maxillofac Surg.*, 3(1): 4–10.
- Hierl T, Kloppel R, Hempick A. 2001. Midfacial distraction osteogenesis without major osteotomies: A report on the first clinical application. *Plast Reconstr Surg.* 108(6): 1667-1672.
- Meazzini MC, Allevia F, Mazzoleni F, Ferrari L, Pagnoni M, Iannetti G, *et al.* 2012. Long-term follow-up of syndromic craniosynostosis after Le Fort III halo distraction: A cephalometric and CT evaluation. *J Plast Reconstr Aesthet Surg.*, 65: 464–72.
- Øland J, Jensen J, Melsen B. 2010. Factors of importance for the functional outcome in orthognathic surgery patients: a prospective study of 118 patients. *J Oral Maxillofac Surg.*, 68(9):222131.
- Polley JW, Figueroa AA. 1997. Management of severe maxillary deficiency in childhood and adolescence through distraction osteogenesis with an external,adjustable, rigid distraction device. *Craniofac Surg.*, 8(3):181–185.
- Roopav Nargotra. 2014. Distraction Osteogenesis as a Treatment Modality for Repaired Cleft LipPalate Patients. Research and reviews: *Journal of Dental Sciences* 2(4): 93-98
- Sinha R, Menon PS, Venugopal MG. 2011. A clinical evaluation of midface advancement using intraoral distractors in management of bone stock deficiencies. *MJAFI.* 67:245–252. Sullivan KO. Tooth eruption in the bone grafted maxillary cleft alveolus. *Int J Oral Surg.* 1981; 10:309-312.
- Swennen G, Schliephake H, Dempf R. 2001. Craniofacial distraction osteogenesis: a review of literature. Part 1: clinical studies *Int J Oral Maxillofac Surg.* 30:89-103.
- Tong AC, Yan BS, Chan TC. 2003. Use of interdental distraction osteogenesis for orthodontic tooth alignment and correction of maxillary hypoplasias: a case report. *Br J Oral Maxillofac Surg.* 41:185-187.

\*\*\*\*\*