



ISSN: 0975-833X

Available online at <http://www.journalcra.com>

International Journal of Current Research  
Vol. 9, Issue, 12, pp.63399-63401, December, 2017

INTERNATIONAL JOURNAL  
OF CURRENT RESEARCH

## RESEARCH ARTICLE

### CHANGE IN REFRACTIVE STATUS FOLLOWING TRABECULECTOMY USING CONVENTIONAL INTERRUPTED SUTURES VERSUS RELEASABLE SUTURES

\*Sud, R., Gogi, A. and Raina, U. K.

Kalpana Chawla Medical College, India

#### ARTICLE INFO

##### Article History:

Received 16<sup>th</sup> September, 2017  
Received in revised form  
07<sup>th</sup> October, 2017  
Accepted 19<sup>th</sup> November, 2017  
Published online 31<sup>st</sup> December, 2017

##### Key words:

Trabeculectomy,  
Releasable sutures,  
Conventional sutures,  
Astigmatism,  
Visual acuity.

#### ABSTRACT

**Purpose:** Trabeculectomy with or without various modifications forms the surgical mainstay of glaucoma treatment. The impact of the procedure on the visual prognosis on the glaucoma patient must be carefully evaluated. Our purpose is to study the stabilization and alterations in the refractive status following trabeculectomy using conventional interrupted sutures and releasable sutures.

**Methods:** This was a prospective comparative study. A total of 40 eyes of 37 patients were randomly divided into 2 groups: Group A with 20 eyes undergoing trabeculectomy with conventional sutures and Group B with 20 eyes undergoing trabeculectomy with releasable sutures. The visual acuity, simulated keratometry and astigmatism was measured on day 1, day 7, day 30 and day 90.

**Results:** The change in the mean visual acuity in group A at day 90 was -0.0140 whereas in group b it was -0.0350. The difference was not found to be statistically significant ( $p=0.603$ ). The astigmatism on day 90 in group a was found to be  $1.28 \pm 0.69$  whereas in group b was found to be  $1.52 \pm 1.49$ . The difference was not found to be statistically significant ( $p=0.511$ ).

**Conclusion:** Trabeculectomy using releasable sutures has all its advantages of minimizing shallow anterior chamber and hypotony in the early postop period as well as ensuring a good long term bleb function, along with no statistically significant difference in postoperative astigmatism as compared to trabeculectomy with conventional sutures.

Copyright © 2017, Sud et al. This is an open access article distributed under the Creative Commons Attribution License, which permits unrestricted use, distribution, and reproduction in any medium, provided the original work is properly cited.

**Citation:** Sud, R., Gogi, A. and Raina, U. K. 2017. "Change In refractive status following trabeculectomy using conventional interrupted sutures versus releasable sutures", *International Journal of Current Research*, 9, (12), 63399-63401.

## INTRODUCTION

Performing trabeculectomy at a relatively early stage in the progression of glaucoma has been a controversial topic in recent years (Thomas and Bllson, 1989 - Beck, 1984). However with reports of success rates of 75% to 90% and several studies suggesting the superiority of trabeculotomy over medical therapy in selected cases, more surgeons are adopting this strategy. Trabeculectomy using releasable sutures is an effective method in titrating postoperative filtration (Cohen and Osher, 1988). It allows the surgeon to close the scleral flap relatively tight intraoperatively, thereby decreasing the incidence of early postoperative complications. When the wound and anterior chamber are believed to be stabilised, the sutures can be removed, serially, to increase filtration in small increments and thus simulate a full thickness filtration procedure (Thomas *et al.*, 1997). After successful trabeculectomy patients often complain of reduction in vision (Costa *et al.*, 1993). Most patients improve within 6 weeks. The cause of transient visual loss is not clear. Surgically induced alterations in the corneal curvature resulting from filtration

surgery may have a significant impact on patients, especially the younger ones, whose vision may already be compromised by visual field loss. Other possible causes include disruption of tear film, subtle corneal surface contour changes, iridocyclitis, movement of iris-lens diaphragm, macular edema, retinal haemorrhages, and changes in choroidal thickness due to acute hypotony. A study measuring pre and postoperative corneal curvature indicated complex regional changes (Claridge *et al.*, 1995). Computer assisted corneal topography revealed these complex regional changes in corneal curvature that were not readily detected from alteration in refraction or keratometry. These changes were significantly great to have an effect on visual function in some patients. Moreover, computer assisted corneal topography can also study peripheral corneal changes, which cannot be assessed by keratometry. Only few reports are available on changes in corneal topography following trabeculectomy (Claridge *et al.*, 1995-Hornova, 1998) and to the best of our knowledge, only one study documenting the alteration in corneal curvature following trabeculectomy with releasable sutures (Dietze *et al.*, 1997).

#### Aims and Objectives

- To study the stabilization of refractive status following trabeculectomy using conventional interrupted sutures and releasable sutures.

\*Corresponding author: Sud, R.  
Kalpana Chawla Medical College, India.

- To compare the alterations in refractive status following trabeculectomy using conventional interrupted sutures and releasable sutures.

## MATERIALS AND METHODS

### Inclusion Criteria

Patients with the diagnosis of primary open angle glaucoma and primary closed angle glaucoma, uncontrolled, with maximal medical and/or laser therapy and needing filtration surgery were included in this study.

### Exclusion criteria

Patients having corneal opacities, congenital/juvenile glaucoma, secondary glaucoma, with previous ocular surgery and patients needing combined surgery were excluded from the study.

A total of 40 eyes of 37 patients were randomly divided into 2 groups as follows:

**Group A:** 20 eyes undergoing trabeculectomy with conventional 10-0 nylon sutures

**Group B:** 20 eyes undergoing trabeculectomy with releasable 10-0 nylon sutures

Preoperative assessment of patients included detailed ocular examination including detailed slit lamp examination, refraction and best corrected visual acuity, intraocular pressure, gonioscopy, anterior chamber depth and corneal thickness measurement, axial length, manual keratometry and corneal topography. All surgeries were conducted under peribulbar anaesthesia. A limbal based conjunctival flap was created 8-10 mm from the limbus. A triangular partial thickness flap measuring 4mmx4 mm was dissected upto the limbal zone. Innersclerotomy measuring 2x2mm was made just anterior to the scleral spur followed by peripheral iridectomy. The scleral flap was closed with 3 interrupted 10-0 nylon sutures in group A. The tightness of the sutures was adjusted to maintain the anterior chamber depth and to restrict aqueous run off around the flap edges to little or no flow. Conjunctival flap was sutured using 8-0 nylon mattress sutures. The releasable suture technique was identical except for the closure of the scleral flap. The apex of the partial thickness scleral flap was closed with 1 interrupted 10-0 nylon suture.

The releasable suture was placed 1 on each side. To place the releasable sutures the needle was passed first into the sclera and then through the scleral flap. The needle was passed through the base of the scleral flap beneath the conjunctival insertion and then through the peripheral cornea 1-2 mm from the limbus. A small superficial bite through adjacent cornea was then taken. The corneal end of the suture was then cut flush to avoid leaving a protruding suture end. The sutures were tied with a quadruple throw hemi bow slip knot. Detailed postoperative assessment was carried out for all patients including detailed slit lamp examination, refraction and best corrected visual acuity, intraocular pressure gonioscopy, anterior chamber depth and corneal thickness measurement, axial length, manual keratometry and corneal topography.

## RESULTS

**Age and Sex distribution:** The age of the patients in the study ranged from 40-69 years with a mean of 52.77±7.05 years. No statistically significant difference was noted between the two groups in terms of age distribution (p=0.876). There were 14 males and 23 females in the study. No statistically significant difference was noted in the sex distribution.

**Visual Acuity:** The range of visual acuity in Snellen's fraction varied from 0.033 to 0.67 with an average of 0.31±0.22 in Group A while in Group B the range extended from 0.033 to 0.67 with an average of 0.34±0.20.

There was no statistically significant difference in the astigmatism (p=0.612), manual keratometry (p=0.864) and Sim k (p=0.591)

**Sim K:** The mean simulated keratometry readings in the two groups during the postoperative period are summarized below (Table 1)

**Table 1. Mean change in the Sim k values in the postoperative period**

Mean Sim-K readings {in dioptries}	Group A	Group B	p
Day 1	43.21±2.22	43.98±2.05	0.263
Day 7	44.97±1.50	44.49±1.94	0.396
Day 30	44.75±1.73	44.86±2.36	0.865
Day 90	44.33±1.40	44.75±1.83	0.425

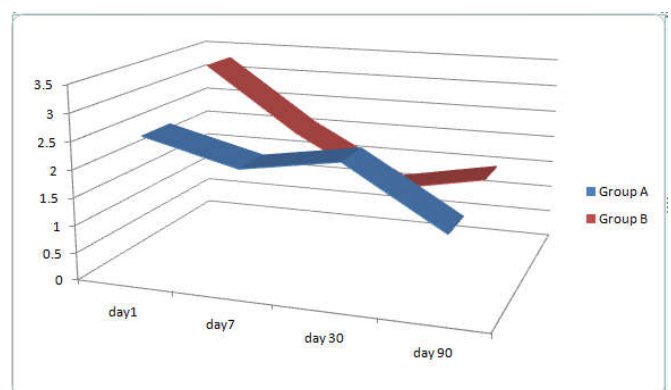
### Astigmatism on corneal Topography

The particulars of mean astigmatism recorded on corneal topography are summarized in the table below (Table 2).

**Table 2. Mean postoperative astigmatism on corneal topography**

Astig based on Sim-K {in dioptries}	Group A	Group B	p
Day 1	2.5±1.38	3.33±2.78	0.295
Day 7	2.06±1.31	2.12±1.04	0.209
Day 30	2.34±1.74	1.18±0.95	0.014
Day 90	1.28±0.69	1.52±1.49	0.511

### Variation in astigmatism (Based on Sim k) with time (Chart 1.)



**Chart 1.**

There was no significant difference in the postoperative astigmatism between the two groups. Change in the orientation of the steep axis. For each postop interval, preoperational

angle of astigmatism was subtracted from the preoperative value. Mean change in the orientation of the steep axis between the two groups is detailed below (Table 3).

**Table 3. Mean change in the postoperative steep axis**

Axis rotation	Group A	Group B	p
Day 1	45.9±21.2	42.2±27.5	0.637
Day 7	45.4±28.8	41.8±30.0	0.701
Day 30	37.9±29.0	36.4±31.8	0.876
Day 90	33.6±32.2	23.0±24.7	0.251

The mean rotation of the steep axis in the postoperative period revealed no significant difference between the two groups

## DISCUSSION

During the years since its development trabeculectomy has been the procedure of choice for glaucoma. Unlike the initial full thickness fistulas, the overlying scleral flap in trabeculectomy prevents overfiltration through the sclerostomy in the early postoperative period, thereby decreasing the incidence of hypotony and shallow anterior chamber and their related complications. With reports of success rates of as high as 90% there is a growing trend of performing surgery early in the disease. However, the resulting "guarded" aqueous outflow prevents the profound and long-lasting reduction in intraocular pressure typically obtained with a full thickness filtration procedure. Use of releasable sutures allows the surgeon to close the scleral flap relatively tight intraoperatively, thereby further decreasing the incidence of early postoperative complications. The sutures can be removed serially, once the wound and anterior chamber are believed to be stabilized, to increase filtration in small increments. The impact of surgically induced alterations in corneal curvature resulting from filtration surgery has not been studied systematically. Only few reports are (Claridge *et al.*, 1995; Hornova, 1998; Dietze *et al.*, 1997; Zarnowski *et al.*, 1997; Rosen *et al.*, 1992; Hayashi *et al.*, 2000) are available in literature on corneal topography changes following trabeculectomy and to the best of our knowledge, only one study documenting the alteration in corneal curvature following trabeculectomy with releasable sutures (Hornova, 1998). To our knowledge, there is no comparative study on refractive status following conventional trabeculectomy vs releasable suture technique. The present study was conducted to compare the alterations and stabilization on refractive status following trabeculectomy using conventional interrupted sutures and releasable sutures. Our longitudinal study on corneal curvature changes following trabeculectomy, with and without releasable sutures, demonstrated that surgery has a distinct effect on corneal topography. There was a trend towards transient trabeculectomy induced astigmatism in the meridian of surgery (shift towards with-the-rule astigmatism) in both the groups, particularly in the central zone, irrespective of the preoperative orientation of the axis. The surgically induced astigmatism progressively diminished by day 30. However, corneal topography revealed alterations even at 3 months postoperatively. These alterations in corneal topography produced between the two groups were not found to be statistically significant.

## Conclusion

Trabeculectomy with or without various modifications forms the surgical mainstay of glaucoma treatment. The impact of the procedure on the visual prognosis on the glaucoma patient must be carefully evaluated. Our study demonstrated that surgery has a distinct effect on corneal topography. Alterations in corneal topography produced by trabeculectomy using releasable sutures were in no way significantly different from changes in topography induced by conventional trabeculectomy and showed a shift towards with-the-rule astigmatism, which persisted even at 3 months postoperatively. Trabeculectomy using releasable sutures has all its advantages of minimizing shallow anterior chamber and hypotony in the early postoperative period as well as ensuring a good long term bleb function, along with no statistically significant difference in postoperative astigmatism as compared to trabeculectomy with conventional sutures.

## REFERENCES

- Beck L. and Jones DEP. 1984. Surgical decisions in glaucoma simplex. *Br J Ophthalmol.*, 68:732-735.
- Claridge, KG, Galbraith JK. and Karmel, V. 1995. The effect of trabeculectomy on refraction, keratometry and corneal topography. *Eye*, 93:292-298.
- Cohen J S. and Osher RH. 1988. Releasable scleral flap suture. *Ophthalmol Clin North America*, 1:187-197.
- Costa VP, Smith M, Spaeth GL, Gandham S. and Markovitz, B. 1993. Loss of visual acuity after trabeculectomy. *Ophthalmology*, 100; 599-612.
- Dietze PJ, Oram O. and Kohnen T. 1997. Visual function following trabeculectomy: Effect on corneal topography and contrast sensitivity. *J Glaucoma.*, 6(2):99-103.
- Hayashi K., Hayashi H. and Oshita T. 2000. Fourier analysis of astigmatism following trabeculectomy. *Ophthalmic Surg Laser*, 31(2):94-99.
- Hornova J. 1998. Trabeculectomy with releasable sutures and corneal topography. *Cesk Slovovalml*, 54(6):368-72.
- Rosen WJ, Annis MJ. and Brandt, JD. 1992. The effect of trabeculectomy on corneal topography. *Ophthalmic Surg.*, 23(6):395-8.
- Thomas R, Jacob P, Braganza A, Mermoud A. and Muliylil J. 1997. Releasable suture technique for trabeculectomy. *Indian J Ophthalmol.*, 45(1):37-41.
- Thomas R. and Billson F. 1989. The place of trabeculectomy in the management of primary open angle glaucoma and factors featuring success. *Aust NZJ Ophthalmol.*, 17:217-223.
- Watson PG. And Grierson I. 1981. The place of trabeculectomy in the treatment of glaucoma. *Ophthalmology*, 88:175-196.
- Zarnowski T, Haszcz D. and Rakowska E. 1997. Corneal astigmatism after trabeculectomy. *Klin Oczna.*, 99(5):313-5.

\*\*\*\*\*