



ISSN: 0975-833X

Available online at <http://www.journalcra.com>

International Journal of Current Research  
Vol. 10, Issue, 01, pp.64650-64653, January, 2018

INTERNATIONAL JOURNAL  
OF CURRENT RESEARCH

## RESEARCH ARTICLE

### INTER DENTAL PAPILLA MANAGEMENT: A REVIEW

<sup>1,\*</sup>Apoorva, M., <sup>2</sup>Vijay K Raghava, <sup>3</sup>Sarita Joshi Narayan, <sup>4</sup>Dr. UmeshYadalam,  
<sup>5</sup>Sheetal, S. and <sup>6</sup>Fakeha Hareem

<sup>1</sup>Post graduate student, Department of Periodontics, Sri Rajiv Gandhi College of  
Dental Sciences and Hospital, Cholanagar, Hebbal, Bengaluru, Karnataka

<sup>2</sup>Professor, Department of Periodontics, Sri Rajiv Gandhi College of Dental Sciences and Hospital,  
Cholanagar, Hebbal, Bengaluru, Karnataka

<sup>3</sup>Head of the Department of Periodontics, Sri Rajiv Gandhi College of Dental Sciences and Hospital,  
Cholanagar, Hebbal, Bengaluru, Karnataka

<sup>4</sup>Professor, Department of Periodontics, Sri Rajiv Gandhi College of Dental Sciences and Hospital,  
Cholanagar, Hebbal, Bengaluru, Karnataka

<sup>5</sup>Post graduate student, Department of Periodontics, Sri Rajiv Gandhi College of Dental Sciences and  
Hospital, Cholanagar, Hebbal, Bengaluru, Karnataka

<sup>6</sup>Post graduate student, Department of Periodontics, Sri Rajiv Gandhi College of Dental Sciences and  
Hospital, Cholanagar, Hebbal, Bengaluru, Karnataka

#### ARTICLE INFO

##### Article History:

Received 19<sup>th</sup> October, 2017

Received in revised form

26<sup>th</sup> November, 2017

Accepted 22<sup>nd</sup> December, 2017

Published online 31<sup>st</sup> January, 2018

#### ABSTRACT

Interdental papillary recession has been esthetical as well as an oral hygiene maintenance problem for the patients. Abnormal tooth shape, improper contours of prosthetic restorations, and traumatic oral hygiene procedures may also negatively influence the outline of the interdental soft tissue. There are very fewer surgical techniques to create interdental papilla, which has been very technique sensitive and less predictive in treatment outcome. In this article, a review is attempted to illustrate various causes, classification, and management of interdental papilla.

#### Key words:

Gingival Recession,  
Interdental Papilla,  
Muco-Gingival Surgery,  
Periodontal Plastic Surgery.

Copyright © 2018, Apoorva et al. This is an open access article distributed under the Creative Commons Attribution License, which permits unrestricted use, distribution, and reproduction in any medium, provided the original work is properly cited.

Citation: Apoorva, M., Vijay K Raghava, Sarita Joshi Narayan, Dr. UmeshYadalam, Sheetal, S. and Fakeha Hareem. 2018. "Inter dental Papilla Management: A Review", *International Journal of Current Research*, 10, (01), 64650-64653.

## INTRODUCTION

The term periodontal plastic surgery was introduced in the late 1980s and consists of a broad range of procedures aiming at correcting or eliminating anatomic, developmental, or traumatic deformities of the gingiva or alveolar mucosa. One of the major esthetic challenges in periodontal plastic surgery is related to the ability of rebuilding lost papillae in the maxillary anterior segment (Miller, 2000). The presence of such interproximal space results in esthetic and phonetic problems. Interdental papillae can be lost as a result of several distinct clinical situations.

#### Corresponding author: Apoorva, M.,

Post graduate student, Department of Periodontics, Sri Rajiv Gandhi College of Dental Sciences and Hospital,, Cholanagar, Hebbal, Bengaluru, Karnataka.

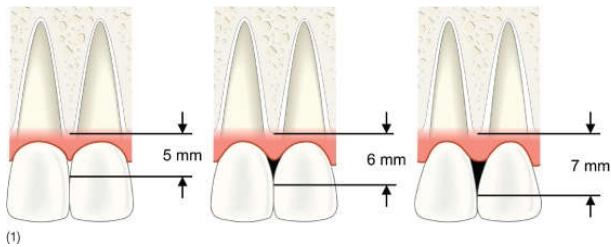
The first in the presence of a naturally occurring midline diastema. This situation can be remedied with orthodontic treatment, positioning the teeth closer together. Diverging roots are another situation that can result in the presence of an interproximal space when the contact point between the two clinical crowns is situated too incisally. Orthodontics may also correct such a clinical situation by aligning the roots and "squeezing" the interproximal soft tissue, thereby creating a new papilla. A clinical crown that tends to be triangular in shape can also result in a partial interproximal space. This happens because of an accentuated discrepancy in the mesiodistal width at the incisal edge and gingival line. Reshaping the clinical crown is helpful in reducing the interproximal opening (McGuire, 1996).

**Definition**

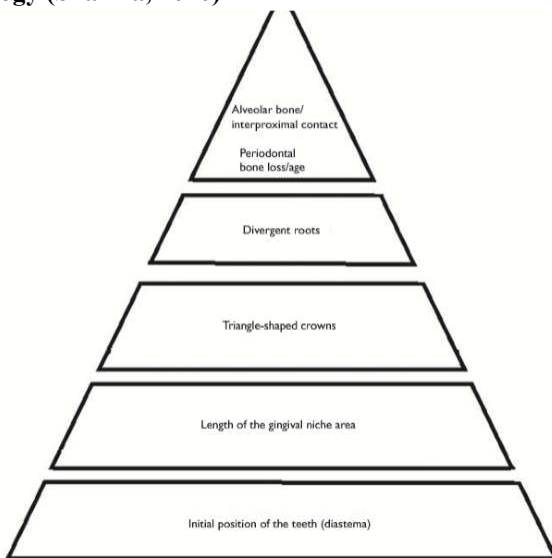
The interdental papilla is defined as the gingival tissue extending from the incisal tip of the papilla to a line tangential to the gingival margins of the two adjacent teeth.

**Morphology of Interdental Papilla**

It depends on (i) the contact relationship between the adjacent teeth, (ii) the distance from the contact point to the crest of the bone, (iii) when the vertical distance from the contact point to the crest of the bone is 5 mm or less, the papilla is present almost 100% of the time (iv) when the distance is 6 mm or more, the papilla is usually missing. The classical study conducted by Tarnow *et al.* (Tarnow *et al.*, 1992) correlated the presence or absence of interdental papilla with the distance between the bone crest and the contact point at 288 interproximal sites in 30 patients. The presence of the papilla was observed in almost 100% of the cases in which the distance was less than or equal to 5 mm, in 56% of cases in which the distance was 6 mm, and only 27% of cases in which the distance was 7 mm or more.



**Etiology (Sharma, 2010)**



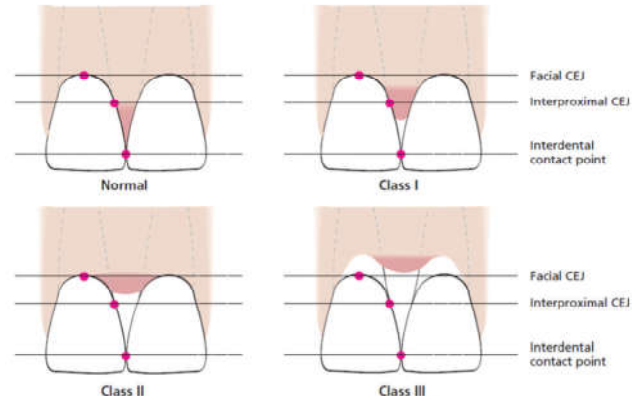
There may be several factors contributing to the loss of papilla height and the establishment of “black triangles” between teeth. The most common reason in the adult individual is a loss of periodontal support due to plaque associated lesions (Shapiro, 1985). However, abnormal tooth shape, improper contours of prosthetic restorations, and traumatic oral hygiene procedures may also negatively influence the outline of the interdental soft tissue.

**Classification of interdental papilla loss**

Nordland and Tarnow (1998) proposed a classification system regarding the papillary height adjacent to natural teeth, based on three anatomical landmarks: The interdental contact point, the apical extent of the facial cemento enamel junction (CEJ),

and the coronal extent of the proximal CEJ (Figure 1). Normal: Interdental papilla fills occupies the entire embrasure space apical to the interdental contact point/area.

- **Class I:** Tip of interdental papilla is located between the interdental contact point and the level of the CEJ on the proximal surface of the tooth
- **Class II:** Tip of interdental papilla is located at or apical to the level of the CEJ on the proximal surface of the tooth but coronal to the level of CEJ mid buccally
- **Class III:** Tip of interdental papilla lies level with or apical to facial CEJ.

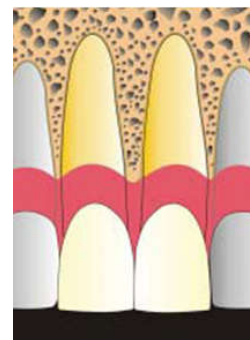


**Figure 1. Classification of interdental papilla loss by Nordland and Tarnow (1998)**

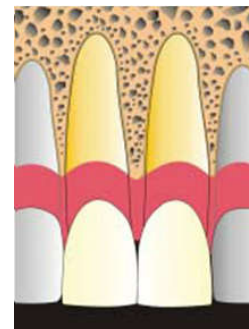
**The Papilla Presence Index (PPI) (Cardaropoli *et al.*, 2004)**

A New System to Assess Interproximal Papillary Levels – proposed by Cardaropoli *et al.* (2004)

- PPI score 1 - Papilla completely present (Fig 2.1)
- PPI score 2 - Apical to contact point (Fig 2.2)
- PPI score 3 - Apical and CEJ visible (Fig 2.3)
- PPI score 4 - Apical to both CEJ. (Fig 2.4)



**Fig 2.1 (left) (PPI 1): Papilla is completely present**



**Fig 2.2 (right) (PPI 2): Papilla is no longer completely present, but interproximal CEJ is not visible.**

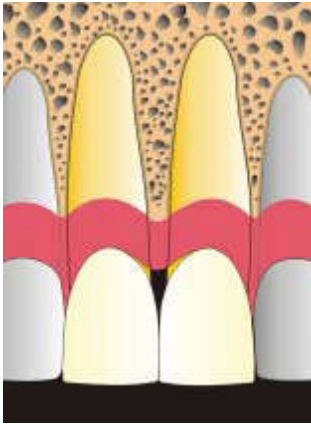


Fig 2.3 (left) (PPI 3): Papilla is no longer completely present, and interproximal CEJ is visible.

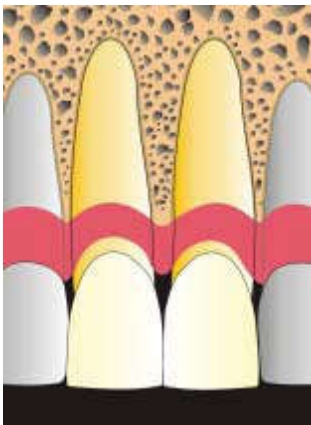


Fig 2.4 (right) (PPI 4): Papilla is no longer completely present, and both interproximal and buccal CEJs are visible.

## TREATMENT

Treatment modalities depend on the following criteria, whether the loss is related to soft tissue damage only or loss caused by severe periodontal diseases with interproximal bone resorption.

### Basic Treatment Modalities

- Surgical method
- Non-surgical method
  - Correction of traumatic oral hygiene habits
  - Prosthetic/restorative approach
  - Orthodontic approach
  - Repeated curettage of the papilla.

### Surgical methods of managing interdental papilla

#### Papilla Recontouring

In the presence of gingival enlargement, the excess tissue should be eliminated to remodel the soft tissue architecture in the case of drug-induced hyperplasia, idiopathic gingival hyperplasia, etc. A gingivectomy may be performed.

#### Papilla reconstruction

##### Surgical Techniques

Several case reports have been published regarding surgical technique for reconstruction of deficient papilla (Beagle 1992,

Han and Takie 1996, Azzi *et al.* 1998). However, the predictability of the various procedures has not been documented, and no data are available in the literatures providing information on the long-term stability of surgically regained interdental papillae. Beagle (1992) described a pedicle graft procedure utilizing the soft tissues palatal of the interdental papilla.

##### Technique

A split thickness flap is dissected on the palatal aspect of the interdental area. The flap is elevated labially, folded and sutured to create the new papilla at the facial part of the interdental area. A periodontal dressing is applied on the palatal aspect only, to support the papilla. Han and Takie (1996) proposed an approach for papilla reconstruction (semilunar coronally repositioned papilla) based on the use of free connective tissue graft (Fig 3).

##### Technique

A semilunar incision is placed in the alveolar mucosa facial to the interdental papilla and a pouch like preparation is performed into the interdental area. Intrasulcular incision is made around the mesial and distal half of the two adjacent teeth to free the connective tissue from the root surface to allow a coronal displacement of the gingival papillary unit. A connective tissue graft, taken from the palate, is placed into the pouch to support the carnally positioned interdental tissue.

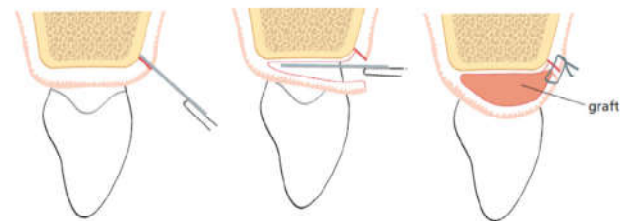
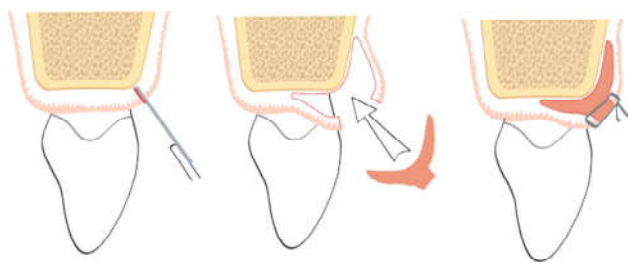


Figure 3. Han and Takie "semilunar coronally repositioned papilla"

Azzi *et al.* (1998) described a technique, in which envelope type flap was prepared for coverage of connective tissue graft. Technique: An intrasulcular incision made at the tooth surface facing the interdental papilla to be reconstructed. Subsequently, an incision placed across the facial aspect of the interdental papilla and an envelope type split thickness flap is elevated into the proximal site as well as apically to and beyond mucogingival line. A connective tissue graft is harvested from the tuberosity area, trimmed to adequate size and shape and placed under the flap in the interdental papillae area; the flaps are brought together and sutured with the connective tissue graft (Fig 4) In 2001, to increase the volume of the interdental tissue additional to the flap described in the aforementioned study, Azzi *et al.* (2001) associated an autogenous bone graft from the region of the maxillary tuberosity with a connective tissue graft from the region of the palate. Conventional surgical techniques are unpredictable because of small working spaces and limited blood supply to the area. Vertical releasing incisions can further jeopardize vascular channels and leave unattractive scarring upon healing. Nordland in 2008 described Microsurgical technique for augmentation of the interdental papilla. The application of microscopes and microsurgical instruments presents a new frontier for predictable esthetic results.



**Figure 4. Azzi et al envelop flap technique**

The above techniques showed that using an interposed subepithelial connective tissue graft can regenerate lost interdental papilla, and the reconstructed papilla remained stable and without any clinical signs of inflammation for 4 years after surgical procedure, but the long-term survivability and the technique sensitivity involved in the surgery to be considered. In the case of implant therapy, the absence of interimplant papillae impairs esthetics. Some attempts have been proposed in the literature to recreate the scalloped and positive architecture of the soft tissue around implants (Palacci et al., 1995). One novel technique consists of buccal dislodgment of a full-thickness flap raised from a site slightly more palatal with respect to the implants. To ensure and stabilize the most coronal position of the flap, the ramp mattress suture technique is performed. This new suturing approach provides a coronal pulling traction, whereas the palatal flap receives compression on its underlying layers. After 4 to 5 weeks, a vestibular scalloped gingivectomy is performed in correspondence to the vestibular surface of the abutments to create a positive architecture of the gingival margin.

### Conclusion

The etiology of the gingival black space is multifactorial and it is important to diagnose properly the etiologic factor for establishing an appropriate treatment planning. However, the treatment approaches are not predictable and further studies are needed to recommend the clinical practices available to date.

### REFERENCES

Azzi R, Etienne D, Carranza F. 1998. Surgical reconstruction of the interdental papilla. *Int J Periodontics Restorative Dent.*, 18:467–474.

- Azzi R, Takei HH, Etienne D, Carranza F. 2001. Root coverage and papilla reconstruction using autogenous osseous and connective tissue grafts. *Int J Periodontics Restorative Dent.*, (21):141-7.
- Beagle JR. 1992. Surgical reconstruction of the interdental papilla. Case report. *Int J Periodontics Restorative Dent.*, 12: 145–151.
- Cardaropoli D, Re S, Corrente G. 2004. The Papilla Presence Index (PPI): A new system to assess interproximal papillary levels. *Int J Periodontics Restorative Dent.*, 24:488-92.
- Han TJ, Takei HH. 2000. Progress in gingival papilla reconstruction. *Periodontol* 1996;11:65–68.
- McGuire MK, Miller L. 1996. Maintaining esthetic restorations in the periodontal practice. *Int J Periodontics Restorative Dent.*, 16:230-9.
- Miller PD Jr, Allen EP. 2000. The development of periodontal plastic surgery. *Periodontol* 1996;11:7-17.
- Nordland WP, Sandhu HS, Perio C. 2008. Microsurgical technique for augmentation of the interdental papilla: Three case reports. *Int J Periodontics Restorative Dent.*, 28:543-9.1
- Nordland WP, Tarnow DP. 1998. A classification system for loss of papillary height. *J Periodontol.* 69(10):1124-6.
- Palacci P, Ericsson I, Engstrand P, Rangert P. 1995. Peri-implant soft tissue management: Papilla regeneration technique. In *Optimal Implant Positioning and Soft Tissue Management for the Brånemark System*. Chicago: Quintessence, 59–70.
- Shapiro A. 1985. Regeneration of interdental papillae using periodic curettage. *Int J Periodontics Restorative Dent.*, 5:26-33.
- Sharma AA, Park JH. 2010. Esthetic considerations in interdental papilla: remediation and regeneration. *J Esthet Restor Dent.*, (22):18-30.
- Tarnow D, Magner AW, Fletcher P. 1992. The effect of the distance from the contact point to the crest of bone on the presence or absence of interproximal dental papilla. *J Periodontol.* 63(12):995-6.

\*\*\*\*\*