



RESEARCH ARTICLE

ROOT CANAL CONFIGURATION OF PERMANENT MAXILLARY FIRST PREMOLARS
IN CUDDALORE DISTRICT, TAMILNADU

¹Dr. Rajaraman Gangadharan, ²Dr. Raghu K., ³Dr. Arivunithi K., ⁴Dr. Selvakumar, S.R.,
⁵Dr. Bhavani Sri Krishna Pillai and ⁶Dr. Jeyapreetha Pavunraj

¹Assistant Professor, Department of Conservative Dentistry and Endodontics Rajah Muthiah Dental College and Hospital, Annamalai University, Annamalai Nagar, Chidambaram, Tamilnadu

²Reader, Department of oral and maxillo facial surgery, Indira Gandhi Dental College and Hospital, Sri Balaji Vidyapeeth Institute, Puducherry

³Rajah Muthiah Dental College and Hospital, Annamalai University, Annamalai Nagar, Chidambaram, Tamilnadu

⁴Assistant professor, Department of oral and maxillo facial surgery, Rajah Muthiah Dental College and Hospital, Annamalai University, Annamalai Nagar, Chidambaram, Tamilnadu

⁵Lecturer, Department of conservative dentistry and endodontics, Rajah Muthiah Dental College and Hospital, Annamalai University, Annamalai Nagar, Chidambaram, Tamilnadu

⁶Oral Pathologist, Le Pearl Multispeciality Dental clinic, Indira Nagar, Neyveli, Tamilnadu

ARTICLE INFO

Article History:

Received 19th December, 2017
Received in revised form
17th January, 2018
Accepted 23rd February, 2018
Published online 30th March, 2018

Key words:

Root Canal Configuration,
Clearing Method, Dye, Decalcification.

ABSTRACT

Dental caries with pulpal involvement is a painful condition. In order to eliminate pain, pulp should be extirpated completely, although due to different configuration it remains difficult. This study aims to understand the various types of root canal configuration of maxillary first premolars in Cuddalore district, Tamilnadu based on the independent epidemiological studies. In order to understand the pattern of root canals, a set of 150 orthodontic extracted teeth was collected and its root canal configuration was studied using clearing method (Sharadha Gupta, 2015). Then with the help of dye its root canal configuration was made visible and studied. According to Vertucci's classification 1984 among the sample, single root where seen in 82.74%, double root where seen in 16.1% and three root where seen in 1.16% of sample. In single rooted teeth type IV is the most common type of root canal configuration seen in 38.04% of sample followed by type II in 21.24%. In double rooted tooth buccal root shows 6.3% followed by type III, and palatal root shows 7.5% of type I followed by type III, 2%. In triple rooted teeth 1.16% of type I in mesiobuccal root, 1.16% type VI in distobuccal root and 1.16% of type I were seen in palatal root. From the results type IV root canal configuration is the most common type configuration among the permanent maxillary first premolars in Cuddalore district, Tamil Nadu.

Copyright © 2018, Rajaraman Gangadharan et al. This is an open access article distributed under the Creative Commons Attribution License, which permits unrestricted use, distribution, and reproduction in any medium, provided the original work is properly cited.

Citation: Dr. Rajaraman Gangadharan, Dr. Raghu K., Dr. Arivunithi K., Dr. Selvakumar S.R., Dr. Bhavani Sri Krishna Pillai and Dr. Jeyapreetha Pavunraj, 2018. "Root canal configuration of permanent maxillary first premolars in Cuddalore District, Tamilnadu", *International Journal of Current Research*, 10, (03), 67046-67049.

INTRODUCTION

The prevalence of caries with pulpal involvement in developing countries is increasing rapidly due to loss of infrastructure and lack of trained personnel. In order to make the treatment of caries through knowledge about the canal configuration and exact morphology of root should be studied. Since India is one of the developing countries, people are more prone for caries with pulpal involvement.

*Corresponding author: Arivunithi, K,

³Rajah Muthiah Dental College and Hospital, Annamalai University, Annamalai Nagar, Chidambaram, Tamilnadu.

For which root canal treatment is one of the prime treatment of choice. For the excellent prognosis of the treatment the pulpal tissue should be extirpated completely and canal should be cleaned, shaped and obturated completely. The study is about the root canal configuration in Maxillary first premolar which varies from single fused root with single canal to three roots with three canals with various configurations from the set of samples collected from various places of Cuddalore district, Tamil Nadu, which aids in the treatment of maxillary premolars. Even though many studies have been done on the same topic in different places this study is aimed about the group of localized people in Cuddalore district and to compare

the study with the other results. This study helps to understand the canal configuration, morphology of maxillary premolars by providing three dimensional model of tooth and also it is used for preclinical study, for demonstration of root canal treatment to patients. It also helps for research in the field of Endodontics for the invention of new methods and technology thereby improving the treatment modalities.

METHODS AND METHODOS

A set of 150 orthodontic extracted permanent maxillary first premolars are randomly collected from Cuddalore district, Tamilnadu (Fig. 1). Teeth with incompletely formed root, caries, restorations and fractured tooth are not included.

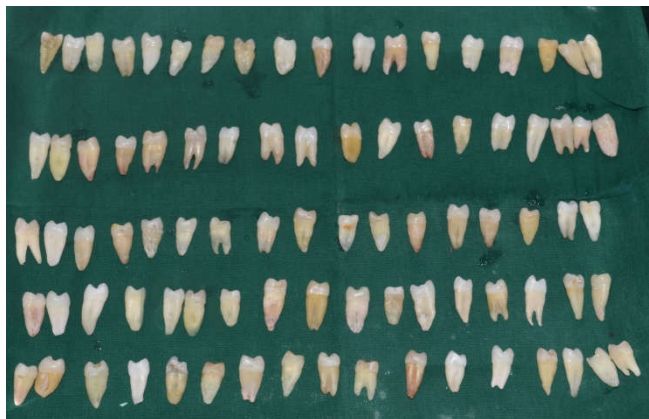

Figure 1. A set of 150 orthodontic extracted teeth

Teeth are stored in water or 10% formalin and they are cleaned completely by removing calculus and debris. Access cavities are prepared with round bur and no.8 size file is used to confirm access opening without damaging the root canal configuration and then stored in 5% sodium hypochlorite solution for 48 hours which is changed every 24 hours to remove any organic debris followed by flushing in running tap water and its apical patency is confirmed by emergence of water from apical opening when water is forced through access opening with syringe. The samples are placed in 10% nitric acid for 24 hours and then in 25% nitric acid for another 24 hours for the purpose of decalcification. The completion of decalcification is confirmed by piercing the needle in crown portion followed by flushing in running tap water for 1 hour. The samples are dehydrated by placing the sample in 80% ethanol for overnight followed by 90% ethanol for 1 hour and then in 100% ethanol for 3 times each 1 hour (Fig 2)

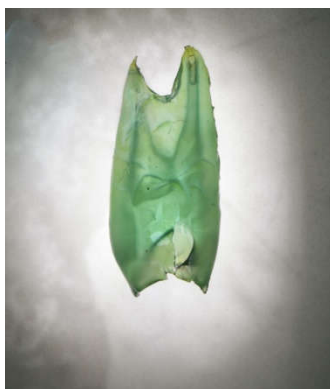

Figure 2. Tooth became cleared after treating with methyl salicylate

Then they are placed in methyl salicylate for 24 hours for clearing the sample (Fig 2). A tooth can stored in methyl salicylate for infinite period of time and then non-alcoholic dye is injected into the canal with cryojet syringe and root canal configuration is studied with naked eye (Fig 3, 4, 5).

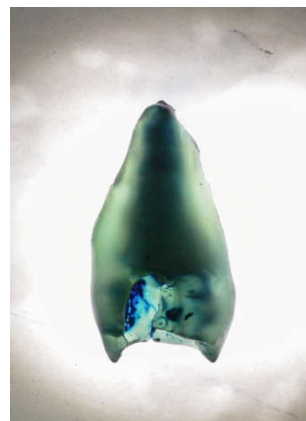


Figure 3. Type I root canal configuration visualized after insertion of dye




Figure 4. Type III root canal configuration visualized after insertion of dye



Figure 5. Type IV root canal configuration visualized after insertion of dye

The canal configuration were categorized into seven types by Vertucci in 1984 (7) as follows (Fig 3)

- **Type I:** It appear as single canal from pulp chamber to apex.
- **Type II:** It appear as two separate canals at the pulp chamber and join at short of the apex to form one canal with one apical opening.

- **Type III:** It appear as one canal at the level of the pulp chamber and divides into two within the root, and merges to exit as single canal.
- **Type IV:** It appears as two separate and distinct canals from the pulp chamber to the apex.
- **Type V:** It appear as Single canal at the level of the pulp chamber then divides into two separate canals with two separate apical foramina at the apex.
- **Type VI:** It appear as two separate canals at the level of pulp chamber and then join at the midpoint and divide again in to two separate canals with two separate apical foramina at the apex
- **Type VII:** It appear as one canal at the level of the pulp chamber then divides and rejoins within the canal, and finally redivides into two distinct canals short of the apex.
- **Type VIII:** It appear as three separate canals from the pulp chamber to apex

RESULTS

By this study we understood that single root were seen in 82.74% of sample, double root in 16.1% of sample and three roots in 1.16% of sample. In single rooted teeth vertucci's type IV is the most common type of root canal configuration seen in 38.04% of sample followed by vertucci's type II in 21.24% of sample, vertucci's type III in 11.2% of sample, vertucci's type V in 5.5% of sample, vertucci's type I in 5.6% of sample, vertucci's type VII in 1.16% of sample are seen. In double rooted tooth buccal root shows 6.3% of vertucci's type I, 3.7% of vertucci's type II, 4.6% of vertucci's type III, 1.5% of vertucci's type V and palatal root shows 7.5% of vertucci's type I 2.2% of vertucci's type II, 3.4% of vertucci's type III, 2% of vertucci's type IV, 1% of vertucci's type V. in triple rooted teeth 1.16% of vertucci's type I in mesiobuccal root, 1.16% vertucci's type VI in distobuccal root and 1.16% of vertucci's type I were seen in palatal root (Table 1). Vertucci's type VI and type VIII is not seen in single tooth among the sample. These results are confined to Cuddalore district, Tamil Nadu.

DISCUSSION

This study reveals about the root canal configuration of permanent maxillary first premolars in Cuddalore district, TamilNadu. Even though there are many methods available for studying root canal configuration, clearing technique provides detailed information about the sample. This method avoids instrumentation of canals and also avoids damage to the canal configuration while maintaining original form and pattern of canals. It also provides three dimensional view of the canal. The tooth was decalcified carefully with nitric acid with controlled action and dehydrated slowly with ethanol to avoid rapid shrinkage of sample and cleared with methyl salicylate to increase the refractive index of the tooth to make the sample transparent. Maxillary first premolar can show single root to three roots with various root canal configurations. According to the study, occurrence of three canals in maxillary first premolar varies from 0.5% to 7.5% (Pineda, 1972). Vertucci (Vertucci, 1979) reported all the VIII type of canals in maxillary first premolars. We found single root in 82.74% of sample which is higher than that of north indian population where the reported incidence was 53.6%. Two root form in 16.1% and three root form in 1.16% which is almost same as

the north Indian population (Sharaddha Gupta *et al.*, 2015). Type IV is seen most commonly followed by Type II. Type I and Type VII are lesser than those reported in north Indian population, where the incidence is 23.3% and 4% (Sharaddha Gupta *et al.*, 2015). Whereas Type II and Type IV are higher than those in north Indian population (Sharaddha Gupta *et al.*, 2015) where the incidence is 14.8% and 33.2%. Type III and Type V remains almost same as in north Indian population (Sharaddha Gupta *et al.*, 2015).

Conclusion

The root canal morphology of permanent maxillary first premolar in Cuddalore district, Tamilnadu shows a higher incidence of vertucci's type IV configuration. The finding of a rare type, namely Type VII were also seen. Hence the dentist should always be aware about the chances of presence of an additional canal.

REFERENCES

- Al-Nazhan S. 1991 maxillary second premolar with three canals. *Saudi Dent J.*3, 18-20.
- Awawdeh LA, Al-Qudah AA. 2008. Root form and canal morphology of mandibular premolars in a Jordanian population. *Int Endod J.*41, 240-248.
- Bellizzi R, Hartwell G. 1985. Radiographic evaluation of root canal anatomy of in vivo endodontically treated maxillary premolars. *J Endod.*11, 37-39.
- Berkan Celikten, Kaan Orhan, Umut Aksoy, Pelin Tufenkci, Atakan Kalender, Fatma Basmaci & Pervin Dabaj. 2016. Cone beam CT evaluation of root canal morphology of maxillary and mandibular premolar in Turkish population. *BD Jopen.* 2, 15006.
- Bulut DG, Kose E, Ozcan G, Sekerci AE, Canger EM, Sisman Y. 2015. Evaluation of root morphology and root canal configuration of premolars in the Turkish individuals using cone beam computed tomography. *Eur J Dent.*9,551-7.
- Caliskan MK, Pehlivan Y, Sepetcioglu F, Turkun M, Tuncer S. 1995. Root canal morphology of human permanent teeth in a Turkish population. *J Endod.*21, 200-204
- Frank J. vertucci. 2005. Root canal morphology and its relationship to endodontic procedures. *Endodontic topics.*10, 3-29
- Ibrahim Ali Ahmad 2015. Root and root canal morphology of Saudi Arabian permanent dentition. *Saudi endodontic journal.*5, 99-106.
- KartalN, Ozcelik B, Cimilli H. 1998. root canal morphology of maxillary premolars. *J Endod.*24, 417-419.
- Lu TY, Yang SF, Pai SF. 2006. Complicated root canal morphology of mandibular first premolar in a Chinese population using the cross section method. *J Endod.*32, 932-936.
- Pineda, F., Kuttler, Y. 1972. Mesiodistal and buccolingual roentgenographic investigation of 7,275 root canals. *Oral surg Oral Med Oral Pathol.* 33, 101-110.
- Sharaddha Gupta, Dakshita joy Sinha and Subhash Gupta. 2015. Root and canal morphology of maxillary first premolar teeth in north Indian population using clearing technique: an in vitro study. *J conserves dent.*3, 232-6.
- Shivaapathasundharam B, Einstein Thiruselvan Berti A. 2000. Transparent tooth model system. an aid in the study of root canal anatomy. *Indian J Dent Res.*11, 89-94.

Vertucci FJ. 1984. Root canal anatomy of the human permanent teeth. *Oral surgery oral medicine and oral pathology*. 58, 588-99.

Vertucci, F.J., Gegauff, A. 1979. Root canal morphology of the maxillary first premolar. *J Am Dent Assoc*. 99, 194-198.
