



CASE STUDY

WHAT NOT TO BE DONE IN A BILATERAL MANDIBULAR ANGLE FRACTURE- A CASE REPORT

¹Dr. Raghu K, ²Dr. Alaguvel Rajan M, and ³Dr. Ramsay Muthukumar

¹Department of oral and Maxillo facial Surgery, Indira Gandhi Dental College and Hospital, Sri Balaji Vidyapeeth Insitute, Puducherry, India

²Department of oral and Maxillo Facial Surgery, Rajas Dental College and Hospital, Tamil Nadu, India

³Department of Oral and Maxillo facial Surgery, Sri Venkateswara Institute of Dental Science, Chennai, Tamil Nadu, India

ARTICLE INFO

Article History:

Received 11th January, 2018

Received in revised form

18th February, 2018

Accepted 13th March, 2018

Published online 30th April, 2018

ABSTRACT

Bilateral mandibular angle fracture is one of the common fractures that occur in a Road traffic accident. In which intra oral plating is always challenging when it comes to impacted third molar in the line of fracture that interferes the treatment plan whether to remove the tooth or not? In our case report the third molar in the line of fracture is not removed at the time of surgery but plating done over the tooth in the fracture line planned for second surgery at the later stage, to remove the plate along with the tooth.

Key words:

Angle fracture, impacted molar, plating.

Copyright © 2018, Dr. Raghu et al. This is an open access article distributed under the Creative Commons Attribution License, which permits unrestricted use, distribution, and reproduction in any medium, provided the original work is properly cited.

Citation: Dr. Raghu, K., Dr. Alaguvel Rajan, M. and Dr. Ramsay Muthukumar. 2018. "What not to be done in a bilateral mandibular angle fracture- a case report", *International Journal of Current Research*, 10, (04), 67770-67773.

INTRODUCTION

This report presents the clinical presentation and management of a 16 year old male patient with a bilateral mandible fracture alone with right Radius fracture of forearm and Fibula fracture in a road traffic accident, in which age have a important role in placing extra oral incision in face considering the patients age and post operative scar. After the incident patient reported a private multispecialty hospital with the complaint of painful lower jaw region alone with right hand and legs with abrasion wounds. Treatment for fracture Radius and Fibula was done along side when doing mandibular angle fracture correction. On examination patient was unable to open the mouth with mild deviation, extra orally step deformity was present in both side of the mandibular angle region and tenderness. Intra orally occlusion de-arranged with segmental mobility and anterior open bite was present. Radio-logical Examination Computer tomography (CT) 3D was taken (Fig.1) that demonstrates displaced fracture of right and left mandibular angle region. OPG (Orthopantomogram) & Sag-ital cut in CT (Fig. 2, 3)

confirmed the fracture along the added information of impacted third molar bilaterally present in the line of mandibular angle fracture. Under LA local anaesthesia maxillary and mandibular arch bar was placed, and the patient was posted under GA general anaesthesia for reduction and fixation Fig. 2 & 3 CT & OPG both confirms displaced mandibular angle fracture with impacted 3rd molar bilaterally Incision was made on the anterior border of the ramus intra orally on the lateral aspect over the external oblique ridge to the vestibular depth till the mandibular 2nd molar both the side. Full thickness mucoperiosteal flap reflected were the fracture sight is identified (Fig. 4, 5) showing bilateral mandibular angle fracture. Maxillary mandibular fixation (Fig. 6) done using 26 gauge wire to achieve occlusion. Fracture reduction done using 4 hole with gap titanium plate and 2* 8 mm titanium screw both sides just above the oblique ridge that didn't miss the impacted molars (Fig. 7, 8). Closure done using 3.0 vicryl.

DISCUSSION

Bilateral mandibular angle fracture is one of the most common fractures that occur during a trauma to the face. Many article is available in managing the fracture, however very little is available in managing the difficulties in young patients with

*Corresponding author: Dr. Raghu, K.

Department of oral and maxilla facial surgery, Indira Gandhi Dental College and Hospital, Sri Balaji Vidyapeeth Insitute, Puducherry.

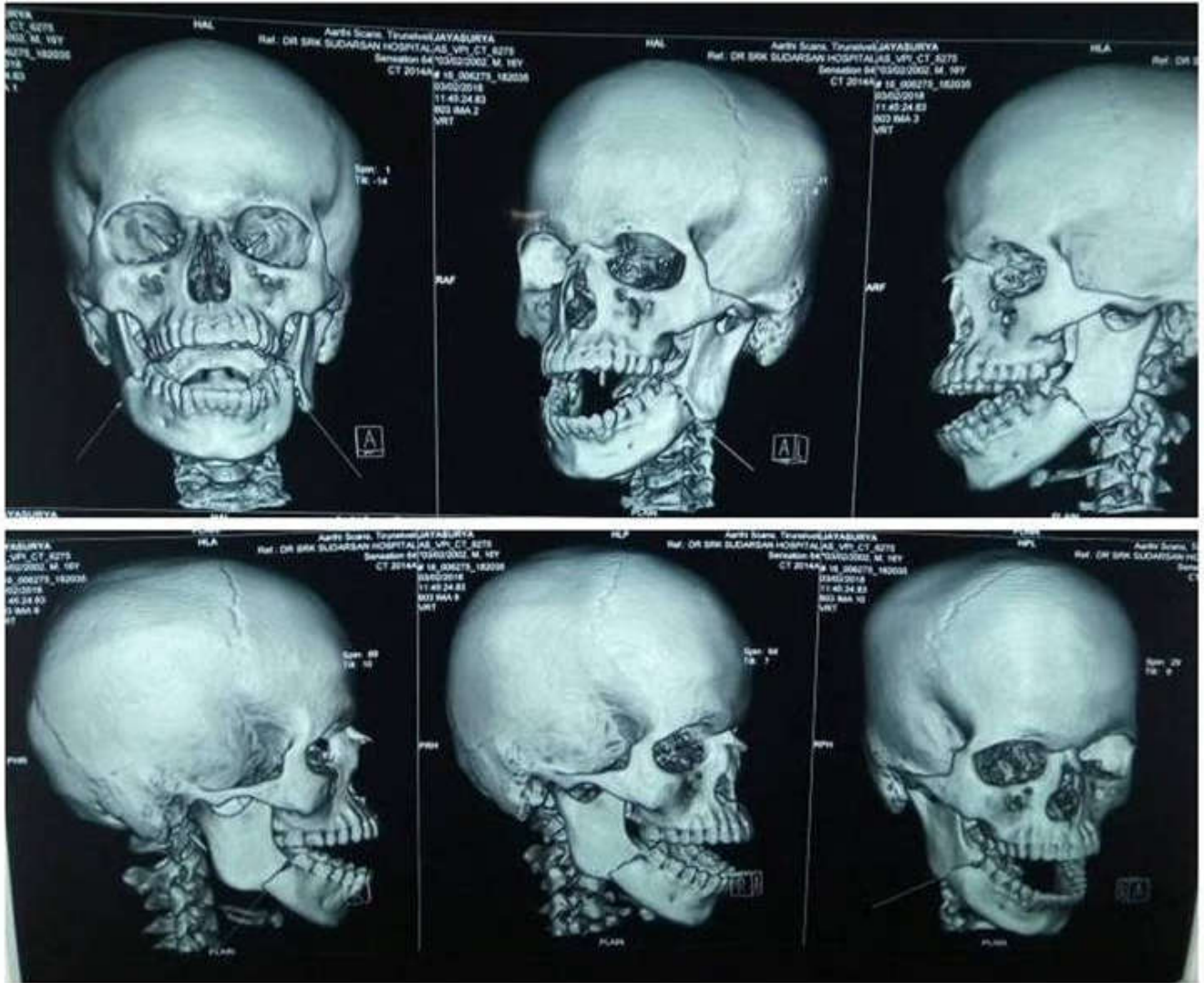


Fig. 1

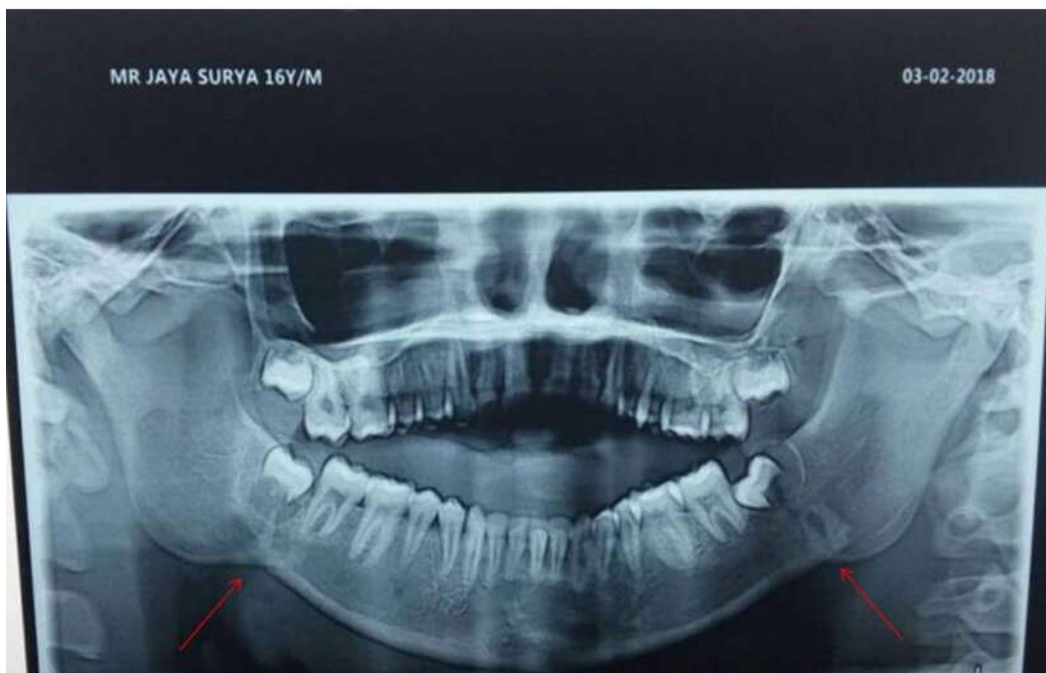


Fig. 2

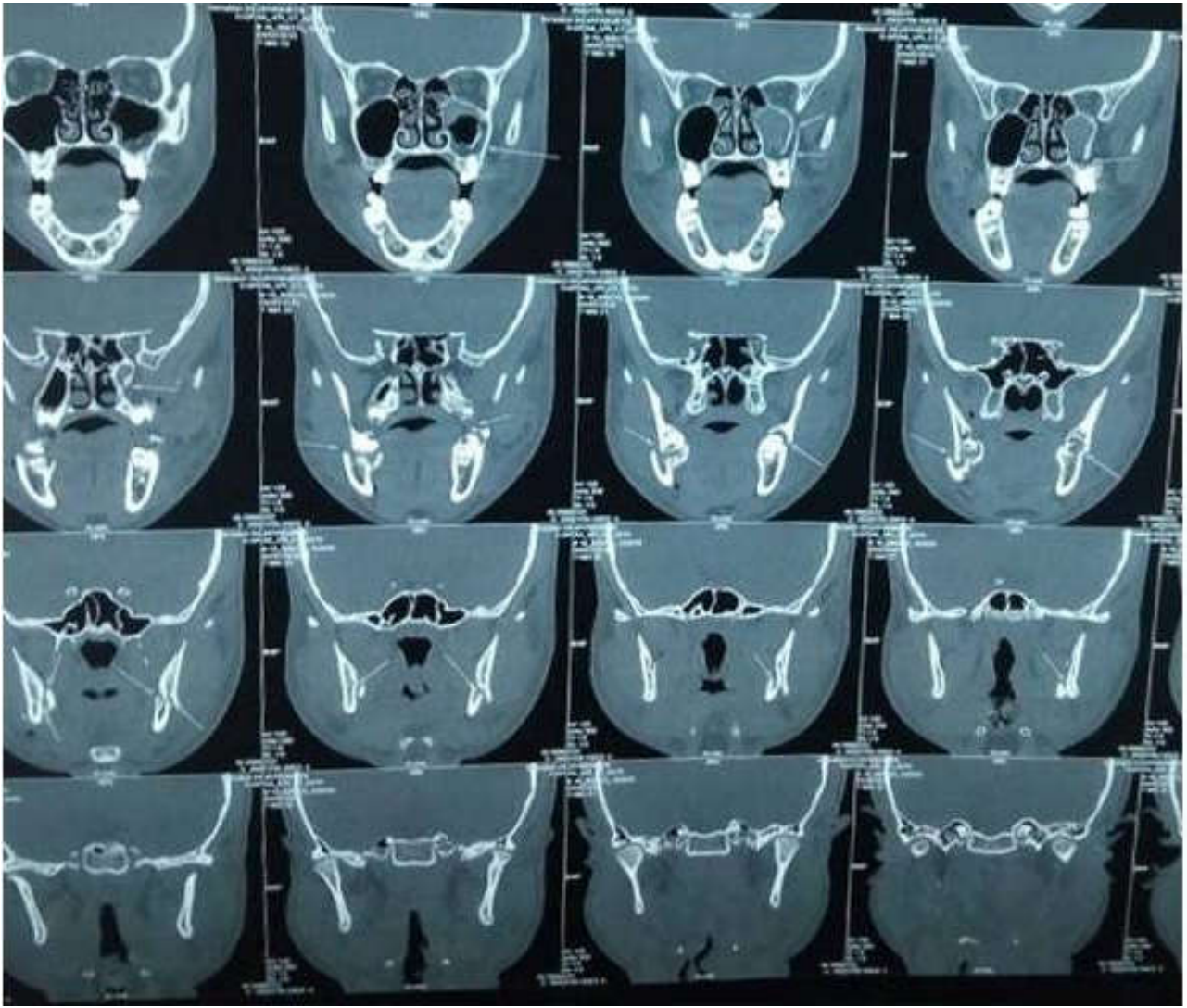

Fig. 3.

impacted third molar at the line of fracture and how not to plate a angle fracture. When doing a surgery in trauma, Facial development, fracture continuity and occlusion achievement is very important goal for a surgeon. Intra oral or extra oral incision isn't matters always. But considering patient's aesthetics intra oral incision is placed even after noticing the impacted tooth in the line of fracture planning in removing the impacted tooth which was unfortunate in the surgery table.

Main difficulty is to plan the surgery that avoids the impacted molar while plating, which was a challenge but intra-operatively if the impacted molar was to be removed at the first place there was a high change of fracture displacement and to sacrifice the occlusion. Considering this scenario plating was done over the oblique ridge both side over the impacted tooth (Fig.9) to achieve the occlusion and fracture angle continuity.

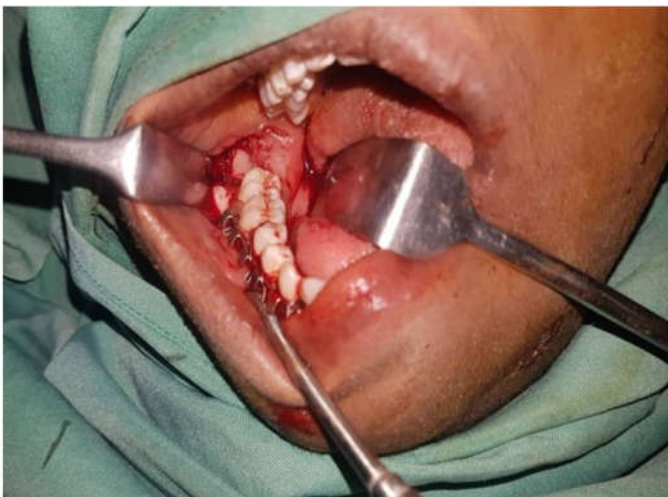

Fig. 4

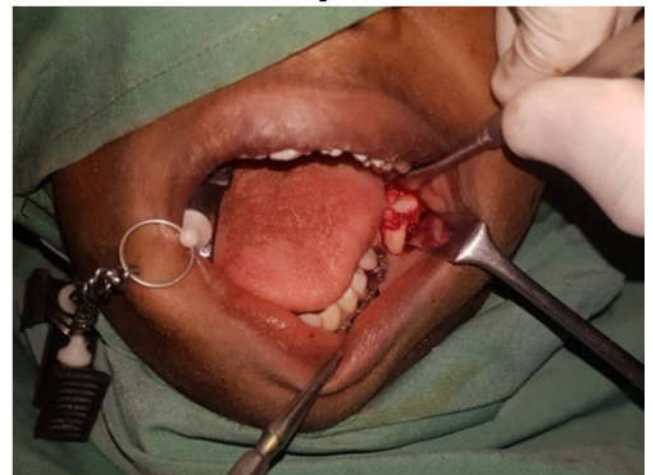

Fig. 5

Fig. 4, 5 shows both right and left mandibular angle fracture

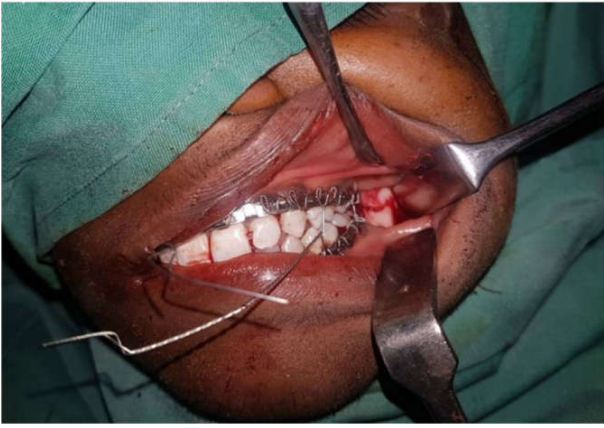

Fig. 6

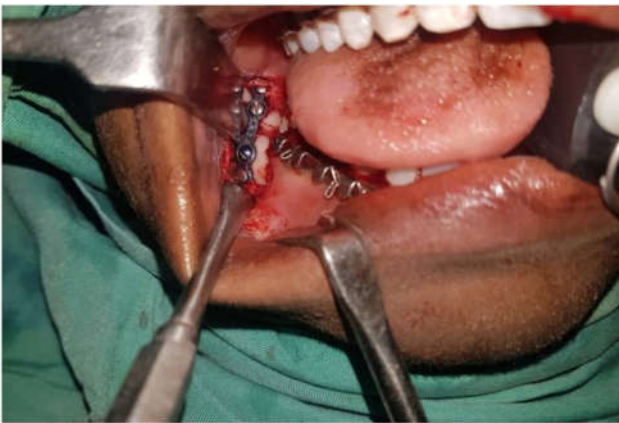


Fig. 7

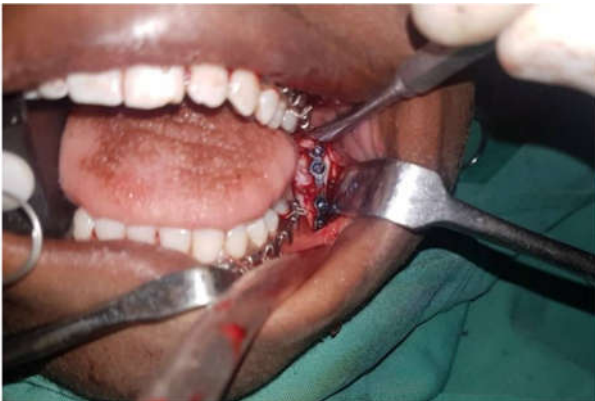

Fig. 8

Fig. 7, 8 Intra operative plating bilaterally

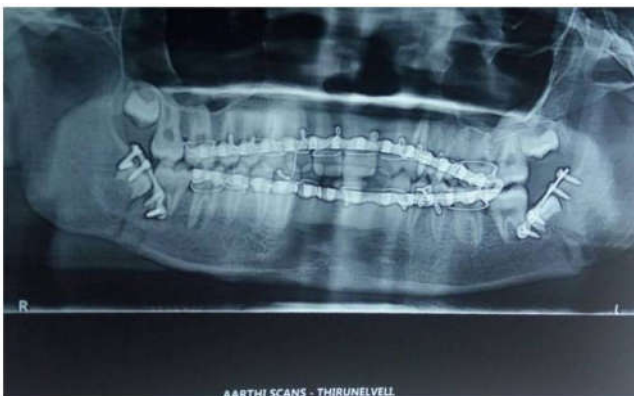

Fig. 9 post operative OPG shows plating over the impacted tooth

Second surgery was planned after few months to remove the impacted tooth and plates once the bone ossification is complete. However this kind of procedure is usually not advised, but in few case were few compromises has to be done in achieving our surgical goal to maintain the mandibular continuity and occlusion. This is a case report of that kind showing what not to be done.

REFERENCE

- Ayali, A. and Erkmén E. 2017. Biomechanical Evaluation of Different Plating Methods Used in Mandibular Angle Fractures with 3-Dimensional Finite Element Analysis: Favorable Fractures. *J Oral Maxillofac Surg*, Jul; 75(7):1464-1474. doi: 10.1016/j.joms.2017.02.028. Epub 2017 Mar 14.
- Ayali, A. and Erkmén, E. 2018. Three-Dimensional Finite Element Analysis of Different Plating Techniques for Unfavorable Mandibular Angle Fractures. *J Craniofac Surg*, 2018 Feb 6. doi: 10.1097/SCS.00000000000004327. [Epub ahead of print]
- Bouchard, C. and Mansouri, M. 2017. Open Reduction with Internal Fixation of Mandibular Angle Fractures: A Retrospective Study. *J Can Dent Assoc*, Jan; 82:h3.
- Chen, CL., Zenga, J., Patel, R. and Branham, G. 2018. Complications and Reoperations in Mandibular Angle Fractures. *JAMA Facial Plast Surg*, Jan 4. doi: 10.1001/jamafacial.2017.2227. [Epub ahead of print]
- Christensen, BJ., Mercante, DE., Neary, JP. and King, BJ. 2017. Risk Factors for Severe Complications of Operative Mandibular Fractures. *J Oral Maxillofac Surg*, Apr; 75(4):787.e1-787.e8. doi: 10.1016/j.joms.2016.12.003. Epub 2016 Dec 11.
- Oruç, M., Işık, VM., Kankaya, Y., Gürsoy, K., Sungur, N., Aslan, G. and Koçer, U. 2016. Analysis of Fractured Mandible Over Two Decades. *J Craniofac Surg*. Sep; 27(6):1457-61. doi: 10.1097/SCS.00000000000002737.
- Patel, N., Kim, B. and Zaid, W. 2016. A Detailed Analysis of Mandibular Angle Fractures: Epidemiology, Patterns, Treatments, and Outcomes. *J Oral Maxillofac Surg*, Sep; 74(9):1792-9. doi: 10.1016/j.joms.2016.05.002. Epub 2016 May 13.
- Rastogi, S., Paul, S., Kukreja, S., Aggarwal, K., Choudhury, R., Bhugra, A., Indra, B NP. and Jawaid, M. 2017. Treatment of Mandibular Angle Fractures with Single Three-Dimensional Locking Miniplates without Maxillomandibular Fixation: How Much Fixation Is Required? *Craniofac Trauma Reconstr*. Sep; 10(3):188-196. doi: 10.1055/s-0037-1600904. Epub 2017 Mar 29.
- Sipahi Calis, A., Efeoglu, C. and Koca, H. 2017. The effect of teeth in mandibular fracture lines. *Dent Traumatol*. Jun; 33(3):194-198. doi: 10.1111/edt.12322. Epub 2017 Feb 23.
- Spinelli, G., Lazzeri, D., Arcuri, F., Valente, D. and Agostini, T. 2016. Management of Mandibular Angle Fractures by Two Conventional 2.0-mm Miniplates: A Retrospective Study of 389 Patients. *Craniofac Trauma Reconstr*. Sep; 9(3):206-10. doi: 10.1055/s-0036-1582457. Epub 2016 Apr 14.