



ISSN: 0975-833X

Available online at <http://www.journalcra.com>

INTERNATIONAL JOURNAL  
OF CURRENT RESEARCH

International Journal of Current Research  
Vol. 11, Issue, 01, pp.140-143, January, 2019

DOI: <https://doi.org/10.24941/ijcr.29800.01.2019>

## CASE REPORT

### MITRAL VALVE THROMBOSIS DURING PREGNANCY: FAVOURABLE COURSE OF ANTICOAGULATION THERAPY

Bachif, M., Ofkir, M., Aissaoui, H., Ismaili, N. and El ouafi, N.

Department of cardiology, Mouhamed 6 University hospital, Oujda, Morocco

#### ARTICLE INFO

##### Article History:

Received 17<sup>th</sup> October, 2018  
Received in revised form  
16<sup>th</sup> November, 2018  
Accepted 24<sup>th</sup> December, 2018  
Published online 30<sup>th</sup> January, 2019

##### Key Words:

Prosthetic valve thrombosis,  
Anticoagulation, pregnancy.

#### ABSTRACT

The Pregnant patients with a prosthetic mechanical valve are at high risk for valve thrombosis and the optimal treatment strategy in the pre-pregnancy period and during pregnancy itself is a matter of debate. Prosthetic heart valve (PHV) thrombosis is a rare condition with serious life-threatening complications diagnosed optimally by TOE followed by a radio-cinema; and which needs to be reevaluated frequently by echocardiography transthoracic in case of an increase in trans valvular gradient. We report here a case of a 37-year-old woman, pregnant at 31 weeks of amenorrhea, with a double mitro-aortic mechanical replacement suspected dysfunction in front of an increase of trans-valvular gradient and confirmed on the radio cinema. The patient was treated with a low molecular weight heparin (LMWH); acetylsalicylic acid 160 mg daily; and oral anticoagulation (Acenocoumarol) with great clinical and biological results. In some cases; Pregnant patients with prosthetic valve thrombosis may be treated surgically, or with prolonged infusions of low-dose TPA. Repeated doses of low TPA can be administered at low doses.

Copyright © 2019, Bachrif et al. This is an open access article distributed under the Creative Commons Attribution License, which permits unrestricted use, distribution, and reproduction in any medium, provided the original work is properly cited.

Citation: Bachrif, M., Ofkir, M., Aissaoui, H., Ismaili, N. and El ouafi, N., 2019. "Mitral valve thrombosis during pregnancy: Favourable course of anticoagulation therapy", *International Journal of Current Research*, 11, (01), 140-143.

## INTRODUCTION

Pregnant patients with a prosthetic mechanical valve are at high risk for valve thrombosis (McGhee, 1998). Numerous pregnancy studies in women with mechanical prostheses have shown that patients who use war far in during pregnancy have a thromboembolic event incidence of 3.9% and maternal mortality of 2%, whereas Patients who used unfractionated heparin during the first trimester followed by warfarin during their 2nd and 3rd trimesters had a thromboembolic event incidence of 9.2% and a maternal mortality rate of 4%. Most of these deaths are related to prosthetic valve thrombosis (North, et al., 1999), the treatment of which is still a subject for debate. We report the case of a 37-year-old woman, pregnant at 31 weeks of amenorrhea, with a double mitro-aortic mechanical replacement suspected dysfunction in front of an increase of trans-valvular gradients and confirmed on the radio cinema. The patient received anticoagulant therapy (AVK + LMWH) and platelet antiaggregant with good progress. This is a 37-year-old patient, followed since the age of 14 years for rheumatic valve disease, having benefited from a double mitro-aortic replacement by mechanical prosthesis 7 years ago, put under medical treatment based on: Avlocardyl 40mg (20 mg per day), Acenocoumarol (1mg per day).

With good clinical evolution. Ancient pregnancy well followed, delivered at 32Th with concept of the death of the new born to J6 of life. She is currently presenting for pregnancy at 31 AW for routine follow-up. The examination found a patient who was conscious, hemodynamically and respiratory stable, without signs of heart failure nor inflammatory. Blood assessment: INR = 2.8, HB at 11.5g / dl. The ECG is in a regular sinus rhythm with a heart rate of 75ppm, no parietal hypertrophy or conduction disorder. A trans-thoracic ultrasound was performed showing a mechanical prosthesis in the double-finned mitral position with a blade lock, with a mean gradient at 17 mmHg, and a mechanical prosthesis in the aortic position with a double aperture fin, which appeared to be limited but without true blockage of wings with a mean gradient at 81 mmHg, and a PAH at 70mmHg, a non-dilated slightly hypertrophied LV of good systolic function and an unexplained RV of good systolic function. The TOE showed a blockage of a mitral wing and typical image of thrombus, the wings of the aortic prosthesis open but appear of limited opening. The cinema radio objectified a still wing at the level of the mitral prosthesis, 2 mobile wings at the level of the aortic prosthesis. An obstetrical ultrasound was performed showing an active monofetalous pregnancy in the seat presentation with gestational age at 31 weeks + 6 days with a PFE at 2742 g. The patient was treated with: Avlocardyl, Sintrom alternating 3 mg and 4 mg, Kardegic 160mg; oral iron, Lovenox at starting, in addition to two courses of prednisolone.

\*Corresponding author: Bachif, M.,

Department of cardiology, Mouhamed 6 university hospital, Oujda, Morocco.

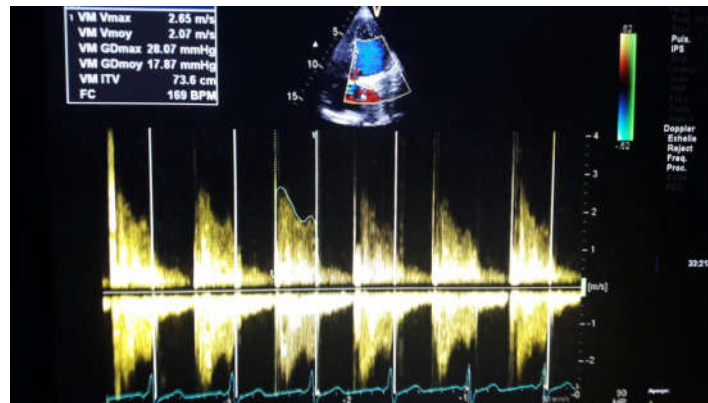


Figure 1. Transthoracic echocardiography showing a mechanical prosthesis in the double-finned mitral position with a blade lock, with a mean gradient at 17mmHg

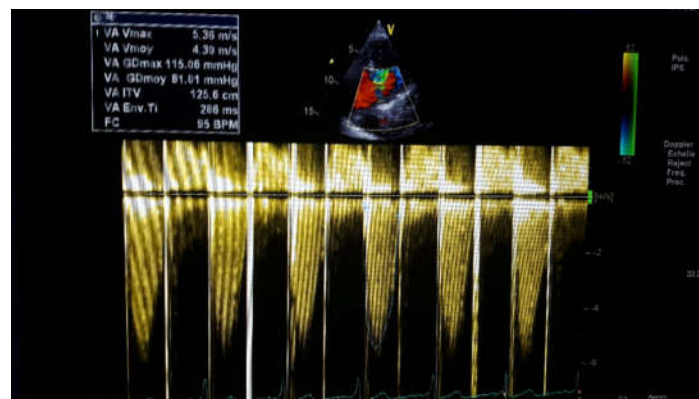


Figure 2. Transthoracic echocardiography showing a mechanical prosthesis in the aortic position with a double aperture fin, with a mean gradient at 81 mmHg

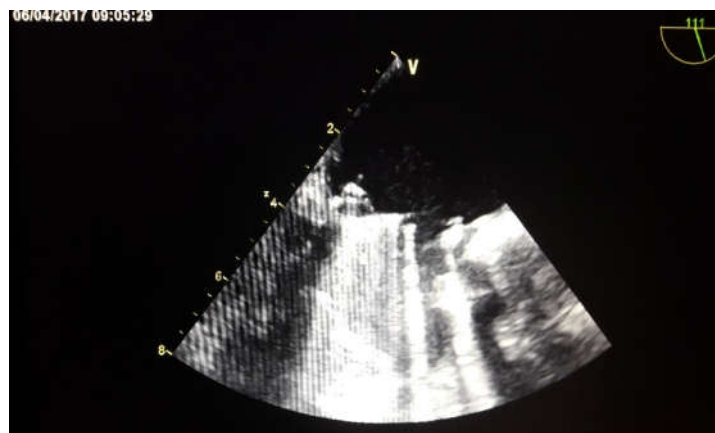

Figure 3. Transoesophageal echocardiography: stuck mitral valve and pedunculated thrombus

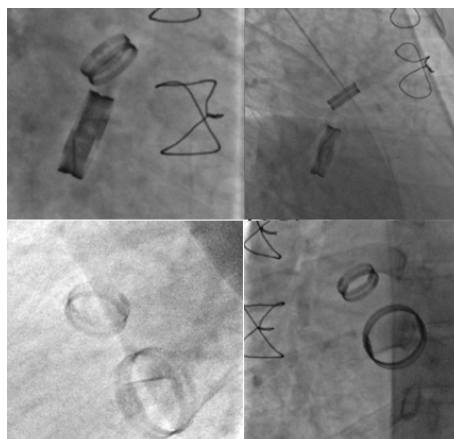


Figure 3. Cinema radio objectified a still wing at the level of the mitral prosthesis, 2 mobile wings at the level of the aortic prosthesis

Follow up was marked by good clinical and biological evolution (dissolution of thrombosis and decreasing of trans-mitral gradient). Then the patient was transferred to the obstetrics and gynecology department at 36 weeks from where the vaginal delivery was done with good post-partum evolution.

## DISCUSSION

Mechanical valve thrombosis is a rare but very serious complication. Although the most common cause of thrombus formation is poor management of anticoagulation, it is also influenced by other factors such as surgical technique, location of the prosthetic valve, type of valve, formation of pannus around the valve and the patient's hemodynamic status. Atrial fibrillation, pregnancy, left atrium dilation and ventricular dysfunction are additional factors that can lead to thrombus formation (Murat Biteker *et al.*, 2015). In their study, Lengyel *et al.* showed that 82% of patients with mechanical valve thrombosis have inadequate use of anticoagulants (Lengyel, 2004) Pregnancy-related changes are thought to exaggerate the blood clotting response in mothers, leaving them more vulnerable to thrombosis. Anticoagulation becomes more difficult to manage. Stricter control of anticoagulant therapy is necessary for these patients. Despite the use of the same warfarin doses, patient INR values decreased from 2.5 to 1.4. We tend to think that pregnancy, among other factors, could have changed its INR value. Patients with mechanical valve thrombosis usually present with worsening functional signs, dyspnoea, peripheral embolization, pulmonary edema, and cardiogenic shock. The TTE provides valuable elements that point towards the diagnosis of mechanical valve thrombosis, however, TOE is the gold standard for diagnosis confirmation, thrombus size measurement and mobility, thrombus search in the appendage of the left atrium and / or the left auricle, pannus or thrombus. TOE should be performed before initiation of treatment. In particular, real-time three-dimensional (3D) TOE that provides extremely useful information on the location and size of thrombosis of the prosthetic valve and in post-thrombolysis follow-up. In our patient, we detected a restricted mobility of the anterior valve of the prosthetic mitral valve and a gradient increase, with a thrombus image at the TOE. As in our case, the results of previous transthoracic ultrasonography can open the way to diagnosis in patients with high gradient values on prosthetic valves. The results of an TTE performed 1 month before admission showed normal valvular mobility, no increase in gradient and no sign of valvular incompatibility. The newly completed TTE and TOE showed no sign of vegetation or dehiscence on the valve. The patient's symptoms were recent, her INR value was infra-therapeutic and she was pregnant, a well-known condition to lead to thrombus susceptibility. Given these factors, thrombosis of the mechanical valves was suspected. There is no current consensus on the treatment of patients with prosthetic valve thrombosis. The ESC recommendations advocate first-line surgical treatment (Lengyel, 2005) while thrombolytic therapy is recommended by the Society of Valve Disease. In addition, the AHA / ACC Valve Disease Guidelines (Bonow *et al.*, 1998), published in March 2014, recommend thrombolytic therapy for patients with recent left heart valve prosthetic valve thrombosis (<14 days). with NYHA class I to II symptoms and when the thrombus is small <0.8 cm. The risks of thrombolytic therapy during pregnancy have never been evaluated with randomized trials.

The best level of evidence comes from case reports or case series. Although thrombolysis in these reports was performed with a different drug, a different protocol and various indications, the overall complication rates in these patients are not worse than the complication rates in large randomized stroke trials, myocardial infarction or pulmonary embolism. (Uri Elkayam *et al.*,?) Mechanical valve thrombosis during pregnancy is rare but requires urgent treatment. Low dose and slow infusion TPA treatment (25 mg / 6 hours) by Özkan *et al.* out of 24 pregnant women showed very promising results. (8) In this study, low-dose, slow-infusion TOE-guided TPA was associated with 100% success without maternal mortality. Fetal mortality was 20%. In general, thrombolytic therapy in non-pregnant women achieves a success rate of approximately 85% (Sharon *et al.*, ?). The risk associated with cardiac surgery during pregnancy is mainly fetal, with a fetal death rate of 20 to 30% and fetal morbidity estimated at 9%. The maternal risk does not seem to be modified by pregnancy, in the order of 3 to 10% of deaths (Ozkan *et al.*, 2009; Weiss *et al.*, 1998; Pomini *et al.*, 1996). The maternal and fetal morbidity and mortality is probably increased by the often late nature of the intervention in a patient with refractory heart failure. The factors of bad maternal prognosis are represented by a hospitalization after the 27th week of pregnancy, the extreme urgency of the intervention, and by the realization of the operation at the same time or just after the birth of the child (Weiss *et al.*, 1998). In order to reduce fetal morbidity and mortality, extracorporeal circulation should be performed under very moderate hypothermia (temperature > 34 ° C), a high flow rate of 3.5 to 4 l / min / m<sup>2</sup> and a high perfusion pressure (mean arterial pressure of 80 to 90 mmHg). The use of a pulsed infusion has also been suggested but is still debated.

**Conclusion:** Pregnant patients with a mechanical heart valve should be followed closely. The diagnosis of valve thrombosis should be suspected before a trans valvular gradient increase during echocardiography follow-up. Pregnant patients with prosthetic valve thrombosis may be treated surgically, or with prolonged infusions of low-dose TPA. Repeated doses of low TPA can be administered at low doses.

## REFERENCES

- Anticoagulation in Pregnant Women With Prosthetic Heart Valves  
Uri Elkayam, MD, Harpreet Singh, MD, AdilIrani, MD, and Mohammed W. Akhter, MD.
- Bonow, RO., Carabello, B., de Leon, AC., Jr, Edmunds, LH Jr, *et al.*, 1998. ACC/AHA Task force report: ACC/AHA Guidelines for the management of patients with valvular heart disease. *J Am CollCardiol.*, 32:1486-588.
- Lengyel M. Management of prosthetic valve thrombosis. *J Heart Valve Dis.*, 2004;13:329-44
- Lengyel, M. 2005. Thrombolysis should be regarded as first line therapy for prosthetic valve thrombosis in the absence of contraindications *J Am CollCardiol.*,18:45.
- McGehee W. Anticoagulation in pregnancy. In Elkayam U, Gleicher N, (eds), *Cardiac Problems in Pregnancy*, 3rd edition. New York: Wiley-Liss, 1998, pp 407–417.
- Mustafa Ozan Gürsoy, Macit Kalçık, Mahmut Yesin, Süleyman Karakoyun, Emrah Bayam, Sabahattin Gündüz, and Mehmet Özkan, A global perspective on mechanical prosthetic heart valve thrombosis: Diagnostic and therapeutic challenges.
- North RA, Sadler L, Stewart AW, McCowan LM, Kerr AR, White HD. Longterm survival and valve-related complications in young women with cardiac valve replacements. *Circulation* 1999; 99:2669-76.

- Ozkan, M., Biteker, M., Duran, NE. and YÖldÖz, M. 2009. Images in cardiovascular medicine. Huge prosthetic mitral valve thrombosis in a pregnant woman, *Circulation*. 120:e151-2.
- Pomini, F., Mercogliano, D., Cavaletti, C., Caruso, A. and Pomini, P. 1996. Cardiopulmonary bypass in prgnancy. *Ann Thorac Surg.*, 61: 259-68.
- Treatment of Prosthetic Valve Thrombosis: Current Evidence and Future Directions Murat Biteker, Ibrahim Altun, OzcanBasaran, VolkanDogan, BirdalYildirim, Gokhan Ergun *J Clin Med Res.*, 2015 Dec; 7(12): 932–936.
- Valvular Heart Disease in Pregnancy Sharon C. Reimold, M.D. and John D. Rutherford, M.B., Ch.B.
- Weiss, BM., Von Segesser, LK., Alon, E., Seifert, B. and Turina, MI. 1998. Outcome of cardiovascular surgery and pregnancy: a systematic review of the period 1984-1996. *Am J Obstet Gynecol.*, 179: 1643-53.

\*\*\*\*\*