



RESEARCH ARTICLE

FORTUITOUS FINDING IN THE ASSESMENT OF 2000 DIAGNOSTIC ORTHOPANTAMOGRAM- A
RETROSPECTIVE COMPREHENSIVE STUDY

*¹Dr. Saraswathi .K .Gopal, ²Dr. Padma.M., ³Dr. Supriya Manoharan, ⁴Dr. Sowmya.H.,
and ⁵Dr. Amala Manivannan.

*¹Head of the Department, Department of Oral Medicine and Radiology,
Meenakshi Ammal Dental College and Hospital, Maduravoyal, Chennai, Tamilnadu, India
^{2,3,4,5}Postgraduates, Department of Oral Medicine and Radiology,
Meenakshi Ammal Dental College and Hospital, Maduravoyal, Chennai, Tamilnadu, India

ARTICLE INFO

Article History:

Received 16th April, 2018
Received in revised form
27th May, 2018
Accepted 20th June, 2018
Published online 31st July, 2018

Key words:

Orthopantamogram,
Identification, single image,
Interpretation, Importance,
Early diagnosis.

ABSTRACT

Background: Panoramic radiography is a two-dimensional dental x-ray that captures the entire mouth in a single image, including the teeth, upper and lower jaws, surrounding structures and tissues. The study was conducted to report the various findings on panoramic radiographs archives of retrospective data.

Materials and Method: This study was conducted in the department of Oral Medicine & Radiology in Meenakshi Ammal Dental College & Hospital during the period August 2016 to September 2017. It included panoramic radiographs of 2000 patient images obtained for various reasons. Patient's information such as name, age, gender, indication of OPG was recorded. All images which were of no diagnostic value and faulty were excluded from the study. All images were taken with single digital Sirona OPG machine and were statistically analysed with Chi square test using SPSS software version 22.0.

Results: In the spectrum of our OPG radiographic study, the various common findings in the 2000 radiographs are periodontitis with 21.05%, impacted mandibular 3rd molar bilaterally with 14.95%, periapical abscess with 8.30 %, impacted mandibular 3rd molar unilaterally with 6.80%, pulp stone with 5.60% , styloid elongation – unilateral in 5.25%, microdontia and maxillary 3rd molar bilaterally with 5% , root dilacerations with 4.45%, TMJ degeneration with 3.40% and maxillary 3rd molar unilaterally with 3.35% . Out of 2000 radiographs, incidental findings were seen in 973 radiographs with 48.65%. The most common incidental findings are periodontitis 25.28%, pulp stone 22.30%, impacted mandibular 3rd molars bilaterally 17.99%, TMJ degeneration with 10.79% , microdontia 10.27%, impacted mandibular molar unilateral 10.07%, root dilacerations 9.54%, periapical abscess 9.45%, impacted maxillary molars bilaterally 7.39%, styloid elongation bilateral 4.93%, calcified carotid arteries 4.93%, Odontomes 4.32%, impacted maxillary molars unilateral 4.01%, styloid elongation unilateral 3.59%, dense bone islands of 3.08% , cement osseous dysplasia 2.87% , maxillary sinus thickening of 1.54%, external root resorption and other impacted teeth with 1.43%, supernumerary impacted teeth 1.33%, macrodontia and maxillary canine impaction with 1.23%, mandibular canine impaction 1.13%, and antrolith with 0.61% and internal root resorption with 0.20%.

Conclusion: Panoramic radiograph is a preferred routine diagnostic tool for the evaluation of fractures, impacted teeth, full mouth rehabilitation, large lesions, cysts, tumors etc. The additional advantage is incidental findings which may remain undetected if radiographer does not concentrates on keen interpretation.

*Corresponding author:

Dr. Saraswathi K Gopal,
Head of the Department, Department of
Oral Medicine and Radiology,
Meenakshiammal Dental College and
Hospital, Maduravoyal, Chennai,
Tamilnadu, India.
DOI: <https://doi.org/10.24941/ijcr.30404.07.2018>

Copyright © 2018, Dr. Saraswathi K Gopal, et al. This is an open access article distributed under the Creative Commons Attribution License, which permits unrestricted use, distribution, and reproduction in any medium, provided the original work is properly cited.

Citation: Dr. Saraswathi K Gopal, Dr. Padma, M., Dr. Sowmya, H., Dr. Amala Manivannan and Dr. Supriya Manoharan, 2018. "Fortuitous finding in the assesment of 2000 diagnostic orthopantamogram- a retrospective comprehensive study", *International Journal of Current Research*, 10, (07), 71809-71815.

INTRODUCTION

Panoramic radiographs are two-dimensional complex tomographic images of the jaws and dentition. They provide a general overview of both jaws and their dentition in addition to surrounding structures, such as the temporomandibular joints,

cervical vertebrae, and the inferior portion of the orbital cavity (Pharoah, 2013). They utilize relatively low doses of radiation [approximately 9- 24 μ Sv] compared to a full mouth [approximately 35 μ Sv] as per the American National Standards Institute [using PSP or F speed film and rectangular

collimation] (Ludlow *et al.*, 2008) (Pharoah, 2014 and Ludlow *et al.*, 2008). Unfortunately, panoramic radiographs are inherently low resolution images that are unsuitable for examining details or detecting carious lesions. Often some clinical sign or symptom or finding from the patient's history indicates the need for a radiologic examination. Commonly, the radiographs are prescribed when the dentist thinks that they are likely to offer useful diagnostic information that will influence or guide the treatment plan. General dentists and dental specialists frequently prescribe panoramic radiographs for a multitude of purposes. These purposes include examining the developing dentition, third molars, and pathological conditions. However, the interpretation of panoramic radiographs is commonly described by many as challenging and difficult, which is due to the complexity of these images, overlapping structures, distortion [unequal magnification] and ghost images that cannot be completely eliminated. Identification and reporting of findings is of paramount importance because they may necessitate medical and/or dental intervention (Bondemark *et al.*, 2006). If the presence of any abnormalities detected in advance, it finds the new diagnosis, if needed requires early treatment. and the prognosis is improved; also it may reduce the morbidity and mortality rate to some extent. The study conducted to report the frequency and nature of various findings which are identified in panoramic images obtained from the archives of Sirona OPG digital machine in Department of Oral Medicine and Radiology, Meenakshi Ammal Dental college, Chennai, India.

MATERIALS AND METHODS

All the OPG images were screened along with the radiographic findings related to patient's chief complaint and radiographic examinations performed during August 2016 to September 2017 were included in the study which included 2000 patient images from the archives of retrospective data captured by Sirona OPG digital software. Intra□ and inter□examiner accuracy and reproducibility for each of the radiograph was done to increase the authenticity of the study.

Exclusion criteria

All images which were of no diagnostic value and faulty were excluded from the study. Panoramic radiographs with positioning or magnification errors were excluded. The data collected included basic demographics, such as patient's age and gender, in addition to all of the incidental findings. Incidental findings in this study were defined as any finding that was not related to the patient's chief complaint and/or the indication for which the panoramic radiograph was requested. Simple descriptive statistics in the form of counts and percentages, mean range were calculated using SPSS version 22.0. Furthermore, to establish the relationship between demographics and incidental findings, the Chi-Square test was used for gender and the t-test for age.

RESULTS

The age of our subjects ranged from 14 to 65 years with a mean of 36.46 years in males and 34.14 yrs in females. Gender distribution was equal with 50.60% males and 49.40% females. No statistically significant difference was found relative to age [$p = 0.156$] and gender [$p = 0.117$] as shown in Table 1 and Graph 1. The frequencies of the various findings are summarized in Table 2 & Graph 2.

The radiological findings in male and female are given in Table 3 and Graph 3. The frequencies of incidental findings and their percentage are summarized in Table 4 and Graph 4.

DISCUSSION

Panoramic radiograph is a commonly advised extra oral radiograph in dentistry. It is preferred over full mouth radiographs as it offers less patient exposure. The present study evaluated all 2000 panoramic radiographs taken for different reasons to asses various diagnostic radiological findings in which incidental findings were evaluated. According to the literature, indications for panoramic radiography was given by selection criteria proposed by Freny Karjodkar in the text book .

- As a substitute for full mouth intraoral periapical radiographs.
- To establish the site and size of lesions such as cysts, tumors and developmental anomalies in the body and rami of the mandible.
- As part of an orthodontic assessment where there is a clinical need to know the state of the dentition and the presence/absence of teeth.
- Fractures of all parts of the mandible except the anterior region.
- Assessment of third molars, at a time when consideration needs to be given to whether they should be removed or not.
- Investigation of TM joint dysfunction.
- Assessment for underlying bone disease before constructing complete or partial dentures.
- Vertical alveolar bone height as part of pre implant planning
- For follow-up of treatment, progress of pathology or postoperative bony healing.
- To study the antrum, especially to study the floor, posterior and anterior walls of the antrum.
- Periodontal disease—as an overall view of the alveolar bone levels. This is the first kind of study reporting with all common findings of pathological and incidental screened in panoramic x rays .

The various common findings in the 2000 radiographs are periodontitis with 21.05%, mandibular 3rd molar bilaterally with 14.95%, periapical abscess with 8.30 %, mandibular 3rd molar unilaterally with 6.80% , pulp stone with 5.60% , styloid elongation – unilateral in 5.25%, microdontia and maxillary 3rd molar bilaterally with 5% , root dilacerations with 4.45%, TMJ degeneration with 3.40% and maxillary 3rd molar unilaterally with 3.35% . Out of 2000 radiographs, incidental findings were seen in 973 radiographs with 48.65%. The incidental findings are considered as other findings which is seen in the radiograph taken for the purpose other than the chief complaint. The most common incidental findings are periodontitis 25.28%, pulp stone 22.30%, mandibular 3rd molars bilaterally 17.99%, TMJ degeneration with 10.79% , microdontia 10.27%, mandibular molar unilateral 10.07%, root dilacerations 9.54%, periapical abscess 9.45%, maxillary molars bilaterally 7.39%, styloid elongation bilateral 4.93%, calcified carotid arteries 4.93%, Odontomes 4.32%, maxillary molars unilateral 4.01%, styloid elongation unilateral 3.59%, dense bone island of 3.08% , cement osseous dysplasia 2.87% , maxillary sinus thickening of 1.54%, external root resorption

Table 1. Demographic Details of Gender Distribution and Age of Patients in the Study Population

	No. of radiographs	Percentage	Chi-square test p-value
Male	1012	50.60%	
Female	988	49.40%	0.117
mean age Male	36.467yrs		
mean age Female	34.144yrs		0.156

Table 2. The Frequencies of the Various Findings in Counts of Radiographs and Their Percentage

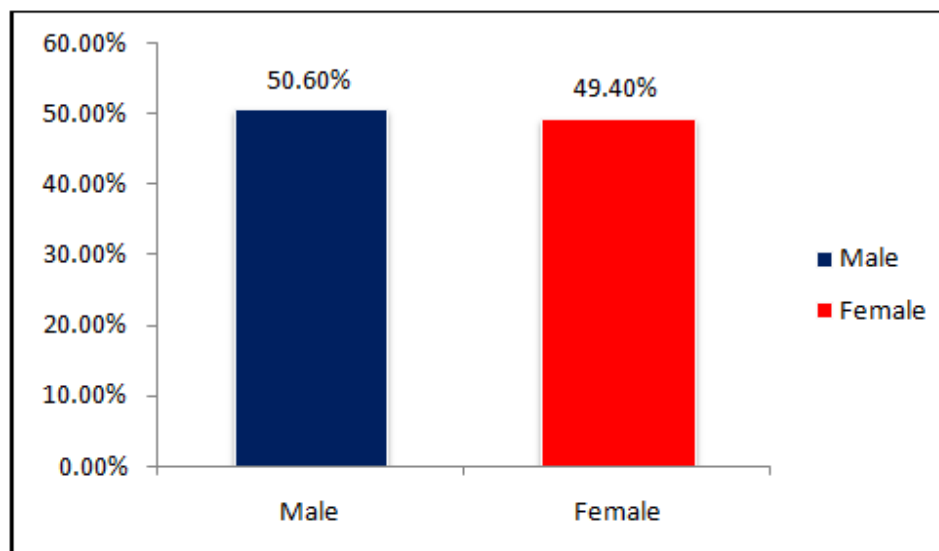
FINDINGS	No. of Radiographs	Percentage
1.Periodontitis	421	21.05%
2.Mandibular 3 rd molar Bilateral	299	14.95%
3.Periapical abscess	166	8.30%
4.Mandibular 3 rd molar Unilateral	136	6.80%
5.Pulp stone	113	5.60%
6.Styloid elongation unilateral	105	5.25%
7.Microdontia	100	5%
8.Maxillary 3 rd molar Bilateral	100	5%
9.Root dilacerations	89	4.45%
10.TMJ degeneration	68	3.40%
11.Maxillary 3 rd molar Unilateral	67	3.35%
12.Odontomes	42	2.06%
13.fractures	41	2.05%
14.Styloid elongation Bilateral	35	1.75%
15.dense bone island	30	1.50%
16.Cemento osseous dysplasia	28	1.40%
17.Calcified carotid arteries	28	1.40%
18.Periapical cyst	25	1.25%
19.Mandibular canine impaction	15	0.75%
20.Maxillary sinus thickening	15	0.75%
21.External root resorption	14	0.70%
22.Maxillary canine impaction	14	0.70%
23.Other impaction	14	0.70%
24.Supernumerary teeth	13	0.65%
25.Macrodonia	12	0.60%
26.Antrolith	6	0.30%
27.Sialolith	5	0.25%
28.Internal root resorption	2	0.10%
29.Residual cyst	2	0.10%

Table 3. Total Number of Radiographs in Male and Female with Radiological Findings and Percentage

RADIOLOGICAL FINDINGS	MALE	%	FEMALE	%
1.periodontitis	216	21.34387352	205	20.74899
2. Mandibular impaction bilateral	156	15.41501976	143	14.47368
3. pulp stone	90	8.893280632	127	12.85425
4. Mandibular impaction unilateral	52	5.138339921	84	8.502024
5. Periapical abscess	85	8.399209486	81	8.198381
6. Maxillary impaction bilateral	45	4.446640316	55	5.566802
7. Microdontia	54	5.335968379	46	4.65587
8. Styloid elongation unilateral	63	6.225296443	42	4.251012
9. root dilacerations	45	4.446640316	44	4.452012
9. TMJ degeneration	28	2.766798419	40	4.048583
10. Maxillary impaction unilateral	30	2.964426877	37	3.744939
11. Odontomes	18	1.778656126	24	2.42915
12. cemento osseous dysplasia	9	0.889328063	19	1.923077
13. Calcified carotid arteries	29	2.865612648	19	1.923077
14. Styloid elongation bilateral	18	1.778656126	17	1.720648
15. dense bone island	14	1.383399209	16	1.619433
16. Periapical cyst	14	1.383399209	11	1.11336
17. External root resorption	6	0.592885375	8	0.809717
18. Maxillary canine impaction	6	0.592885375	8	0.809717
19. fractures	33	3.260869565	8	0.809717
20. Mandibular canine impaction	8	0.790513834	7	0.708502
21. Other impaction	8	0.790513834	6	0.607287
22. Supernumerary teeth	8	0.790513834	5	0.506073
23. Macrodonia	7	0.691699605	5	0.506073
24. Sialolith	1	0.098814229	4	0.404858
25. Residual cyst	0	0	2	0.202429
26. Antrolith	4	0.395256917	2	0.202429
27. TMJ cyst	0	0	1	0.101215
28. maxillary sinus thickening	4	0.395256917	1	0.101215
29. Internal root resorption	2	0.197628458	0	0

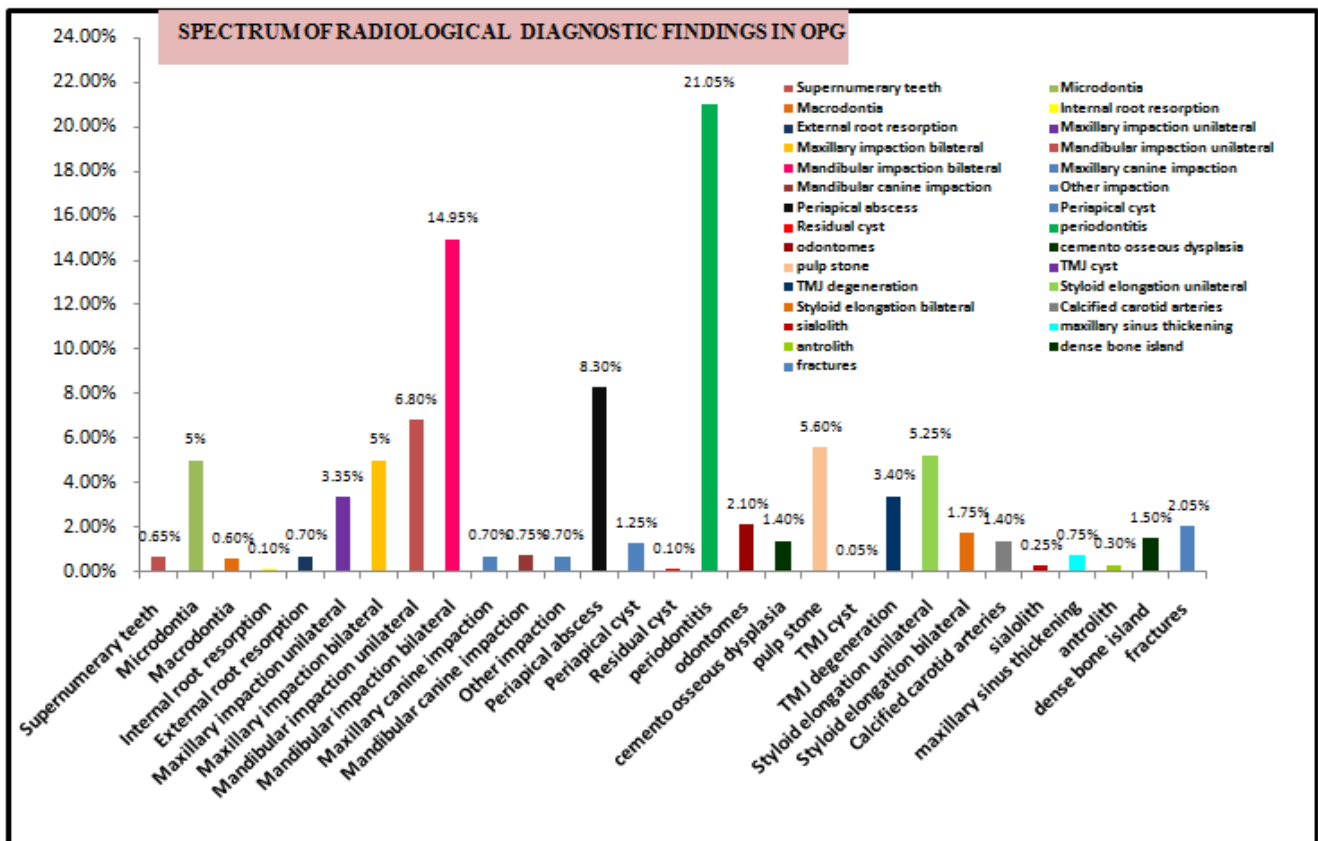
Table 4. The frequencies of the various incidental findings in counts of radiographs and their percentage

S.NO	INCIDENTAL FINDINGS	NO OF RADIOGRAPHS	PERCENTAGE
1	Periodontitis	246	25.28263
2	pulp stone	217	22.30216
3	Mandibular molar bilateral	175	17.98561
4	TMJ degeneration	105	10.79137
5	Microdontia	100	10.27749
6	Mandibular molar unilateral	98	10.07194
7	periapical abscess	92	9.455293
8	Root dilacerations	89	9.54321
8	Maxillary molar Bilateral	72	7.399794
9	Styloid elongation bilateral	48	4.933196
10	Calcified carotid arteries	48	4.933196
11	Odontomes	42	4.316547
12	Maxillary molar Unilateral	39	4.008222
13	Styloid elongation unilateral	35	3.597122
14	dense bone island	30	3.083248
15	cemento osseous dysplasia	28	2.877698
16	maxillary sinus thickening	15	1.541624
17	External root resorption	14	1.438849
18	Other impaction	14	1.438849
19	supernumerary teeth	13	1.336074
20	Macrodontia	12	1.233299
21	Maxillary canine impaction	12	1.233299
22	mandibular canine impaction	11	1.130524
23	Antrolith	6	0.61665
24	internal root resorption	2	0.2055

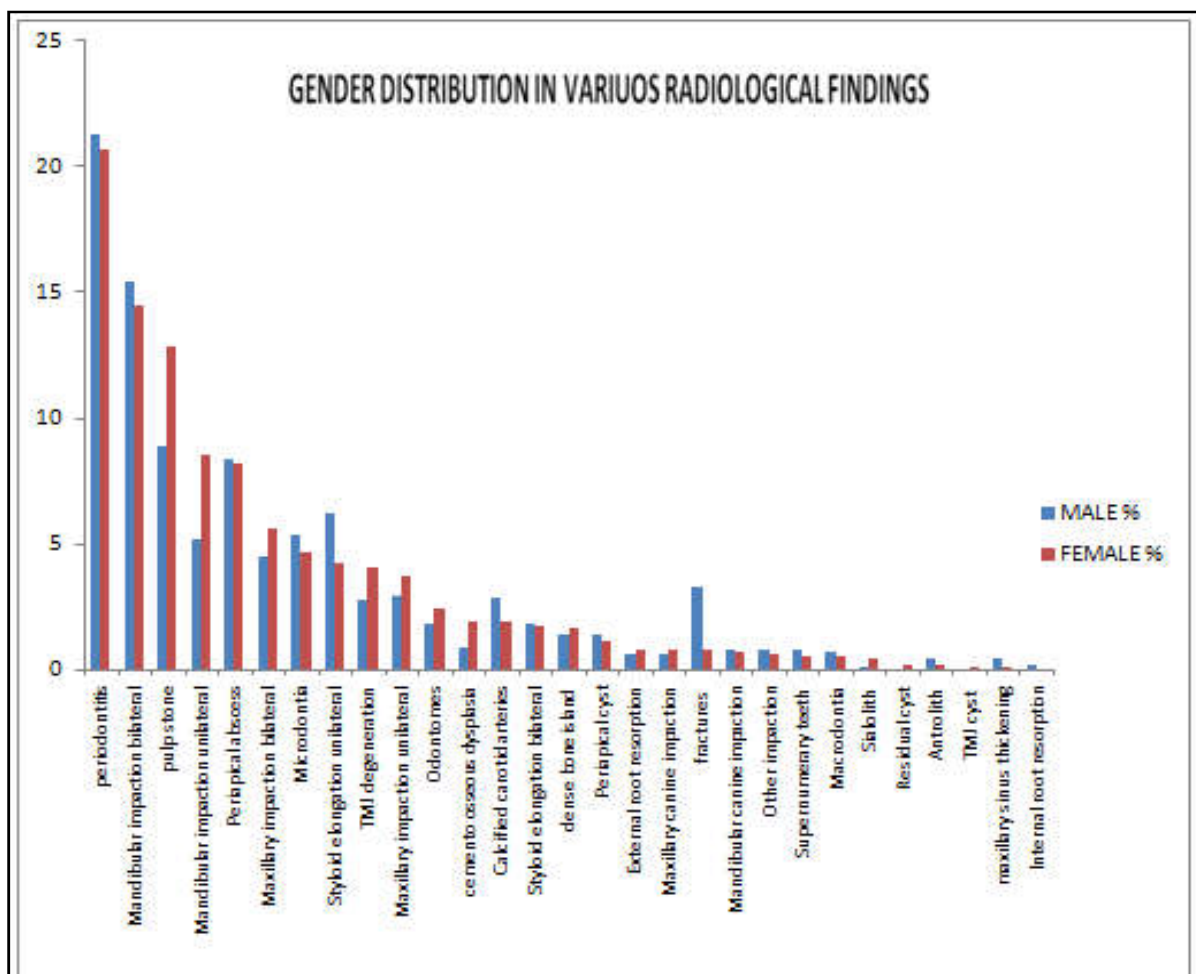
**Graph 1. Demographic details of sex distribution**

and other impacted teeth with 1.43%, supernumerary impacted teeth 1.33%, macrodontia and maxillary canine impaction with 1.23%, mandibular canine impaction 1.13%, and antrolith with 0.61% and internal root resorption with 0.20%. Similar findings were seen in study conducted by (Shaik *et al.*, 2013). The most common incidental finding was pulp stones, with females are more predominant than males with prevalence of 5.60%. The next most common finding was styloid process elongation or calcification of the stylohyoid ligament. We reported that elongated styloid process was seen in unilateral (5.25%) and bilateral (1.75%) of cases and more predominant in males compared to the females. This finding is common among many population studies conducted earlier. (Sudhakara Reddy *et al.*, 2013; Shaik *et al.*, 2013; Alpoz *et al.*, 2014; Mandian and Tadinada, 2014). Most patients are asymptomatic, although the condition may be symptomatic in 1-5% of cases (Khandelwal *et al.*, 2011). The symptomatic form of this condition is termed Eagle's syndrome and was first documented by Dr. Eagle in 1948 when he correlated symptoms of pain on swallowing or turning the neck with

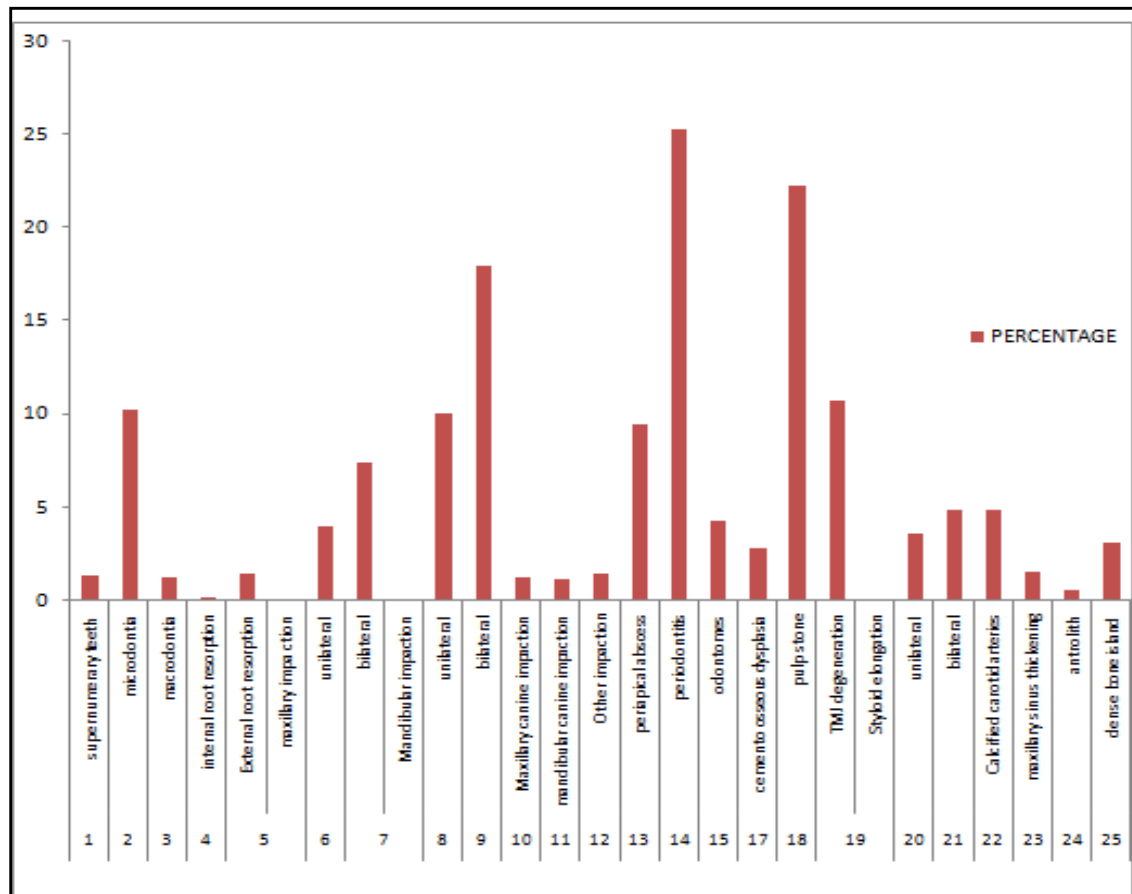
elongation of the styloid process or calcification of the stylohyoid ligament (Eagle, 1948), bilateral involvement was reported at a rate of 55% in cases with Eagle's syndrome (Khandelwal *et al.*, 2011). The dense bone island [DBI], also known as enostosis or idiopathic osteosclerosis (Pharoah *et al.*, 2013) with prevalence of 1.5%. It is a hamartoma that usually presents as a relatively well-defined area of dense bone (Pharoah *et al.*, 2013; Ramesh and Ganguly, 2010). It may vary in shape and size but it is asymptomatic, identified radiographically and should not be biopsied because it lacks an adequate blood supply. (Ramesh and Ganguly, 2010). According to Brondemark *et al.* (2006) study the incidence for dense bone island was more in panoramic radiographs of orthodontic patients. This lesion may be radiographically mistaken for exostosis, including torus mandibularis and palatinus, residual condensing osteitis, alveolar calcification after extraction, bone architectural change in response to occlusal trauma on an inclined tooth, particularly on mandibular second molars, when the first molars are missing.



Graph 2. Frequency of distribution of various radiological findings



Graph 3. Gender Distribution in Various Diagnostic Radiological Findings



Graph 4 . Percentage of Various Incidental Findings

The most common soft tissue calcification identified in this study was vascular calcification with prevalence of 1.40%. Although vascular calcifications can potentially affect any artery, on panoramic images they are usually encountered in the carotid arteries, especially at the furcation area at the level of cervical vertebrae 3 and 4 (Mandian and Tadinada, 2014). Several studies have examined the efficacy of panoramic images at detecting carotid artery calcification and have found the sensitivity and specificity to be poor to moderate according to the various authors. (Mandian and Tadinada, 2014, Friedlander, 2007; Griniatsos *et al.*, 2009; Pornprasertsuk-Damrongsri and Thanakun, 2006; Ohba *et al.*, 2003; Ertas and Sisman, 2011). Sialoliths in submandibular region are seen on panoramic image in the molar and premolar region and in our study seen with prevalence of 0.25% and is seen commonly in females compared to males. They often present in symptomatic patients and so in our study also. The maxillary sinuses are of importance to dentist because of their proximity to dental structures. Part or all of the paranasal sinuses may appear on radiographs made for dental purposes, including maxillary periapical, panoramic and lateral or posteroanterior skull radiographs and cephalometric radiographs. Antral polyp rarely causes any signs or symptoms and is often noticed as an incidental finding on radiographs made for other purposes. It usually requires no treatment because they customarily resolve spontaneously without any residual effect on the antral mucosa and periodic follow up may be required. We reported mucosal thickening in 0.75% and antrolith in 0.30% of our study in accordance with Roopashni *et al.* (2012) and Mandian *et al.* (2014) studies. Both sinus opacification and lack of a sinus cortical boundary may be signs of a malignant tumor and require further investigation and advanced imaging of the sinuses.

In our study, common dental anomalies were supernumerary teeth (.65%), microdontia (5%), macrodontia (.6%), root dilacerations (4.45%), internal root resorption in 0.10% and external root resorption in 1% of all cases. Early identification of internal resorption is vital, it may be transient and self-limiting or progressive, if endodontic treatment is started early or in time it halts the resorption (0.10%). Our results correlated with Griniatsos *et al.* (2009) study. The periapical inflammatory lesion includes periapical abscess, radicular cysts, residual cysts, and apical scars. Periapical abscess is seen in 8.30% and radicular cysts are seen in 1.25% of all cases in our study. Also correlated with Roopashini *et al.* (2012) study. The supernumerary teeth are more commonly encountered clinically as well as radiographically. The impacted supernumerary teeth requires removal of teeth to avoid cyst formation or development of malocclusion. The mind's eye view of the panoramic radiograph: The 6 zones that we must learn to interpret the panoramic radiographs are

- Zone 1 : The dentition
- Zone 2 : The nose- sinus
- Zone 3 : The mandible
- Zone 4 : The TMJ's
- Zone 5: The spine-ramus
- Zone 6: The hyoid

The various findings pertaining to the various zones are in

- Zone 1:** Dental caries with pulpal and periapical pathology, cyst, impacted teeth, dense bone island, odontomes, Pulp stone, root dilacerations, fracture of teeth/ jaw, sialolith
- Zone 2:** maxillary sinus mucosal thickening, antral polyp, antrolith, cysts

- Zone 3:** Fracture of jaw, odontome, supernumerary impacted teeth, root dilacerations,
- Zone 4:** TMJ degeneration, Condylar hyperplasia, TMJ cyst, Osteophyte, coronoid hyperplasia
- Zone 5:** Cyst, mandibular molar impaction, root dilacerations, dense bone island, fracture of ramus and angle of mandible
- Zone 6:** Here the double and real images of body and great horns of the hyoid can be seen in both sides, carotid calcifications can be identified as incidental finding in this zone.

Thus, the data acquired from the findings of this study put forward that radiologist should not only interpret characteristic findings of the pathological conditions related to the chief complaint of the patient but also to analyze coincidental findings. Moreover, this is not the one time activity but it is an ongoing process.

Conclusion

Panoramic radiographs have many useful applications in dentistry but require diligence on the part of the observer to examine the image thoroughly. Understanding the perspective of the anatomy on panoramic radiographs and many superimpositions and distortions produced will be a difficult task for the practitioner to be more successful at the diagnosis. For this reason, a systematic approach is recommended for the interpretation of the image type. A thorough review of all radiographic images will aid in early diagnosis, while a good documentation of significant anatomical variations will provide important preoperative information.

Acknowledgement: Nil

Conflict of Interest statement: Not Applicable

Funding statement: None

REFERENCES

- Alpoz, E., Akar, G.C., Celik, S., Govsa, F. and Lomcali, G. 2014. Prevalence and pattern of stylohyoid chain complex patterns detected by panoramic radiographs among Turkish population. *Surgical and radiologic anatomy*, SRA. 36(1):39-46
- Bondemark, L., Jeppsson, M., Lindh-Ingildsen, L. and Ränge, K. 2006. Incidental findings of pathology and abnormality in pretreatment orthodontic panoramic radiographs. *The Angle orthodontist*, 76(1):98-102.
- Derek Richards : Selection criteria for dental radiography booklet if UK : British Dental journal : Research Gate.net . Nov 1992.
- Eagle, W.W. 1948. Elongated styloid process; further observations and a new syndrome. *Archives of*
- Ertas, E.T. and Sisman, Y. 2011. Detection of incidental carotid artery calcifications during dental examinations: panoramic radiography as an important aid in dentistry. *Oral surgery, oral medicine, oral pathology, oral radiology, and endodontics*, 112(4):e11-7.
- Friedlander, A.H. 2007. Atheromas on panoramic radiographs often denote stenotic lesions and portend adverse vascular events. *Oral surgery, oral medicine, oral pathology, oral radiology, and endodontics*, 104(4):451-2; author reply 2-4.
- Griniatsos, J., Damaskos, S., Tsekouras, N., Klonaris, C. and Georgopoulos, S. 2009. Correlation of calcified carotid plaques detected by panoramic radiograph with risk factors for stroke development. *Oral surgery, oral medicine, oral pathology, oral radiology, and endodontics*, 108(4):600-3.
- Khandelwal, S., Hada, Y.S. and Harsh, A. 2011. Eagle's syndrome - A case report and review of the literature. *The Saudi dental journal*, 23(4):211-5.
- Mandian, M. and Tadinada, A. 2014. Incidental findings in the neck region of dental implant patients: a comparison between panoramic radiography and CBCT. *Journal of the Massachusetts Dental Society*, 63(2):42-5.
- Mosby, p. 257-69. Ludlow, J.B., Davies-Ludlow, L.E. and White, S.C. 2008. Patient risk related to common dental radiographic examinations: the impact of 2007 International Commission on Radiological Protection recommendations regarding dose calculation. *Journal of the American Dental Association*, 139(9):1237-43.
- Ohba, T., Takata, Y., Ansai, T., Morimoto, Y., Tanaka, T. and Kito, S. et al. 2003. Evaluation of calcified carotid artery atheromas detected by panoramic radiograph among 80-year-olds. *Oral surgery, oral medicine, oral pathology, oral radiology, and endodontics*, 96(5):647-50.
- otolaryngology*, 47(5):630-40.
- Pharoah, M. 2013. In: White SC PM, editor. *Oral Radiology: Principles and Interpretation*. St Louis, Missouri: Elsevier 257-269.
- Pharoah, M. 2014 . First South East Asia Edition . *Oral Radiology: Principles and Interpretation.. Safety and protection*: page No: 32
- Pornprasertsuk-Damrongsri, S. and Thanakun, S. 2006. Carotid artery calcification detected on panoramic radiographs in a group of Thai population. *Oral surgery, oral medicine, oral pathology, oral radiology, and endodontics*, 101(1):110-5.
- Ramesh, A. and Ganguly, R. 2010. Incidental dental radiographic findings: dense bone islands. *Journal of the Massachusetts Dental Society*, 59(3):48-9.
- Roopashri, G., Vaishali, M.R., David, M.P. and Baig, M. 2012. Evaluation of elongated styloid process on digital panoramic radiographs. *The journal of contemporary dental practice*, 13(5):618-22.
- Shaik, M.A., Naheeda, Kaleem S.M., Wahab A, Hameed S. 2013. Prevalence of elongated styloid process in Saudi population of Aseer region. *European journal of dentistry*, 7(4):449-54.
- Sudhakara Reddy, R., Sai Kiran, C., Sai Madhavi, N., Raghavendra, M.N. and Satish, A. 2013. Prevalence of elongation and calcification patterns of elongated styloid process in south India. *Journal of clinical and experimental dentistry*, 5(1):e30-5.
- Text book of Dental and maxillofacial Radiology : Freny karjodkar.
