



ISSN: 0975-833X

Available online at <http://www.journalcra.com>

International Journal of Current Research
Vol. 10, Issue, 06, pp.70157-70160, June, 2018

INTERNATIONAL JOURNAL
OF CURRENT RESEARCH

RESEARCH ARTICLE

RADIOLOGICAL INDICATORS OF SURVIVAL IN PATIENTS WITH BILATERAL TRAUMATIC INTRACRANIAL HEMATOMAS

Dr. Adimoolam Sendil Kumar and *Dr. Aravinth Kumar Ashok

Institute of Neurosurgery, Madras Medical College, Chennai – 600003, India

ARTICLE INFO

Article History:

Received 06th March, 2018

Received in revised form

18th April, 2018

Accepted 08th May, 2018

Published online 28th June, 2018

Key words:

Head injury,
Bilateral haematomas,
SDH,
EDH,
Survival.

Abbreviations

CT - Computed Tomography
EDH – Extra Dural Hemorrhage
GCS – Glasgow Coma Scale
SDH – Sub Dural Hemorrhage
TBI – Traumatic Brain Injury

Copyright © 2018, Adimoolam Sendil Kumar and Aravinth Kumar Ashok. This is an open access article distributed under the Creative Commons Attribution License, which permits unrestricted use, distribution, and reproduction in any medium, provided the original work is properly cited.

Citation: Dr. Adimoolam Sendil Kumar and Dr. Aravinth Kumar Ashok, 2018. "Radiological indicators of survival in patients with bilateral traumatic intracranial hematomas", *International Journal of Current Research*, 10, (06), 70157-70160.

INTRODUCTION

Traumatic brain injury (TBI) affects up to 2% of the population per year and constitutes the major cause of death and severe disability among young people. Road traffic injuries account for 2.1% of global mortality. The developing countries bear a large share of burden and account for about 85% of the deaths as a result of road traffic crashes. India accounts for about 10% of road accident fatalities worldwide. Head injury is the leading cause of death in our country. Intracranial haematoma plays an important role in the death and disability that are associated with head injury. There are many studies on intracranial extraparenchymal lesions viz. extradural haematoma (EDH) and subdural haematoma (SDH). Studies on bilateral EDH and bilateral SDH have been presented. But very limited literature is available in patients presenting with combination of EDH+EDH, EDH+SDH and SDH+SDH on the opposite sides. The pathophysiology of both these lesions is different. This poses a challenge to the treating neurosurgeon.

*Corresponding author: Dr. Aravinth Kumar Ashok,
Institute of Neurosurgery, Madras Medical College, Chennai – 600003, India.

ABSTRACT

Aim: To assess the impact of radiological indicators like pre-operative Mid line shift and status of basal cisterns on the survival of patients presenting with combination of EDH+EDH, EDH+SDH and SDH+SDH on the opposite sides.

Materials and Methods: 79 patients admitted in the Institute of Neurology, Rajiv Gandhi Government General Hospital & Madras Medical College, Chennai, with bilateral traumatic intracranial extraparenchymal haematomas were included in this study. Acute, bilateral, traumatic, intracranial-extraparenchymal haematomas that is composed of EDH+EDH, EDH+SDH and SDH+SDH patterns were included in the study group. CT-Brain was done in all patients. In patients having bilateral intracranial haematomas, the midline shift and the condition of basal cisterns on admission were ascertained and documented. The impact of these factors on the survival of the patients was analysed. The data was subjected to statistical analysis and a "p" value of less than 0.05 was supposed to indicate a positive association of the results and survival.

Results: The patients who had a mid line shift of less than 0.5 mm and the patients with a normal basal cistern in the pre-operative phase had statistically significant positive impact on the survival.

Conclusion: The statistically significant positive correlation of the included radiological factors makes CT-Brain a useful tool in the assessment of the survival in patients with combination of intracranial haematomas on the opposite sides.

Guidelines for the Management of Traumatic Brain Injury are available in cases of EDH and SDH. But there are no clear cut guidelines when a patient presents with EDH+EDH, EDH+SDH and SDH+SDH on the opposite sides. Here an attempt has been made to study patients presenting with "Acute bilateral traumatic intracranial – extraparenchymal haematomas". The high association of SDH with focal brain lesions is at least partially responsible for higher mortality rate (Setti *et al.*). Annual incidence of acute subdural haematoma is 2–5 per 100,000. Incidence correlated to frequency of traumatic brain injury. The common causes leading to SDH are road traffic accidents, falls, assault, objects falling on head or sometimes unknown. Incidence of bilateral EDH has been variably reported ranging from 2–25% (Huda *et al.*, 2004; Gupta *et al.*, 1992; Ramzan *et al.*, 2002; Rasmussen *et al.*, 1992; Agrawal, 2011). Highest numbers of the victims were in the most active period of life i.e. the third decade, closely followed by second decade (Chowdhury Noman Khaled *et al.*, 2008). Moreover, there is a need for modalities easily available even in rural areas to predict the post operative outcome in patients with combination of EDH+EDH, EDH+SDH and SDH+SDH on the opposite sides. One such

easily available tool is CT brain. The factors like post operative reduction in mid line shift and post operative opening of basal cisterns can be assessed using CT brain.

Aim of the study

The aim is to assess the impact of CT-Brain based radiological indicators like pre-operative Mid line shift and status of basal cisterns on the survival of patients presenting with combination of EDH+EDH, EDH+SDH and SDH+SDH on the opposite sides.

MATERIALS AND METHODS

79 patients admitted in the Institute of Neurology, Rajiv Gandhi Government General Hospital & Madras Medical College, Chennai, with bilateral traumatic intracranial extraparenchymalhaematomas were included in this study.

Inclusion criteria

Acute, bilateral, traumatic, intracranial-extraparenchymalhaematomas that is composed of EDH+EDH, EDH+SDH and SDH+SDH were included in the study group.

Exclusion criteria

1. Intraparenchymalhaematomas
2. Chronic intracranial haematomas
3. Nontraumatic intracranial haematomas
4. Posterior fossa haematomas

On admission patients clinical profile such as age, sex, admission GCS, presenting symptoms and signs were recorded. All patients were subjected to CT scan brain plain study. In patients having bilateral intracranial haematomas the following features were noted – type of haematoma, site of haematoma, volume of haematoma, midline shift, condition of cisterns and associated lesions. Patients were either managed conservatively or by surgical evacuation of intracranial haematomas. Outcome analysis was done at the time of discharge. Patients with GCS score of less than 9, pupillary abnormality, compression of the cisterns, combined haematoma volume of more than 30ml, patients whose GCS score decreased by 2 from the initial GCS score and CT features suggesting expansion of the haematoma were treated by surgical evacuation of haematoma within 4 hours of admission. The various factors mentioned were documented at the time of admission. The radiological factors like midline shift and status of basal cisterns were considered. The obtained data were subjected to statistical analysis and were correlated to the survival of the patients. A “p” value of less than 0.05 was considered to denote a statistically significant positive correlation between the factors and survival.

RESULTS

Table 1. Status of basal cisterns

Cisterns	Outcome				Total
	Survived	%	Expired	%	
Normal - 1	37	100	0	0	37
Compressed - 2	2	50	2	50	4
Fully Effaced - 3	3	7.9	35	92.1	38
Total	42	-	37	-	79

When the cisterns were normal all the 37 patients survived. 2 of 4 (50%) patients survived when the cisterns were partially effaced and only 3of 38 (8%) survived if the cisterns were totally effaced.

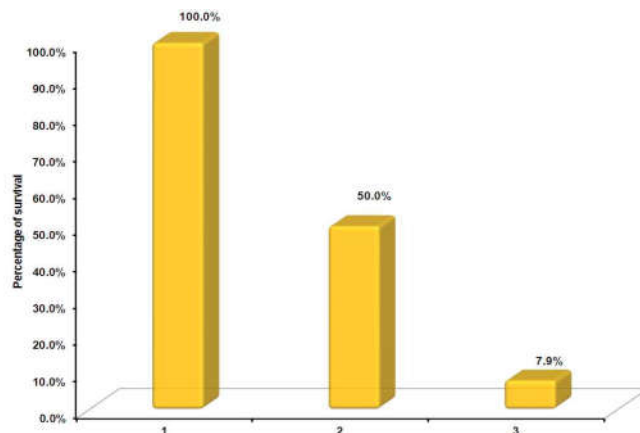


Fig. 1. Status of basal cisterns

There is correlation between Cisterns vs. Outcome (P-value – 0.000<0.05)

Table 2. Midline shift

Midline shift	Outcome				Total
	Survived	%	Expired	%	
Nil - 0	31	70.5	13	29.4	44
< 5 mm - 1	6	50	6	50	12
> 5 mm - 2	4	33.3	8	66.7	12
Total	42	-	37	-	79

When there was no midline shift, 31 of 44 (70.5%) patients survived. When midline shift was <5mm, 6 of 12 (50%) patients survived. When the midline shift was > 5mm, 4 of 12 (33.3%) patients survived.

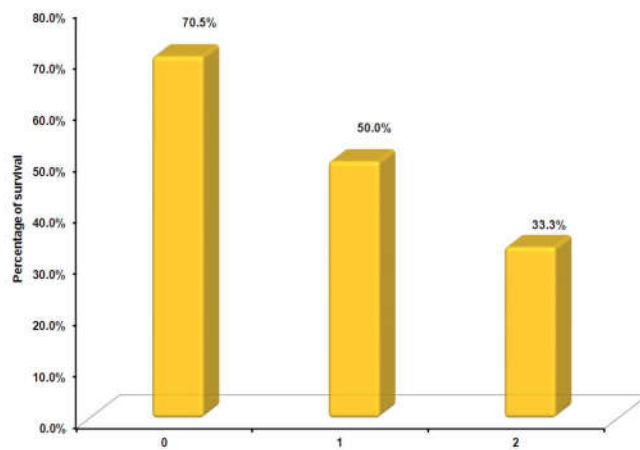


Fig. 2. Midline shift

There is correlation between Midline shift vs. Outcome (P-value – 0.000<0.05)

DISCUSSION

Management

Subdural haematoma: Patients with small acute SDH thinner than 5 mm on axial CT images without sufficient mass effect

can cause midline shift or neurological signs and this can be observed clinically with frequent neurological examination. The use of sequential CT scanning is important. Serial imaging is done to document haematoma resolution because an acute SDH that is treated conservatively can evolve into a chronic haematoma. Another indication for surgery is an Expanding haematoma noted on serial diagnostic imaging, even if the neurological status of the patient is near normal. Bullock et al recently reported that "an acute SDH with a thickness greater than 10 mm, or a midline shift greater than 5 mm on CT scan should be surgically evacuated, regardless of the patient's GCS score (Bullock *et al.*, 2000)."

Extradural haematoma: The recently published "Guidelines for the Surgical Management of Traumatic Brain Injury" recommended that patients who exhibit an EDH that is less than 30 ml, less than 15-mm thick and less than 5-mm midline shift, without a focal neurological deficit and GCS greater than 8 can be treated nonoperatively. Early follow-up scanning should be used to assess a further increase in haematoma size prior to deterioration. Delayed epidural formation has been reported. If a rapid size increase is noted and/or the patient develops anisocoria or a neurological deficit, then surgery is indicated. Any symptomatic EDH, an acute asymptomatic EDH with more than 1cm maximal thickness, midline shift of more than 5mm, volume more than 30ml, posterior fossa EDH and paediatric patients with EDH are the indications for surgery. When operation is performed early, the prognosis is good (Rasmussen *et al.*, 1992). Patients comatose at operation usually evidenced a more rapid clinical deterioration and tended to have a large haematoma volume, a higher incidence of mixed CT density clot (hyperacute bleeding), more marked shift of midline structures, more severe associated lesions, and higher postoperative ICP levels (Rivas *et al.*, 1988). Occasionally, the bone flap (decompressive craniectomy) may not be reattached. This occurs when significant intracerebral swelling or injury is noted on the initial CT scan or encountered during the operation

Outcome and Prognosis: EDH or SDH <1 cm thick can be safely managed nonoperatively unless there is concomitant cerebral oedema (De Souza *et al.*, 2007).

Acute subdural haematoma: The outcome from acute SDH has been generally unsatisfactory. Most series in the literature report a mortality of over 50 percent and none records a mortality of less than 35 percent (Setti *et al.*). Other factors associated with markedly increased morbidity and mortality were increasing age, GCS, associated intraparenchymal contusion, compression of basal cisterns and presence of subarachnoid haemorrhage on CT (Damianos *et al.*, 1995). Croce, *et al.* 1994 reported a functionally independent outcome in 93% of the patients conservatively managed presenting acute SDHs that measure 10 mm or less at the thickest diameter and a GCS>11. Patients who are alcohol abusers have a higher incidence of morbidity and mortality after acute SDH than nonalcoholics (Sonne and Tonnesen, 1992). Multivariate logistic regression analysis indicated that age, preoperative GCS score, brain herniation and the time from trauma to decompression were independently associated with mortality (TIAN Heng-li *et al.*, 2008).

Acute Extradural Haematoma: According to Chowdhury et al⁷ the highest mortality was found in patients of EDH with subdural haemorrhage and a GCS between 3 and 5. Factors

that affect the outcome in EDH are midline shift, traumatic subarachnoid haemorrhage, obliteration of the basal cisterns, thickness of blood clot and haematoma volume, cerebral contusion and fracture of skull bone (Chowdhury *et al.*, 2008). Another important consideration is the timing of repeat CT scan. Sullivan et al have shown that EDH enlargement occurs within 36 hours and a repeat CT is useful at this time. EDH enlargement occurred in 23% of patient and mean time to enlargement was 8 hours of injury (Dubey *et al.*, 2004; Bezircioglu *et al.*, 1996; Bullock *et al.*, 1985; Giordano *et al.*, 1985; Sullivan *et al.*, 1999). Management of patients with bilateral traumatic intracranial haematomas is a challenge because of the multiple factors involved in causation of injury, progression of clinical course, associated intracranial lesions and co-existing morbid medical conditions. Various factors like age, presenting GCS, neurological status, associated intracranial lesions, major medical conditions etc. affecting the outcome of management of bilateral EDH and bilateral SDH have been studied. In this study of heterogeneous group of patients presenting with combinations of EDH/EDH, EDH/SDH and SDH/SDH an attempt has been made to analyze radiological factors such as pre-operative midline shift and status of basal cisterns through CT Brain. A series of 79 cases were evaluated.

Status of basal cisterns

When the cisterns were normal all the patients survived. 50 % of patients survived when the cisterns were partially effaced and only 8% survived if the cisterns were totally effaced. Croce, *et al.* 1994 found that patency of the perimesencephalic cisterns significantly correlated with a favorable outcome in patients conservatively managed, but recommended that haematomas greater than 10 mm should be surgically evacuated (Croce *et al.*, 1994; Feliciano *et al.*, 2008). Yanaka, *et al.* 1993 in a retrospective study on 170 patients with acute SDH also show in these patients a positive predictive value of 77% to unfavorable outcome in the presence of compressed basal cisterns. Surgery has been advocated when a SDH is associated with compressed or effaced basilar cisterns. In one large series of patients with severe head injuries, the mortality rates were 77%, 39%, and 22% for patients with effaced, compressed, or normal cisterns, respectively (Wong, 1994).

Midline shift

In patients with bilateral traumatic intracranial haematomas survival was better when there is no midline shift and worse when the shift was more than 5mm. Midline shift > 5mm have been found to unfavorably influence the outcome (Chen *et al.*, 1993). This was in vogue with Chen *et al.* 1993.

Conclusion

To assess the survival in patients with Bilateral Traumatic Intracranial Hematomas in The Opposite Sides, an easily available, assessable to all and low cost tool is essential. The survival of patients in the post-traumatic period has a binding on the productivity of the patients. CT Brain is one such investigational tool. The statistically significant positive correlation of the radiological factors included in this study like midline shift and status of basal cisterns on admission makes CT-Brain a useful tool in the assessment of the survival in patients with combination of intracranial haematomas on the opposite sides

REFERENCES

- Agrawal A. 2011. Bilateral symmetrical parietal extradural hematoma. *J Surg Tech Case Report*, 3:34-6
- Bezircioglu H, Ersahin Y, Demircivi F, Yurt I, Donertas K, Tektas S. N. 1996. nonoperative treatment of acute extradural hematomas: Analysis of 80 cases. *J Trauma*, 41:696-8.
- Bullock R, Chesnut R, Clifton G, et al. 2000. Guidelines for the management of severe head injury. *J Neurotrauma*, 17:453-553
- Bullock R, Smith RM, van Dellen JR. 1985. Nonoperative management of extradural hematoma. *Neurosurgery*, 16:602-6
- Chen TY, Wong CW, Chang CN, Lui TN, Cheng WC, Tsai MD, et al. 1993. The expectant treatment of "asymptomatic" supratentorial epidural hematomas. *Neurosurgery*, 32:176-9; discussion 179.
- Chowdhury Noman Khaled SM M S, Raihan MZ M S, Chowdhury FH FCPS, Ashadullah ATM MBBS, Sarkar MH M S, Hossain SS FCPS, 2008. Surgical management of traumatic extradural haematoma: Experiences with 610 patients and prospective analysis, *Indian Journal of Neurotrauma (IJNT)*, Vol. 5, No. 2, pp. 75-79
- Croce MA, Dent DL, Menke PG, et al. 1994. Acute subdural hematoma: Nonsurgical management of selected patients. *J Trauma*, 36:820-827.
- Damianos E. Sakas, M.D., M. Ross Bullock, Ph.D., F.R.C.S. (SN), and Graham M. Teasdale, F.R.C.P., F.R.C.S. 1995. One-year outcome following craniotomy for traumatic hematoma in patients with fixed dilated pupils, *JNS*, Volume 82, Number 6.
- De Souza M, Moncure M, Lansford T, Albaugh G, Tarnoff M, Goodman M, Endress R, Ross SE. 2007. Nonoperative management of epidural hematomas and subdural hematomas: is it safe in lesions measuring one centimeter or less?, *Trauma*, 63(2):370-2.
- Dubey A, Pillai SV, Kolluri SV. 2004. Does volume of extradural hematoma influence management strategy and outcome?. *Neurol India*, 52:443-5
- Feliciano CE, et al., 2008. Conservative management outcomes of traumatic acute subdural hematomas *PRHSJ* Vol. 27 No. 3.
- Frank E, Berger TS, Tew JM Jr., 1982. Bilateral epidural hematomas, *Surg Neurol.*, 17(3):218-22.
- Giordano C, Morello G, Rossano A, Chiloiro C, Boccuzzi F. 1985. The benign acute epidural haematoma. *J NeurosurgSci.*, 29:313-6
- Gupta SK, Tandon SC, Mohanty S, Asthana S, Sharma S. 1992. Bilateral traumatic extradural haematomas: report of 12 cases with a review of the literature, *Clin Neurol Neurosurg*, 94(2):127-31.
- Huda MF, Mohanty S, Sharma V, Tiwari Y, Choudhary A, Singh VP. 2004. Double extradural hematoma: An analysis of 46 cases. *Neurol India*, 52:450-2
- Ramzan A, Wani A, Malik AH, Kirmani A, Wani M. Acute bilateral extradural hematomas. *Neurol India* 2002;50:217
- Rasmussen GL, Holme S. 1992. Bilateral epidural hematomas, *Ugeskr Laeger*, 20;154(4):203-4.
- Rivas JJ, Lobato RD, Sarabia R, Cordobés F, Cabrera A, Gomez P. 1988. Extradural hematoma: analysis of factors influencing the courses of 161 patients, *Neurosurgery*, 23(1):44-51.
- Setti S. Rengachary, *Neurosurgery*, second edition, volume II, Pathology of closed head injury, chapter 261
- Sonne NM Tonnesen H. 1992, The influence of alcoholism on outcome after evacuation of subdural haematoma, *Br J Neurosurg.*, 6:125-130
- Sullivan PT, Jarvik JG, Cohen WA. 1999. Follow-up of conservatively Managed Epidural hematomas: Implications for timing of repeat CT. *Am J Neuroradiol*, 20:107-113.
- TIAN Heng-li et al, 2008. Risk factors related to hospital mortality in patients with isolated traumatic acute subdural haematoma: analysis of 308 patients undergone surgery, *Chin Med J.*, 121(12):1080-1084
- Wong CW. 1994. The CT criteria for conservative treatment--but under close clinical observation--of posterior fossa epidural hematomas. *Acta Neurochir (Wien)*. 126(2-4):124-7.
- Yanaka K, Kamezaki T, Yamada T, et al. 1993. Acute subdural hematoma prediction of outcome with a linear discriminant function. *Neurol Med Chir (Tokyo)*33:552-558.
