



RESEARCH ARTICLE

TREATMENT OF MULTIPLE GINGIVAL RECESSION BY BRIDGE FLAP
TECHNIQUE - A CASE REPORT

*¹Dr. Kokila, ¹Dr. Tamilselvi, ²Dr. Esther Nalini ³Dr. Renuka Devi and ³Dr. Arunkumar Prasad

¹Senior Lecturer, Department of Periodontics, KSR Institute of Dental Science and Research,
Tiruchengode, Tamilnadu, India

²Professor and Head of the Department, Department of Periodontics, KSR Institute of Dental Science and
Research, Tiruchengode, Tamilnadu, India

³Professor, Department of Periodontics, KSR Institute of Dental Science and Research,
Tiruchengode, Tamilnadu, India

ARTICLE INFO

Article History:

Received 29th March, 2018

Received in revised form

22nd April, 2018

Accepted 24th May, 2018

Published online 30th June, 2018

Key Words:

Gingival recession,

Root coverage, Bridge flap,

Vestibular deepening.

ABSTRACT

One of the most common esthetic concerns associated with periodontal tissue is gingival recession. Gingival recession is the exposure of root surface due to a displacement of the gingival margin apical to cement-enamel junction. Various surgical techniques are described such as free gingival graft, coronally repositioned flap, connective tissue graft, guided tissue regeneration and tissue engineering to correct the mucogingival problems and to cover the denuded root surfaces. This case report presents a bridge flap technique, which is a combination of coronally repositioned flap and vestibule extension procedure, which can be used to cover the multiple gingival recession. The treated case revealed adequate root coverage and increase in width of the attached gingiva at three months follow up.

Copyright © 2018, Kokila et al. This is an open access article distributed under the Creative Commons Attribution License, which permits unrestricted use, distribution, and reproduction in any medium, provided the original work is properly cited.

Citation: Dr. Kokila, Dr. Tamilselvi, Dr. Esther Nalini Dr. Renuka Devi and Dr. Arunkumar Prasad. 2018. "Treatment of multiple gingival recession by bridge flap technique - A Case report", *International Journal of Current Research*, 10, (06), 70959-70962.

INTRODUCTION

Gingival recession is defined as the exposure of root surface due to a displacement of the gingival margin apical to cement-enamel junction (Kassab and Cohen, 2003). The term marginal tissue recession was first proposed by Maynard and Wilson in 1979. The etiology of gingival recession is multifactorial and several factors play an important role in the development of gingival recession. The common factors are faulty tooth brushing, periodontal disease, tooth malpositioning, high frenal pull, shallow vestibule, inadequate width of gingiva, thin alveolar bone, improper restoration, orthodontic tooth movement, occlusal trauma and self mutilation (Bower, 1963). For many years, presence of an adequate zone of the gingiva was considered to be critical for the maintenance of gingival health and for prevention of progressive loss of connective tissue attachment. It has been proved that an inadequate zone of gingiva leads to gingival recession and subgingival plaque accumulation.

***Corresponding author: Dr. Kokila**

Senior Lecturer, Department of Periodontics, KSR Institute of Dental Science and Research, Tiruchengode, Tamilnadu, India

DOI: <https://doi.org/10.24941/ijcr.31260.06.2018>

So, various studies concluded that, minimum 2mm of keratinized gingiva is required to ensure the gingival health (Long and Loe, 1972). The marginal tissue recession results in dental hypersensitivity, pain, cervical root resorption, plaque retention, root caries and unesthetic appearance. Important function points in the treatment of mucogingival problems are to stop the progressive gingival recession and facilitate plaque control in the affected area and creation of adequate vestibule deep in the areas where there is a deficiency (Vijayalakshmi Rajram, 2015). Various techniques are available to correct mucogingival problems which can be gingival recession, shallow vestibule, inadequate width of attached gingiva and aberrant frenulum (Goldman, 1953).

Bilateral bridge flap is one of the techniques used to cover denuded root surfaces. The bridge flap was first introduced by Marggraf in 1981, which is a combination of coronally repositioned flap and modified Edlan and Mejchar vestibuloplasty technique. The advantages of this technique are that it does not require both second surgical site and separate frenectomy procedure (Marggraf, 1985). This article reports a case treated with bridge flap technique.

Case Report

A male patient aged 38 years reported in the department of periodontics with the chief complaints of hypersensitivity and receding gums in lower right front and back tooth region of jaw. Patient had no relevant medical history and was not under any medication. Clinical examination revealed an inadequate zone of attached gingiva with shallow vestibule. The recession was class II according to Millers' classification in relation to 42, 43 and 44 region. The recession was about 4mm in relation to 42, 43 and 3mm in relation to 44. Intraoral periapical radiograph in relation to 42, 43, and 44 revealed adequate bone supports in interdental areas. The width of attached gingiva was 2mm on 42, 43 and 44. Bridge flap technique was planned for root coverage in 42, 43 and 44. The surgical technique was explained to the patient and informed consent was obtained. Scaling and root planning was done prior to surgery.

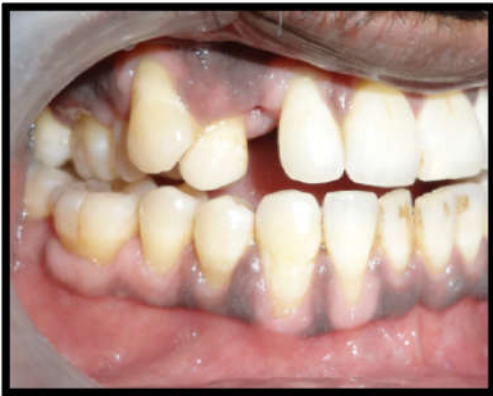

Figure 1. Pre operative view

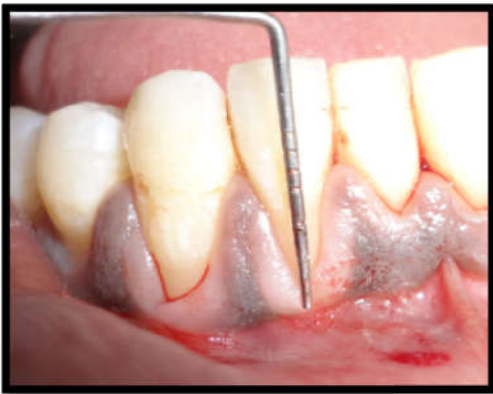

Figure 2. Insufficient width of attached gingiva

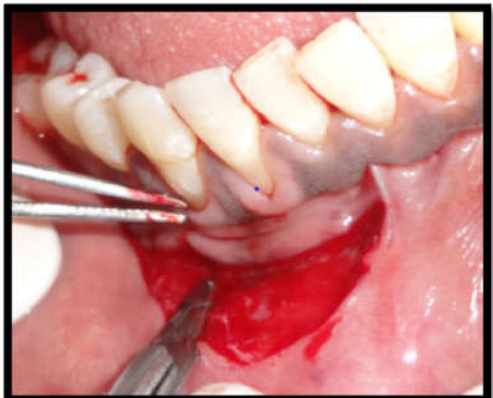


Figure 3. Arch shaped incision

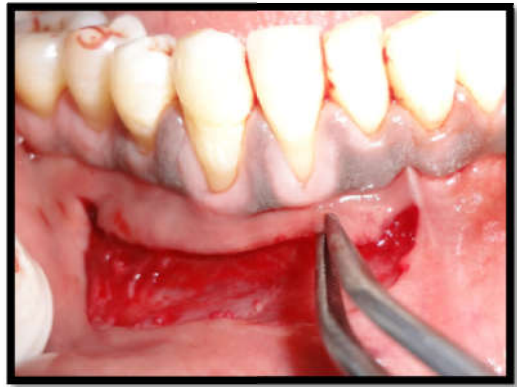

Figure 4. Split thickness flap

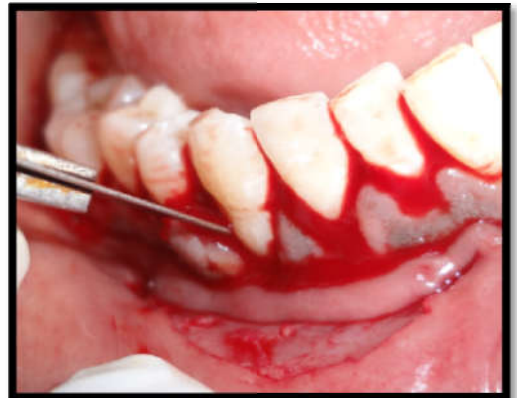

Figure 5. Sulcular incision

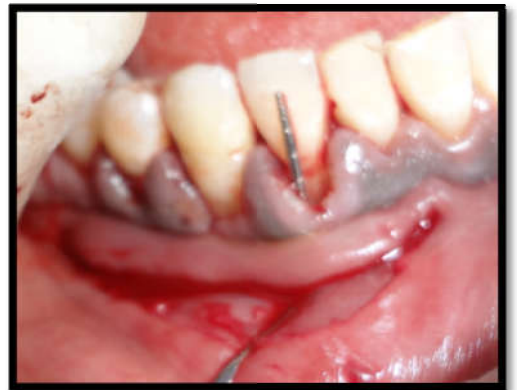

Figure 6. Bridge flap elevated

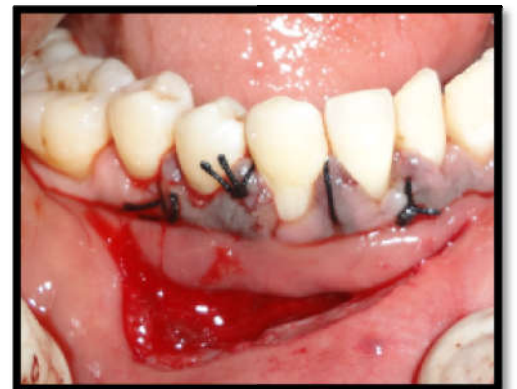

Figure 7. Bridge flap coronally positioned and sutured

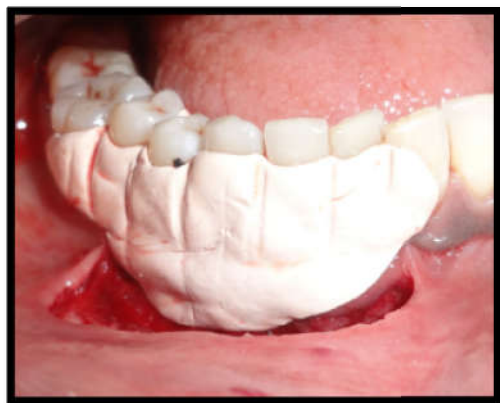


Figure 8. Periodontal pack placed

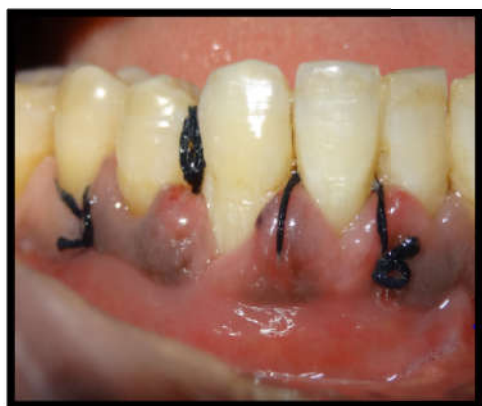

Figure 9. Post operative view after 1 week

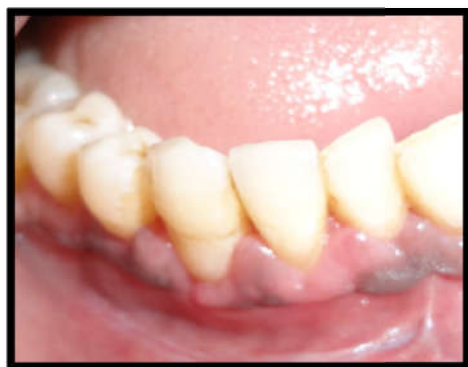

Figure 10. Post operative view after 3 months

Surgical Technique

The bridge flap technique is a combination of coronally repositioned flap and modified vestibuloplasty procedure by Edlan and Mejchar. After a period of 4 weeks, the patient was re-evaluated and the surgical procedure was performed under local infiltration of 2% lignocaine combined with 1:100,000 epinephrine.

- The first incision is arch shaped with a distance to the vestibule of approximately $2xGR+2$ mm. This is necessary in order to produce a sufficiently wide bridging flap, for sufficient blood supply.
- A split thickness flap was elevated in a coronal direction and an incision into the periosteum was placed at its base.

- This flap was elevated in a coronal-apical direction after a sulcular incision.
- The whole bridge flap was coronally repositioned to cover the denuded root surface and pressed to the alveolar bone at least for 3 minutes to avoid hematoma.
- The sling suture was placed. After suturing periodontal dressing was given.

Post operative instructions were given to the patient. Amoxicillin 500 mg thrice a day for 5 days and analgesic (Ibuprofen 400 mg and paracetamol 500 mg combination) twice a day for 3 days was prescribed. The patient was instructed to rinse his mouth with chlorhexidine (0.2%) two times a day for 4 weeks. Patient was recalled after 2 weeks for suture removal. Healing was satisfactory. Adequate root coverage was obtained in 3 months post operative follow up.

DISCUSSION

One of the most common esthetic concerns associated with periodontal tissue is gingival recession. The correction of gingival recessions is an important issue in the field of periodontal plastic surgery (Sana Farista, 2015). A wide variety of periodontal plastic surgical procedures have been described such as lateral sliding flap, free gingival graft, double papilla flap, coronally repositioned flap, connective tissue graft, guided tissue regeneration and tissue engineering to correct mucogingival problems and to cover the denuded root surfaces (Cortellini, 1991). An evaluation of adequate width of attached gingiva in patients with multiple recession is an important factor before deciding the correct procedure for root coverage as less than 2mm of attached gingiva and thin gingival tissue will increase the risk of gingival recession and facilitate subgingival plaque formation because of incomplete pocket closure (Chambrone *et al.*, 2010) and (Kassab and Cohen, 2003).

Marggraf, in 1985 presented surgical technique namely, the double lateral sliding bridge flap technique, which is a combined Edlan-Mejchar vestibuloplasty technique with a coronally repositioned flap. In this method, the flap which covers a denuded root surface is supplied by plasmatic circulation from capillaries in the adjacent portion of the gingiva, allowing it to survive and thus it creates healthy, functional and esthetic results that appear to be resistant of further recurrence. The bridge flap indicated when a single surgical procedure is desired to unavoidably cover the denuded root surfaces, in cases of inadequate zone of keratinized gingiva and also to increase the width of the attached gingiva with vestibular deepening at one step (Verma, 2013).

In the original Edlan and Mejchar technique, which was developed to deepen the vestibule and not to cover gingival recession, there was a alveolar bone exposure. But in this modification there is no alveolar bone exposure. This will certainly explain the uncomplicated and rapid healing in most cases. Also in this technique, a coronally repositioned flap could be used for root coverage even in the presence of an attached gingival width of less than 3mm (Marggraf, 1985) and (Edlan and Mejchar, 1963). The main advantages of this procedure are that it does not require a second surgical site, as in free soft tissue grafting methods and a separate frenectomy procedure (Marggraf, 1985). Miller, in 1987 defined complete

root coverage in clinical term as location of soft tissue margin at the cement-enamel junction, presence of clinical attachment to the root, a sulcus depth of 2mm or less and absence of bleeding. Treatment approaches used in the present case suggest that a combination of two surgical modalities can be successful for the management of multiple teeth recession.

Conclusion

Several surgical techniques are described in the literature to correct mucogingival problems and to cover denuded root surfaces. Successful treatment of multiple recessions is based on the uses of predictable periodontal plastic surgical techniques. Appropriate case selection and careful preoperative diagnosis are the prerequisites for improving surgical success. In this case, lateral bridge flap may provide a satisfactory solution in the multiple gingival recessions. But further follow up for a long period is necessary to improve the success rate of this technique.

REFERENCES

- Bower, G.M. 1963. A study of the width of the attached gingival. *J Periodontol.* 34: 201-9.
- Chambrone, L., Sukekava, F., Araujo, M.G., Pustiglioni, F.E., Chambrone, L.A. and Lima, L.A. 2010. Root coverage procedures for the treatment of localised recession – type defects: A Cochrane systematic review. *J Periodontol.* 81: 452-78.
- Cortellini, P., Pini Prato, G.P., Desanctis, M., Baldi, C. and Clauser, C. 1991. Guided tissue regeneration procedure in the treatment of a bone dehiscence associated with a gingival recession: A case report. *Int J Periodontics Restorative Dent.* 11: 460-7.
- Edlan, A. and Mejchar, B. 1963. Plastic surgery of the vestibule in periodontal therapy. *Int Dent J.* 13:593-7.
- Goldman, H.M. 1953. *Periodontia.* 3rd. St Louis: C.V.Mosby Co. 552-61.
- Kassab, M.M. and Cohen, R.E. 2003. The etiology and prevalence of gingival recession. *J AM Dent Assoc.* 134: 220-5.
- Lang, N.P. and Loe, H. 1972. The relationship between the width of the keratinized gingival and gingival health. *J Periodontol.* 43: 623-7.
- Marggraf, E. 1985. A direct technique with a double lateral bridging flap for coverage of denuded root surface and gingival extension. *Clinical evaluation after two years. J Clin Periodontol.* 12: 69-76.
- Maynard, J.C. and Willson, R.D. 1979. Physiological dimensions of the periodontium significant to the restorative dentist. *J Periodontol.* 50: 170-4.
- Miller, P.D. Jr. 1987. Root coverage with free gingival graft. *J Periodontol.* 58: 674-681.
- Sana Farista., Lynn Johnson., Gopinath., Deepak Thakur and Shanin Farista. 2015. Bridge flap technique – A single step solution to multiple mucogingival problems. *International Journal of Oral Health and Medical Research.* 2(2):64-7.
- Verma, P.K., Srivastava, R., Chaturvedi, T.P. and Gupta, K.K. 2013. Root coverage with bridge flap. *J. Indian Society of Periodontology.* 17(1): 120-3.
- Vijayalakshmi Rajaram., Ramakrishnan Theygarajan., Ashwath Balachandra., Geeth Aari and Anilkumar Kanakamedala. 2015. Platelet rich fibrin in double lateral sliding bridge flap procedure for gingival recession coverage: An original study. *Indian Society of Periodontology.* 19(6): 665-670.
