



RESEARCH ARTICLE

PLASMA CELL MUCOSITIS OF LOWER LIP- A RARE CASE REPORT WITH LITERATURE REVIEW

^{1*}Dr. Prashant Tamgadge, ²Dr. Rashmi wasekar, ³Dr. Heena Mazhar, ⁴Dr. Rajdeep Singh,
⁵Dr. Pramod Krishna, B. and ⁶Dr. Sushant kumar Soni

^{1,3,4,5,6} Dept of Oral and Maxillofacial surgery Chhattisgarh Dental College and Research Institute, Rajnandgaon
²Dept of Oral Medicine and Radiology Chhattisgarh Dental College and Research Institute, Rajnandgaon

ARTICLE INFO

Article History:

Received 17th April, 2018
Received in revised form
26th May, 2018
Accepted 07th June, 2018
Published online 30th July, 2018

Key Words:

Plasma Cell Mucositis,
Plasma Cell Cheilitis, Oral Papillary
Plasmacytosis.

ABSTRACT

Plasma cell mucositis is a chronic, multifocal, non-neoplastic plasma cell proliferative disease of upper aerodigestive tract having unknown etiology, very rare condition with less than 50 cases reported in literature till now. The present case reported unifocal variant of such lesion of lower lip in elderly female patient presenting clinically as painless papular growth of oral commissure having nodular mucosal horns with erythematous to velvety surface changes extending towards lower lip since last one year associated with pain and pharyngitis. The histopathologic Section shows overlying squamous epithelium with marked acanthosis, hyperkeratosis and papillomatosis along with patchy fibrosis and dense plasma infiltrate. The significance of this case is the differentiation of a benign disease from one that is potentially life threatening.

Copyright © 2018, Prashant Tamgadge et al. This is an open access article distributed under the Creative Commons Attribution License, which permits unrestricted use, distribution, and reproduction in any medium, provided the original work is properly cited.

Citation: Dr. Prashant Tamgadge, Dr. Rashmi wasekar, Dr. Heena Mazhar, Dr. Rajdeep Singh, Dr. Pramod Krishna, B. and Dr. Sushant kumar Soni, 2018. "Plasma cell mucositis of lower lip- a rare case report with literature review.", *International Journal of Current Research*, 10, (07), 71163-71165.

INTRODUCTION

Plasma-cell mucositis (PCM) is one of the rare idiopathic, chronic, multifocal, non-neoplastic proliferative plasma cell disorder of the mucous membrane of oral cavity and upper aerodigestive tract. It is characterized histopathologically as dense infiltration of plasma cells in lamina propria of mucous membrane without any history of premalignant lesion, fungal infection or tuberculosis (White, 1986). In 1952, Zoon first described plasma cell infiltrates in the glans penis, which he called as balanitis plasma cellularis, which later on called as Zoon's balanitis (Zoon, 1952). Other anatomical sites reported in literature with plasma cell infiltrate are the vulva, gingiva, buccal mucosa, palate, nasal aperture, lips, tongue, epiglottis, larynx, pharynx, lower respiratory tract, conjunctivae, skin and other orificial mucosa (Solomon *et al.*, 2008; Ferreiro *et al.*, 1994; Bharti, 2003). Plasma cell mucositis of lower lip also can be called as plasma cell cheilitis presents as flat-to-slightly raised, circumscribed, eroded plaque or patch on the lower lip of an elderly person (Farrier, 2008). The cause is unknown or immune-mediated, but patients usually responds to steroids, either topical or intralesional, or oral griseofulvin (Zoon, 1952; Ferreiro *et al.*, 1994).

Here, we describe a patient whose lip lesion was resistant to topical steroids, but resolved by systemic steroids.

Case Report: A 65-years-old female reported to the Department of Oral and Maxillofacial Surgery complaining of painless growth on left side of lower lip since 1 year. History revealed that it was started as a small pea size lesion which gradually increases to involve lip commissure, lower lip extending towards mentolabial fold left side in last one year duration. Neither of her family members reported such type of lesion. On extra-oral clinical examination, we noticed deep erythematous, papule on lower lip with two spike like nodular mass associated with mild pain from 2-3 months along with sore throat. (Figure 1, 2) No history of bleeding, pus discharge from the lip lesion was noticed by patient. Intra-orally, papular lesion extends from vermilion border to lower lip vestibule on left side. On the basis of clinical and radiographic findings, a provisional diagnosis of melanoma of lip was given. The routine hemogram was carried out and found to be within normal limits. After that, excisional biopsy of lip lesion was done under local anesthesia which on histopathological examination revealed a overlying squamous epithelium with marked acanthosis, hyperkeratosis, papillomatosis and dense plasma infiltrate in lamina propria. Most plasma cells are morphologically normal with paranuclear hoff alongwith some binuclear plasma cells and lymphocytes (Figure 3).

*Corresponding author: Dr. Prashant Tamgadge,
Dept of Oral and Maxillofacial surgery Chhattisgarh Dental College and Research Institute, Rajnandgaon
DOI: <https://doi.org/10.24941/ijcr.31320.07.2018>

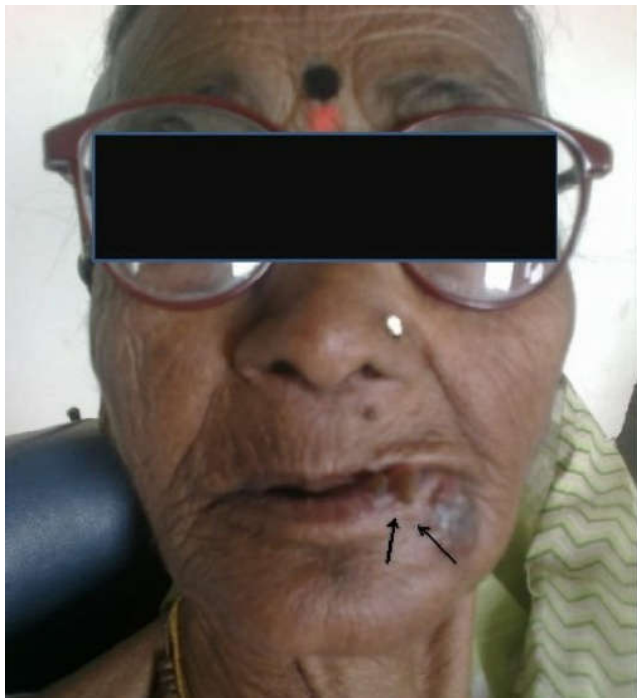

Figure 1. Extraoral frontal view

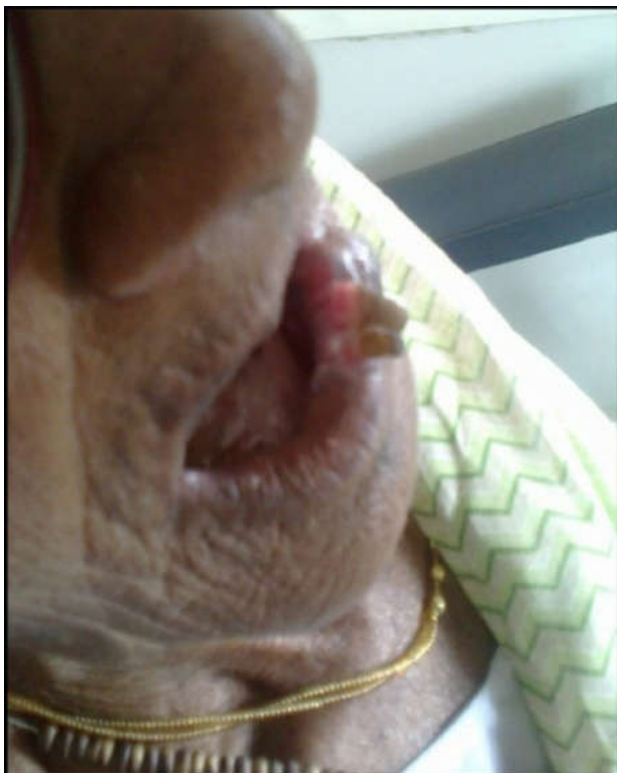


Figure 2. Extraoral view showing horn projections

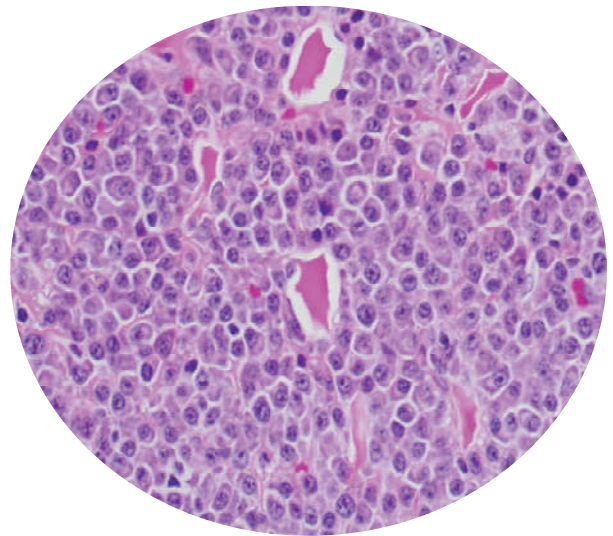


Figure 3. High power microscopy: H and E staining shows sheets of plasma cells intermixed with scattered small lymphocytes

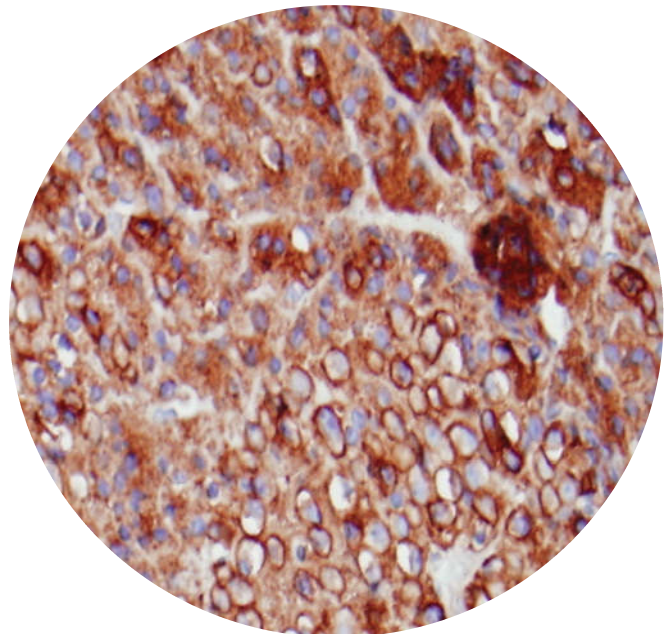


Figure 4. Positive staining for D138

DISCUSSION

Immunohistochemical study of the biopsy material was done which revealed the polyclonal plasma cell infiltrating which stains positive for CD138, a marker for plasmacytoid cells (Figure 4). Thus, the final diagnosis of plasma cell mucositis was done. Then, the patient was started with 1% topical hydrocortisone cream, but this did not give any response. She was therefore given a reducing course of oral prednisolone starting on 30 mg/day which reduces size of lesion dramatically. Now, she is on maintenance dose of 5 mg/day which we plan to further taper her medication.

Plasma cell mucositis of the lower lip is the most rare proliferative plasma cell disorder of orificial mucous membranes with an idiopathic origin. Till now, only 30 cases of it which affects the upper aerodigestive tract has been reported in the literature with variety of names like plasma cell orificial mucositis, idiopathic plasmacytosis, mucous membrane plasmacytosis and oral papillary plasmacytosis. Most commonly reported in males with age range of 25-85 years. Solomon *et al* in 2008 reviewed 22 cases of upper aerodigestive tract and found their etiology associated with synchronous or metachronous autoimmune diseases (Solomon *et al.*, 2008). Clinical presentation of it is variable, ranging from florid erythematous mucosa having papillomatous, cobblestone, nodular, velvety or granulomatous surface changes (White *et al.*, 1986). The lesion initially when small in size is completely asymptomatic, but gradually enlarges, erodes and becomes painful causing dysphagia, dysphonia depending on the site affected.

Management ranges use of steroids, immunosuppressant drugs, oral griseofulvin, liquid nitrogen, radiotherapy, and surgical excision. Steroids (topical, intralesional or systemic) are commonly used as first-line therapy. Immunosuppressive agents, like topical tacrolimus, cyclosporin, methotrexate, chlorambucil and dapsone etc also suggested with limited effectiveness (Gupta *et al.*, 2014; Madhavarajan, 2015). Surgical intervention like resection, tracheostomy and laser excision can be done if inflammation causes subglottic oedema and compromises airway. No progression to plasma cell neoplasm reported in literature (Solomon *et al.*, 2008; Galvin *et al.*, 2016). The clinical differential diagnosis of oral PCM includes sarcoidosis, Wegener granulomatosis, rhinoscleroma, mucous membrane pemphigoid, pemphigus, erosive lichen planus, erythroplasia, squamous cell carcinoma, allergic gingivostomatitis, and fungal infections. When the condition is limited to the lips, it must be differentiated from allergic contact mucositis, cheilitis granulomatosa, Melkersson-Rosenthal syndrome, plasmacanthoma, and angioedema (Puvanendran *et al.*, 2012).

Conclusion

The unifocal variant of plasma cell mucositis of lower lip is a rare plasma cell lesion whose diagnosis and management are challenging. Thus, inclusion of it as a rare differential diagnosis should be considered when treating mucositis that appears refractory to conventional treatment.

Ethical Disclosures

Protection of human and animal subjects: The authors declare that no experiments were performed on humans or animals for this study.

Right to privacy and informed consent: The authors declare that no patient data appear in this article and written informed consent was taken from the patient.

Financial assistance: Authors not received financial assistance.

Authors' contributions: All authors participated in the creation of manuscript.

Conflict of interest: The authors declare that they have no competing interests.

REFERENCES

- Bharti R, Smith DR. 2003. Mucous membrane plasmacytosis: A case report and review of the literature. *Dermatol Online J.*, 9:15.
- Farrier JN, 2008. Perkins CS Plasma cell cheilitis. *British Journal of Oral and Maxillofacial Surgery.* 46:679-680.
- Ferreiro JA, Egorshin EV, Olsen KD, Banks PM, Weiland LH. Mucous membrane plasmacytosis of the upper aerodigestive tract. A clinicopathologic study. *Am J Surg Pathol.* 1994;18:1048-53.
- Galvin S, Bowe C, Esther M, Regan O, Conlon N, Stephen R, Claire M. 2016. Circumoral plasmacytosis/plasma cell orificial mucositis: a case series and a review of the literature. *Oral Surg Oral Med Oral Pathol Oral Radiol.*, 122:e77-e81.
- Gupta SR, Gupta R, Saran RK, Krishnan S. 2014. Plasma cell mucositis with gingival enlargement and severe periodontitis. *J Indian Soc Periodontol.*, 18:379-384.
- Madhavarajan S, Tighe J. 2015. Orofacial plasmacytosis: a management conundrum. *Br J Oral Maxillofac Surg.*, 53:399-402.
- Puvanendran M, Lieder A, Issing W. 2012. Plasma cell mucositis of oro- and hypopharynx: a case report. *Case Rep Otolaryngol.*, 304-36.
- Solomon LW, Wein RO, Rosenwald I, Laver N. 2008. Plasma cell mucositis of the oral cavity: Report of a case and review of the literature. *Oral Surg Oral Med Oral Pathol Oral Radiol Endod.* 106:853-60.
- White Jr JW, Olsen KD, Banks PM. 1986. Plasma cell orificial mucositis. Report of a case and review of the literature. *Arch Dermatol.* 122(11):1321-4.
- Zoon JJ. 1952. Differential diagnosis between chronic circumscribed benign plasmacellular balanitis and Queyrat's erythroplasia. *Ned Tijdschr Geneeskd.* 96(38):2349-53.
