



ISSN: 0975-833X

Available online at <http://www.journalcra.com>

International Journal of Current Research  
Vol. 10, Issue, 10, pp.74280-74282, October, 2018

DOI: <https://doi.org/10.24941/ijcr.32744.10.2018>

INTERNATIONAL JOURNAL  
OF CURRENT RESEARCH

## RESEARCH ARTICLE

# MORBIDLY ADHERENT CENTRAL PLACENTA PREVIA AT 22 WEEKS GESTATION: A CASE REPORT

\*N.V.S. Mahalakshmi, N. and Bhavani, A.

Department of Obstetrics and Gynecology, Sunshine hospitals, Secunderabad, India

### ARTICLE INFO

#### Article History:

Received 16<sup>th</sup> July, 2018  
Received in revised form  
20<sup>th</sup> August, 2018  
Accepted 25<sup>th</sup> September, 2018  
Published online 30<sup>th</sup> October, 2018

#### Key Words:

Caesarean,  
Adherent placenta,  
Hemorrhage,  
Obstetric Hysterectomy.

### ABSTRACT

Morbidly adherent Placenta (accreta/percreta) is one of the serious complications in pregnant women and is frequently associated with severe obstetric hemorrhage usually leading to hysterectomy. Placentation disorders has increased owing to increased cesarean deliveries, resulting in increased fetomaternal morbidity and mortality. Although repeated caesareans are one of the largest risk factors for the adherent placenta, increasing maternal age and parity, as well as other uterine surgeries also result in the same. Considering the level of complexity, a multidisciplinary team in a tertiary centre with expertise in managing morbidly adherent placenta should manage these suspected cases.

Copyright © 2018, Mahalakshmi and Bhavani. This is an open access article distributed under the Creative Commons Attribution License, which permits unrestricted use, distribution, and reproduction in any medium, provided the original work is properly cited.

Citation: N.V.S. Mahalakshmi, N. and Bhavani, A., 2018. "Morbidly Adherent Central Placenta previa at 22 weeks gestation: A Case Report", *International Journal of Current Research*, 10, (10), 74280-74282.

## INTRODUCTION

Placenta percreta is a potentially life-threatening obstetric condition that requires a multidisciplinary approach to management. The incidence of adherent placenta has increased and seems to parallel the increasing cesarean delivery rate (Placenta accrete, 2012). Women are at greatest risk of adherent placenta when they had myometrial damage caused by a previous cesarean delivery with either anterior or posterior placenta previa overlying the uterine scar. A prospective observational study found that in the presence of placenta previa, the risk of placenta accreta was 3%, 11%, 40%, 61%, and 67% for the first, second, third, fourth, and fifth or greater repeat cesarean deliveries, respectively and 1–5% risk in those with placenta previa without previous uterine surgery (Silver *et al.*, 2006). Advanced maternal age, multiparity, previous myomectomy, uterine instrumentation resulting in Asherman syndrome (Al-Serehi *et al.*, 2008), submucous leiomyomas (Hamar *et al.*, 2006), septic endometritis, thermal ablation, and uterine artery embolization (Pron *et al.*, 2005) are other risk factors. Implantation is characterized by fetal trophoblastic invasion of the maternal uterine tissues and the degree to which trophoblast invades appears to be a major determinant of pregnancy outcome. Excessive invasion leads to placenta adherent to myometrium with increased fetomaternal morbidity.

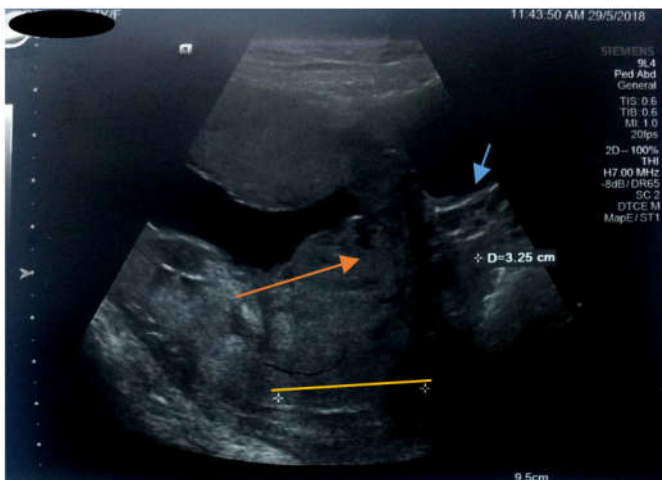
Inadequate endovascular invasion results in the pathophysiology of pre-eclampsia, preterm labour, and growth restriction (Norwitz, 2006). Depending on the invasion, placentation disorders are classified as placenta accreta (vera) where placenta attaches to myometrium, but does not invade, placenta increta if the placenta invades into the myometrium, but not beyond, and placenta percreta when it invades through the serosal layer and potentially beyond (Silver *et al.*, 2006). Grayscale ultrasonography is sensitive and specific enough for the diagnosis; magnetic resonance imaging may be helpful in ambiguous cases (Placenta accrete, 2012). The ultrasonographic features of placenta accreta are irregular placental lacunae, thinned out myometrium, loss of the retroplacental "clear space," protrusion of placenta into bladder, increased vascularity of uterine serosa-bladder interface (Comstock, 2005).

## CASE REPORT

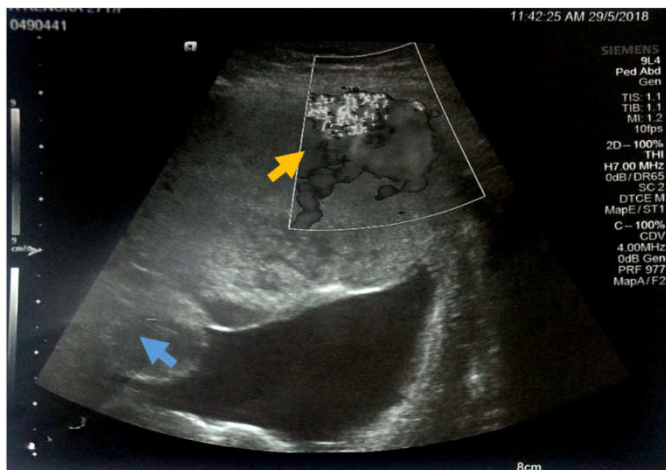
We would like to report a case of 27 year old Gravida 5, Para 3, living 2, abortion 1 at 22 weeks 3 days gestation with 3 previous cesareans and short interval pregnancy referred to our hospital in view of central placenta previa. She presented in the hospital with profuse painless vaginal bleeding since one day. Also she had similar episodes thrice in the past 3 weeks resulting in severe anemia (Hb-5.8gm%) for which she was treated in another hospital. Antenatal period was uneventful. Ultrasound

\*Corresponding author: N.V.S. Mahalakshmi, N.,

showed anterior central placenta previa. Her previous history of 3 previous cesarean sections and placenta previa with antepartum hemorrhage in her second pregnancy raised a suspicion of placentation disorder. Patient underwent cesarean delivery in her first uneventful pregnancy for cephalopelvic-disproportion 8 years back. Second pregnancy was terminated by cesarean section at 28 weeks due to central placenta previa with antepartum hemorrhage. Spontaneous miscarriage at 14 weeks in third pregnancy and fourth pregnancy 15 months back delivered by cesarean with uneventful postpartum period. No past medical co-morbidities. On admission, patient was pale (Hb-7gm%), with tachycardia. Abdominal examination showed 22 weeks soft nontender uterus with fresh vaginal bleeding. Ultrasound was repeated again suspecting placenta accreta showed single intrauterine live gestation at 22 weeks with placenta previa with focal placenta accreta.



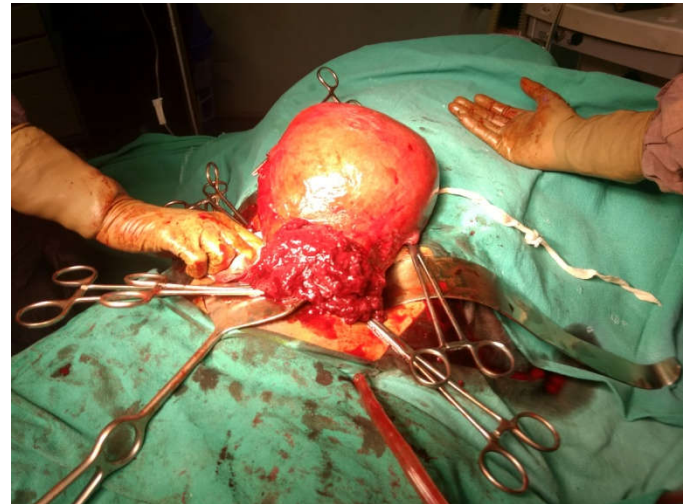
**Figure 1. Anterior Placenta covering cervical os: red arrow, yellow line: cervical length, blue arrow: bladder**



**Figure 2. Doppler shows Placental invasion into myometrium with extensive vascularity along anterior lower uterine segment extending upto bladder (yellow arrow), blue arrow- fetal parts**

After a detailed discussion of the diagnosis with the patient and weighing up of the pros and cons of continuing the pregnancy, the decision was taken to perform abdominal hysterectomy with conservation of ovaries. We also discussed expectant management as another potential option in this specific situation and explained the risks. The patient opted for hysterectomy to forestall potential serious injuries to organs and prevent hemorrhage and also due to lack of nearby hospital facilities in case of emergency. Patient was taken for emergency abdominal hysterectomy after transfusing 2 units of

packed RBCs. Intraoperatively, lower segment was thinned out and bladder densely adhered to the anterior wall of uterus. Bladder adhesions released with difficulty and found placenta extended upto bladder uterine interface with a rent on bladder base. Urologists were called for to assess and repair bladder rent. Fetus delivered with placenta and proceeded for Hysterectomy and bladder repair with suprapubic and urethral catheters. Intraoperatively one packed RBCs transfused.



**Figure 3. Placenta percreta**

Uterus with placenta sent for histopathology revealed trophoblastic tissue interspersed upto serosa giving placenta percreta as final diagnosis. Postoperatively, patient was monitored and discharged at stable condition on Day 4 after explaining postoperative care. Suprapubic and urethral catheters removed at 3 and 5 weeks respectively.

## DISCUSSION

The relative incidence of all types of adherent placenta has been rising for the past two decades, parallel to increasing caesarean rates. In these cases, resuscitation procedures and an urgent hysterectomy appears to be the treatment of choice (Shellhaas *et al.*, 2009). Antecedently, a conservative treatment, aiming at uterine rescue, was followed to a greater extent, based upon maximum possible removal of placental tissue manually. The conservative treatment can be achieved only in cases where bleeding is minimal. Alternative interventions include methotrexate injections, ligation of uterine artery or internal iliac artery, or angiographic embolization (Liu *et al.*, 2003). First line modalities for diagnosis include gray-scale ultrasound and color Doppler. MRI used as an adjunct tool to improve sensitivity when sonographic examination is equivocal or when the placenta cannot be reliably visualized. Overall, Ultrasonography is sufficient to diagnose placenta accreta, with a sensitivity of 77–87%, specificity of 96–98% (Placenta accrete, 2012). Transabdominal ultrasonography at 20 weeks revealing placenta previa should be confirmed with transvaginal ultrasound and should be repeated at 32 weeks gestation (Johnston A). RCOG considers Cell salvage, or autologous blood transfusion, in patients with estimated blood loss over 1500mL. Ensuring sufficient blood bank facilities for transfusion must be considered. It is still controversial regarding the benefit of interventional radiology with aortic balloon catheterization to reduce blood loss. Perioperative ureteric stent placement can facilitate palpation of ureters

intraoperatively to allow early identification of ureteral trauma (Belfort, Michael). Postpartum hemorrhage with maternal and fetal demise are of such high risk in these patients that early diagnosis and planning is the key to improved-outcomes (Johnston A).

### Conclusion

In spite of early diagnosis, Hysterectomy remains a common treatment for adherent placenta. This case highlights the need for further research to prevent the risk of massive hemorrhage. Evaluation of high-risk patients, referral to tertiary center with expertise in MRI should be considered for accurate antenatal diagnosis and improved outcome. Also we all should strive to prevent primary cesarean sections.

**Funding:** No funding sources

**Conflict of interest:** None declared

**Ethical approval:** Not required

### REFERENCES

- Al-Serehi A, Mhoyan A, Brown M, Benirschke K, Hull A, Pretorius DH. 2008. Placenta accreta: an association with fibroids and Asherman syndrome. *J Ultrasound Med.*, 27: 1623–8.
- Belfort, Michael A. Placenta accrete. *American Journal of Obstetrics & Gynecology*, Volume 203 , Issue 5 , 430 – 439.
- Comstock CH. 2005. Antenatal diagnosis of placenta accreta: a review. *Ultrasound Obstet Gynecol.*, 26: 89–96.
- Hamar BD, Wolff EF, Kodaman PH, Marcovici I. 2006. Premature rupture of membranes, placenta increta, and hysterectomy in a pregnancy following endometrial ablation. *J Perinatol.*, 26: 135–7.
- Johnston A., S. Paterson-Brown, “Placenta Praevia, Placenta Praevia Accreta and Vasa Praevia: Diagnosis and Management”. Royal College of Gynecology, Green-top Guideline No. 27 p.1-26.
- Liu X, Fan G, Jin Z, Yang N, Jiang Y, Gai M, et al. 2003. Lower uterine segment pregnancy with placenta increta complicating first trimester induced abortion: diagnosis and conservative management. *Chin Med J.*, 116:695-8.
- Norwitz E. 2006. Defective implantation and placentation: laying the blueprint for pregnancy complications. *Reprod Biomed Online*, 13: 591–599.
- Placenta accreta. Committee Opinion No. 529. American College of Obstetricians and Gynecologists. *Obstet Gynecol* 2012; 120: 207–11.
- Pron G, Mocarski E, Bennett J, Vilos G, Common A, Vanderburgh L. 2005. Pregnancy after uterine artery embolization for leiomyomata: the Ontario multicenter trial. Ontario UFE Collaborative Group. *Obstet Gynecol.*, 105: 67–76.
- Shellhaas CS, Gilbert S, Landon MB, Varner MW, Leveno KJ, Hauth JC, et al. 2009. The frequency and complication rates of hysterectomy accompanying cesarean delivery. Eunice Kennedy Shriver National Institutes of Health and Human Development Maternal-Fetal Medicine Units Network. *Obstet Gynecol.*, 114:224-9.
- Silver RM, Landon MB, Rouse DJ, Leveno KJ, Spong CY, Thom EA, et al. 2006. Maternal morbidity associated with multiple repeat cesarean deliveries. National Institute of Child Health and Human Development Maternal-Fetal Medicine Units Network. *Obstet Gynecol.*, 107: 1226–32.

\*\*\*\*\*