



ISSN: 0975-833X

Available online at <http://www.journalcra.com>

INTERNATIONAL JOURNAL  
OF CURRENT RESEARCH

International Journal of Current Research  
Vol. 11, Issue, 03, pp.2618-2623, March, 2019

DOI: <https://doi.org/10.24941/ijcr.34968.03.2019>

## RESEARCH ARTICLE

### EFFICACY OF DRILL FREE SCREWS VS SELF TAPPING SCREWS IN ZYGOMATICO MAXILLARY COMPLEX FRACTURES – A RANDOMIZED CONTROLLED TRIAL

\*Sarath, K., Sathyanarayanan, R. and Nithin Joseph Jude, B.

Department of Oral and Maxillofacial Surgery, Indira Gandhi Institute of Dental Science, Sri Balaji Vidyapeeth (Deemed to Be University) Puducherry, India

#### ARTICLE INFO

##### Article History:

Received 26<sup>th</sup> December, 2018

Received in revised form

03<sup>rd</sup> January, 2019

Accepted 19<sup>th</sup> February, 2019

Published online 31<sup>st</sup> March 2019

##### Key Words:

Drill Free Screws, Self Tapping Screws, Zygomatico Maxillary Complex Fracture, Open Reduction and Internal Fixation.

#### ABSTRACT

**Purpose:** To compare the efficacy of drill free screws and self tapping screws in the fixation of zygomatico maxillary complex fractures. **Materials and Methods:** A prospective randomized comparative study was planned comprising of 18 subjects, underwent fixation of zygomatico maxillary complex fracture. The subjects were block randomized into two groups—group A fixation using miniplates and self tapping screws and group B fixation using miniplates and self drilling screws. Intra operatively operating time, screw fixation time, fixation at operation, state of reduction at operation were evaluated. Postoperatively occlusal discrepancy, segmental mobility, anatomic reduction and signs of infection were evaluated. Chi square test and independent t test was used for Statistical analysis. **Results:** The mean operation time for fixing mini plates using self-tapping screws was 130(SD=15.61) seconds whereas for drill free screws was 108(SD=23) seconds. The mean screw fixation time for fixing mini plates using self-tapping screws was 337.2(SD=39.37) seconds whereas for drill free screws was 284.3(SD=104.94) seconds. The differences in measurements of fixation at operation, state of reduction at operation occlusal discrepancy, segmental mobility, anatomic reduction between 2 groups were not statistically significant. Post operative signs of infection was also not statistically significant among the 2 groups. **Conclusion:** On analysing the results of our study, apart from the operating and fixation time, the drill free and the self tapping screws are equally effective in terms of stabilization of fractures clinically and radiologically, intra-operative ease of handling and recording, intraoperative technical challenges and post operative complications. To conclude, drill free screws can be used as an alternative to self tapping screws in fixation of zygomatico maxillary complex fractures as the efficacy of both the screws was found to be equally effective. In our study, the sample size was limited and thus further studies are to be done in future to evaluate the efficacy of drill free screws.

\*Corresponding author: Sarath, K.

Copyright © 2019, Sarath et al. This is an open access article distributed under the Creative Commons Attribution License, which permits unrestricted use, distribution, and reproduction in any medium, provided the original work is properly cited.

Citation: Sarath, K., Sathyanarayanan, R. and Nithin Joseph Jude, B. 2019. "Efficacy of drill free screws Vs self tapping screws in zygomatico maxillary complex fractures – A randomized controlled trial", *International Journal of Current Research*, 11, (03), 2618-2623.

## INTRODUCTION

Maxillofacial trauma by their varying nature imparts a high degree of emotional as well as physical trauma to the patients. The anatomy of the cranio facial skeleton is complex in terms of alignment three dimensionally. As a result of this complexity isolated fractures of the facial bone is a rare incidence (Naveen Shankar *et al.*, 2012). Zygomatico maxillary complex fractures can also occur in isolation or in combination with other injuries such as mandibular, ophthalmologic, cranial, thoracic, abdominal trauma as well as upper and lower long bone injuries (Simpson and Mclean, 1995). The epidemiological data regarding facial fractures varies in type, severity and cause depending on the population studied. These diverse causes of maxillofacial fractures may be the result of differences in risk and cultural factors among countries and is influenced by the severity of injury (Killey, 1977). Self-tapping screws are generally used for the placement of miniplates.

Those screws require certain definite prerequisite like the preparation of a pilot hole with a diameter size equal to the screw core. The main disadvantage of drilling this pilot hole is that it is time consuming and may have other disadvantage like damage to nerves tooth roots, and drill bit breakage. Thermal necrosis of bone has also been observed using self-tapping screws (Norton, 2007). Another problem encountered is stripping of bone threads during screw insertion in thin cortical or soft cancellous bone. Also screw failure occurs due to over-drilled pilot hole occurs in thin cortical and cancellous bone (Le Fort, 1901). The purpose of the study is to compare the efficacy of drill free screws and self-tapping screws in reduction and fixation of zygomatico maxillary complex fractures.

## MATERIALS AND METHODS

A randomized prospective comparative study was planned to be conducted amongst 18 subjects reporting to the department

of oral and maxillofacial surgery between February 2017 and March 2018. The inclusion criteria comprised of

- Patients with zygomatico maxillary complex fractures
- Patients with orbital rim fractures,
- Patients in the age group of 18 to 65 years,
- Patients who are willing to participate in the study

The study was approved by the Institutional ethics committee (IGIDSRID2017NDPO2PGSKOMS) and informed consent was obtained from all patients. All the patients underwent reduction and fixation of zygomatico maxillary complex fracture were block randomized into two groups Group A underwent fixation of zygomatico maxillary complex fracture using miniplates and self tapping screws Group B underwent fixation of zygomatico maxillary complex fracture using miniplates and drill free screws. Pre operative radiographs and photographs of all the patients were taken and deformities were properly recorded. Blood investigations were done to elicit fitness for surgery. Blinding of either patient or operator was not possible. All the procedures pertaining to surgery were done by the same operator. Patients were reviewed with regular time intervals of 1<sup>st</sup> week, 1<sup>st</sup> month and 3<sup>rd</sup> month. AAOMS parameters were evaluated with the help of scoring system such as Operating time, Screw fixation time, Fixation at operation, State of reduction at operation, Occlusal discrepancies, Segmental mobility, Anatomic reduction, Infection at fracture site. Outcomes were measured by an assistant who was not a part of the study.

**Statistical analysis:** Comparisons of Operating time, Screw fixation time, Fixation at operation, State of reduction at operation, Occlusal discrepancies, Segmental mobility, Anatomic reduction between groups A and B were performed using chi square test and paired t test.

## RESULTS

There were no significant differences between groups in the Operating time, Screw fixing time, Fixation at operation, State of reduction at operation, Occlusal discrepancies, Segmental mobility, Anatomic reduction, Infection at the fracture site. The drill free screw group reported significantly less operating time and reduced screw fixation time than the self tapping screw group.

## DISCUSSION

The mean age of participants in drill free screw group was 30 (SD =7.03) and for self tapping screw group was 27(SD=5.8) respectively. The technique of using infraorbital incision for exposure of fractures along the inferior orbital rim was adopted from previous literature, were fractures are treated similar to our study. A prerequisite for the insertion of screws is the preparation of a pilot hole with a minimum diameter size equal to the screw's core. Though self tapping screws are the most engaged screws in maxillomandibular fixation, it has the disadvantage of predrilling. To overcome this disadvantage, new drill free screws are created by changing the screw shaft design. Results from various studies (Naveen Shankar *et al.*, 2012; Thomas and Hill, 2000; Mouzakes *et al.*, 2001) have proved that Drill-free screws provide intensive screw to bone contact, with minimal bone debris on insertion and minimal thermal damage to bone. The high initial stability from drill

free screws can be contributed to lesser bony damage compared with the self-tapping type. In the present study, drill free screws and 9 self-tapping screws were used on 18 patients with zygomatico complex fracture. The patients were recalled at a interval of 1 week, 1 month and 3 month intervals. The mean operation time for fixing mini plates using self-tapping screws was 130(SD=15.61) seconds whereas for drill free screws it was 108(SD=23) second. The mean screw fixation time for fixing mini plates using self-tapping screws was 337.2(SD=39.37) seconds whereas for drill free screws was 284.3(SD=104.94) seconds. This data suggests that in our study the mean operating time and screw fixation time is less in drill free screw group than self tapping screw group. In our study, out of 18 subjects who underwent zygomatico maxillary complex fracture fixation with miniplate and self-tapping screws and drill free screws, fixation for 14 subjects at operation was carried out by slight movement of plate but no movement of bone fragment; two of them underwent fixation with movement of bone fragment but with no need for other internal fixation. The fixation for the remaining one person was carried out with movement of bone fragment and need for other internal fixation and for one person it was carried out with no movement of plate or bone fragment. This data suggests that drill free as well as self tapping screws are equally effective in reducing plate movement.

The state of reduction at operation among the 9 subjects in self-tapping screw group was recored, among that for six (66.7%) subjects it was found to be less than 1mm gap between bone fragments and for the remaining three (33.3%) subjects it was 1-<5mm gap between bone fragments. Out of nine subjects who underwent zygomatico maxillary complex fracture fixation with miniplate and drill free screws, the state of reduction at operation for six (77.8%) subjects was less than 1mm gap between bone fragments; for one (11.1%) subjects was 1-<5mm gap between bone fragments and for the remaining one (11.1%) of them there was no gap between bone fragments. This suggests that the state of reduction at operation was effectively achieved through drill free screws as compared to that of self tapping screws in one subject. Otherwise, the subjects had 1-<5mm gap between bone fragments in both the groups. The state of anatomic reduction one week after operation was found to be less than 5mm of visible radiographic gap between fracture fragments among six (66.7%) subjects, for two (22.2%) subjects it was less than 5mm and for the remaining one (11.1%) subject there was no visible radiographic gap, in both the groups.

This suggests the equal effectiveness of drill free and self tapping screws in the state of anatomic reduction radiographically. The state of anatomic reduction radiographically one month after operation was also found to be of similar pattern in both the groups. The visible radiographic gap between fracture fragments among the subjects significantly reduced in both the group on third month evaluation. The signs of infection at the site of operation one week post-operatively was found to be of edematous (100%) in self tapping screws comparing to the drill free screws in which 8 of them showed edema and one of them showed erythema. The postoperative edema and erythema could be the result of overall surgical technique rather than the type of screws used. In our study, no adverse complications related to infection or wound dehiscence could be recorded except for only one patient who had pus discharge at third month evaluation and was treated by systemic antibiotics.

**Table 1. Comparison of operation time and screw fixation time for fixing mini plates using self-tapping screws and drill free screws**

Characteristic	Group	Mean±SD	P- value
Operation Time	Self-tapping screws	130±15.61	0.030
	Drill free screws	108±23.05	
Screw Fixation Time	Self-tapping screws	337.2±39.37	0.187
	Drill free screws	284.3±104.94	

**Table 2. Comparison of the method of fixation at operation between drill free screws and self-tapping screws in the fixation of zygomatico maxillary complex fractures**

Characteristic	Categories	Self-tapping screws N (%)	Drill free screws N (%)	P value
Fixation at operation	No movement of plate or bone fragment	0(0)	1(11.1)	0.572
	Slight movement of plate but no movement of bone fragment	7(77.8)	7(77.8)	
	Movement of bone fragment but no need for other internal fixation	1(11.1)	1(11.1)	
	Movement of bone fragment and need for other internal fixation	1(11.1)	0(0)	

**Table 3. Comparison of state of reduction at operation between drill free screws and self-tapping screws in the fixation of zygomatico maxillary complex fractures**

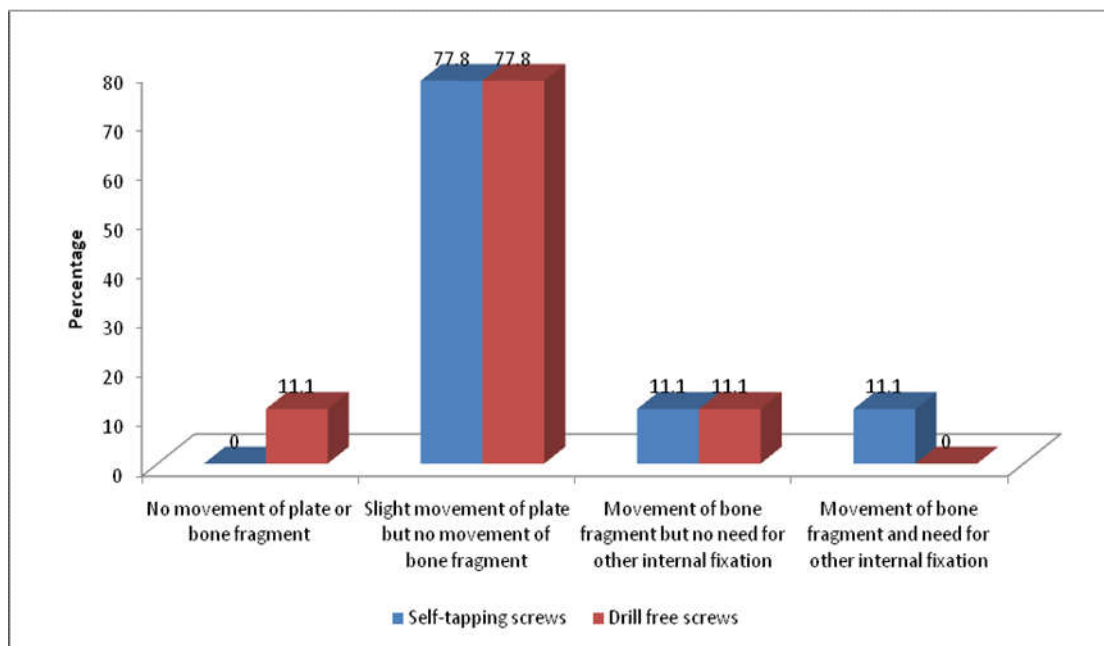
Characteristic	Categories	Self-tapping screws N (%)	Drill free screws N (%)	P value
State of reduction at operation	No gap between bone fragments	0(0)	1(11.1)	0.354
	Less than 1mm gap between bone fragments	6(66.7)	7(77.8)	
	1-<5mm gap between bone fragments	3(33.3)	1(11.1)	

**Table 4. Comparison of state of anatomic reduction one week post-operatively between drill free screws and self-tapping screws in the fixation of zygomatico maxillary complex fractures**

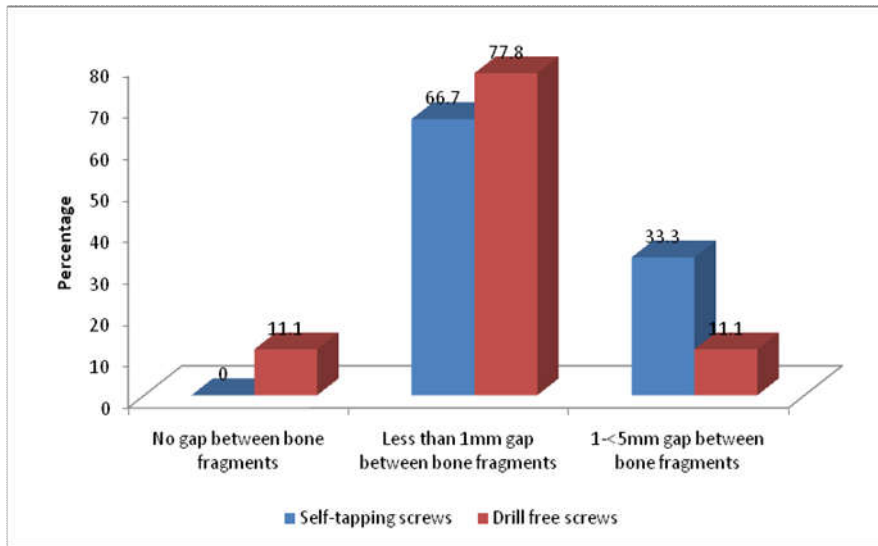
Anatomic reduction	Category	Self-tapping screws N (%)	Drill free screws N (%)	P value
After one week	No visible radiographic gap between fracture fragments	1 (11.1)	2(22.2)	0.717
	Less than 5mm of visible radiographic gap between fracture fragments	6 (66.7)	6(66.7)	
	More than 5mm of visible radiographic gap between fracture fragments	2(22.2)	1(11.1)	

**Table 5. Comparison of state of anatomic reduction one month post-operatively between drill free screws and self-tapping screws in the fixation of zygomatico maxillary complex fractures**

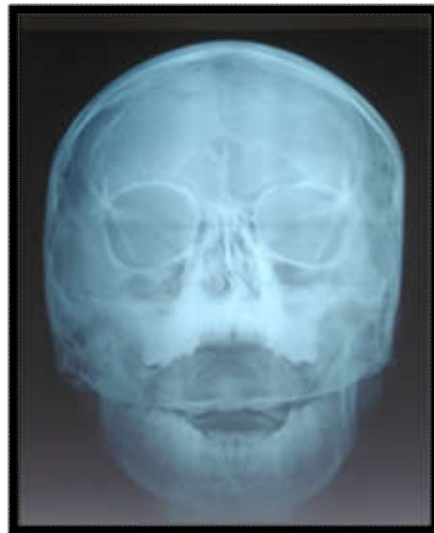Anatomic reduction	Category	Self-tapping screws N (%)	Drill free screws N (%)	P value
After one month	No visible radiographic gap between fracture fragments	1(11.1)	3(33.3)	0.257
	Less than 5 mm gap between bone fragments	8(88.9)	6(66.7)	
	More than 5mm of visible radiographic gap between fracture fragments	0(0)	0(0)	



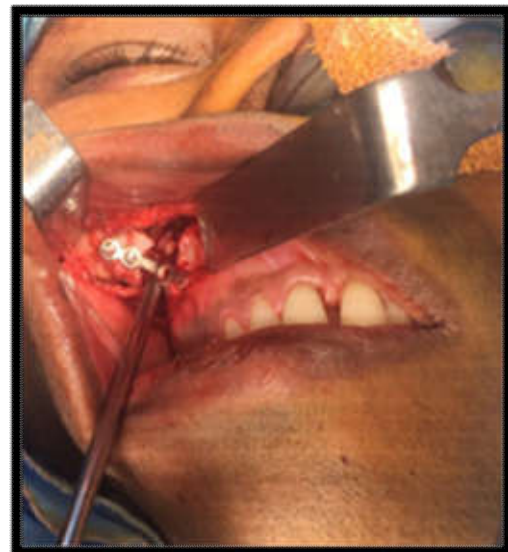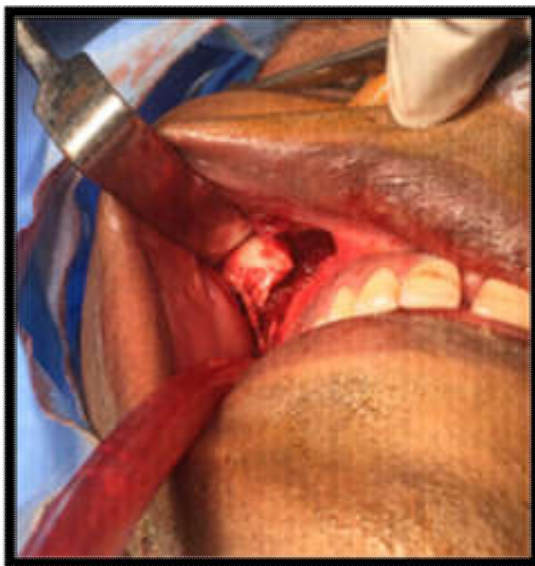**Graph 1. Comparison of the method of fixation at operation between drill free screws and self-tapping screws in the fixation of zygomatico maxillary complex fractures**



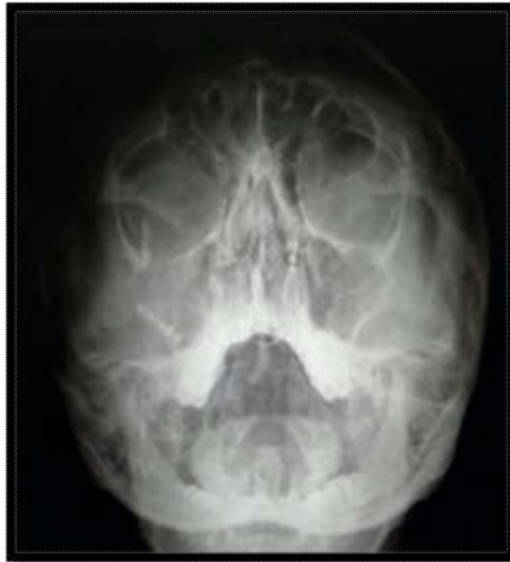Graph 2. Comparison of state of reduction at operation between drill free screws and self-tapping screws in the fixation of zygomatico maxillary complex fractures



Pre Operative Photographs



Intra Operative Photographs



**Post Operative Photographs**

The reason we tend to attribute for this is, poor patient compliance, as there was no screw loosening. Postoperative infection at the fractured site is not only the result of contamination, but is also related to reduced stability of fracture i.e. mobility of fractured segments (Avery and Johnson, 1992). Stability is considered as the best protection against infection, as movement in the presence of foreign bodies (i.e. loose screws) usually leads to infection and malunion. In this study, as there was minimal screw loosening and the stability of screws on fixation is much better. The increased stability of screws can be related to the higher screw/bone contact and significantly more residual bone in the region of the screw threads using drill free screws as well as self tapping screws (Manson *et al.*, 1985). The residual bone debris formed with self-drilling screws is not the result of the heat generated, but rather the result of biologically active bone tissue capable of reacting with the screw (Francel *et al.*, 1992).

Restoration of pre-morbid occlusion is one of the most important goals of the management of fractures of dentofacial region. The effect of not restoring the occlusion to its original condition is disabling and can cause severe effects especially on the temporo -mandibular joint. In our study, occlusion of the patients was checked preoperatively and during the follow up stages after surgery. The results indicated 100% subjects who had underwent zygomatico maxillary complex fracture fixation with miniplate and self-tapping screws as well as drill free screws had no occlusal discrepancy. This could be because as there was no obvious occlusal discrepancies preoperatively. Postoperative follow up of the patients for three months showed the improvement of the patients after treatment of 3 month duration. Almost all patients had pain on their first week after treatment. This is a normal finding post surgically due to inflammation. After first week the pain is reduced gradually and almost reached null condition (zero) within 1 month. None of the patient had pain from second month to third month. After one month, none of the patients showed any mobility in fractured segments. Rigidity of fractured segments produces a stable foundation for soft tissue growth and provides improved vascularity to the area and allows better healing of wound. It also prevents bacteria from being continually pumped through the fracture site thereby decreasing the chance of osteitis.

It is seen that more the mobility presents at the fracture site, greater the chances of infection.

### **Conclusion**

On analysing the results of our study, apart from the operating and fixation time, the drill free and the self tapping screws are equally effective in terms of stabilization of fractures clinically and radiologically, intra-operative ease of handling and recording, intraoperative technical challenges and post operative complications. Drill free screws needs less operating and fixation time compared to that of self tapping screws. To conclude, drill free screws can be used as an alternative to self tapping screws in fixation of zygomatico maxillary complex fractures as the efficacy of both the screws was found to be equally effective. In our study, the sample size was limited and thus further studies are to be done in future to evaluate the efficacy of drill free screws.

### **REFERENCES**

- Afzelius, L. and Rosén, C. 1980. Facial fractures. *International Journal of Oral Surgery.*, 9(1):25-32.
- Altonen, M., Kohonen, A. and Dickhoff, K. 1976. Treatment of zygomatic fractures: Internal wiring-antral-packing-reposition without fixation. *Journal of Maxillofacial Surgery*, 4:107-115.
- Ansari, M. 2004. Maxillofacial fractures in Hamedan province, Iran: a retrospective study (1987–2001). *Journal of Cranio-Maxillofacial Surgery*, 32(1):28- 34.
- Avery, C. and Johnson, P. 1992. Surgical glove perforation and maxillofacial trauma: to plate or wire?. *British Journal of Oral and Maxillofacial Surgery*, 30(1):31-35.
- Bos, R., Boering, G., Rozema, F. and Leenslag, J. 1987. Resorbable poly(L-lactide) plates and screws for the fixation of zygomatic fractures. *Journal of Oral and Maxillofacial Surgery*, 45(9):751-53.
- Brown, J., Fryer, M. and McDowell, F. 1952. Internal wire-pin fixation for fractures of upper jaw, orbit, zygoma and severe facial crushes. *Plastic and Reconstructive Surgery*, 9(3):276-83.



- Cook, H. and Rowe, M. 1990. A retrospective study of 356 midfacial fractures occurring in 225 patients. *Journal of Oral and Maxillofacial Surgery*, 48(6):574-78.
- Covington, D., Wainwright, D., Teichgraeber, J. and Parks, D. 1994. Changing patterns in the epidemiology and treatment of zygoma fractures. *The Journal of Trauma: Injury, Infection, and Critical Care.*, 37(2):243-48.
- Ellis, E. and Walker, L. 1996. Treatment of mandibular angle fractures using one noncompression miniplate. *Journal of Oral and Maxillofacial Surgery*, 54(7):864-71.
- Francel, T., Birely, B., Ringelman, P. and Manson, P. 1992. The Fate of Plates and Screws after Facial Fracture Reconstruction. *Plastic and Reconstructive Surgery*, 90(4):568-73.
- Gassner, R., Tuli, T., Hächl, O., Rudisch, A. and Ulmer, H. 2003. Cranio-maxillofacial trauma: a 10 year review of 9543 cases with 21067 injuries. *Journal of Cranio-Maxillofacial Surgery*, 31(1):51-61.
- Giroto, J., MacKenzie, E., Fowler, C., Redett, R., Robertson, B. and Manson, P. 2001. Long- Term Physical Impairment and Functional Outcomes after Complex Facial Fractures. *Plastic and Reconstructive Surgery*, 108(2):312-27.
- Haerle, F., Champy, M. and Terry, B. Stuttgart Atlas of Craniomaxillofacial Osteosynthesis: Microplates, Miniplates, and Screws, 2nd Ed. Germany Thieme Medical Publishers ISBN: 9783131164926. Pp. 240.
- Heidemann, W. and Gerlach, K. 1999. Clinical applications of drill free screws in maxillofacial surgery. *Journal of Cranio-Maxillofacial Surgery*, 27(4):252-55.
- Heidemann, W., Gerlach, K., Gröbel, K. and Köllner, H. 1998. Drill Free Screws: a new form of osteosynthesis screw. *Journal of Cranio-Maxillofacial Surgery*, 26(3):163-68.
- Heidemann, W., Terheyden, H. and Louis Gerlach, K. 2001. Analysis of the osseous/metal interface of drill free screws and self-tapping screws. *Journal of Cranio- Maxillofacial Surgery*, 29(2):69-74.
- Jackson, I., Somers, P. and Kjar, J. 1986. The Use of Champy Miniplates for Osteosynthesis in Craniofacial Deformities and Trauma. *Plastic and Reconstructive Surgery*, 77(5):729-36.
- Killey, H C. 1977. Fractures of the Middle Third of the Facial Skeleton. Bristol: John Wright & Sons Limited, pg.77.
- Klotch, D. and Gilliland, R. 1987. Internal Fixation vs. Conventional Therapy in Midface Fractures. *The Journal of Trauma, Injury, Infection, and Critical Care*. 27(10):1136-45.
- Lakshmi, N., Vivekanand, S., Amit, V., Srinivas, C. and Sridhar, S. 2012. Prospective blind comparative clinical study of two point fixation of zygomatic complex fracture using wire and mini plates. Published online Head Face Med. PMID: PMC3342088:doi: 10.1186/1746-160X-8-7.
- Le Fort, R. 1901. Etude experimentalesur les fractures de la machoiresuperiore. *Rev Chir.*, 23:208-27.
- Le Fort, R. 1901. Etude experimentalesur les fractures de la machoiresuperiore. *Rev Chir.*, 23:360-79.
- Le Fort, R. 1901. Etude experimentalesur les fractures de la machoiresuperiore. *Rev Chir.*, 23:479-507.
- Manson, P., Crawley, W., Yaremchuk, M., Rochman, G., Hoopes, J. and French, J. 1985. Midface Fractures. *Plastic and Reconstructive Surgery*, 76(1):1-10.
- Melmed, E. 1972. The Management of Severe Facial Fractures Using Box Frame Fixation.. 1972;14.'. *SA Medical Journal*, 14.
- Motamedi, M. 2003. An assessment of maxillofacial fractures: A 5-year study of 237 patients. *Journal of Oral and Maxillofacial Surgery*, 61(1):61-4.
- Mouzakes, J., Koltai, P., Kuhar, S., Bernstein, D., Wing, P. and Salsberg, E. 2001. The Impact of Airbags and Seat Belts on the Incidence and Severity of Maxillofacial Injuries in Automobile Accidents in New York State. *Arch Otolaryngol Head Neck Surg.*, 127(10):1189.
- Naveen Shankar, A., Naveen Shankar, V., Hegde, N., Sharma and Prasad, R. 2012. The pattern of the maxillofacial fractures – A multicentre retrospective study. *Journal of Cranio-Maxillofacial Surgery*, 40(8):675-79.
- Norton, N S. 2007. Netter's Head And Neck Anatomy For Dentistry. Philadelphia: *Saunders Elsevier*, pg.56.
- Nunamaker, D. and Perren, S. 1976. Force measurements in screw fixation. *Journal of Biomechanics*, 9(11):669-75.
- Paludetti, G., Almadori, G., Corina, L., Parrilla, C., Rigante, F. and Ottaviani, M. 2003. Midfacial Fractures: Our Experience. *Acta OtorhinolaryngolItal*, 23:265- 73
- Phillips, J. and Rahn, B. 1989. Comparison of Compression and Torque Measurements of Self-Tapping and Pretapped Screws. *Plastic and Reconstructive Surgery*, 83(3):447-56.
- Robertson, J. 1964. Recent Advances in Maxillo-facial Surgery. *Proc R Soc Med.*, 57(3):184.
- Schatzker, J., Sanderson, R. and Murnaghan, J. 1975. The Holding Power of Orthopedic Screws in Vivo. *Clinical Orthopaedics and Related Research*, 108:115-26.
- Simpson, DA. and Mclean, AJ. 1995. Mechanisms of Injury. In: David DJ, Simpson DA (Eds) Craniomaxillofacial Trauma, Vol. 101. Churchill Livingstone, pg.92.
- Sofferman, R., Danielson, P., Quatela, V. and Reed, R. 1983. Retrospective Analysis of Surgically Treated Le Fort Fractures: Is Suspension Necessary? *Archives of Otolaryngology - Head and Neck Surgery*, 109(7):446-48.
- Thomas, DW. and Hill, CM. 2000. Etiology and Changing Patterns of Maxillofacial Trauma. In: Booth PW, Schendel SA, Hausamen JE (Eds) Maxillofacial Surgery, Vol. Churchill Livingstone, 3, pg.273.
- Thorén, H., Snäll, J., Salo, J., Suominen-Taipale, L., Kormi, E., Lindqvist, C., et al., 2010. Occurrence and Types of Associated Injuries in Patients With Fractures of the Facial Bones. *Journal of Oral and Maxillofacial Surgery*, 68(4):805-10.
- Tuovinen, V., Erik Nørholt, S., Sindet-Pedersen, S. and Jensen J. 1994. A retrospective analysis of 279 patients with isolated mandibular fractures treated with titanium miniplates. *Journal of Oral and Maxillofacial Surgery*, 52(9):931-35.
- Wu, H., Zhu, Z., Li, Y., Duan, H. and Liu, J. 1998. Internal fixation with mini-titanium plate for midface fractures. *Hunan Yi Ke Da XueXueBao*. 23(1):65-72.

\*\*\*\*\*