



ISSN: 0975-833X

Available online at <http://www.journalcra.com>

International Journal of Current Research  
Vol. 11, Issue, 04, pp.2947-2949, April, 2019

DOI: <https://doi.org/10.24941/ijcr.35098.04.2019>

INTERNATIONAL JOURNAL  
OF CURRENT RESEARCH

## RESEARCH ARTICLE

### TREATMENT OF CLASS II DIVISION I BY POWERSCOPE –CASE REPORT

\*Ambati Dharanija, Monish. C. Reddy, Pradeep Raghav, Shalu Jain, Stuti Mohan  
and Sourabh Jindal

Subharti Dental College, India

#### ARTICLE INFO

##### Article History:

Received 27<sup>th</sup> January, 2019

Received in revised form

04<sup>th</sup> February, 2019

Accepted 27<sup>th</sup> March, 2019

Published online 29<sup>th</sup> April, 2019

##### Key Words:

Class II Malocclusion, Powerscope, Fixed Functional Appliance, CVMI Staging.

##### \*Corresponding author:

Ambati Dharanija

Copyright ©2019, Ambati Dharanija et al. This is an open access article distributed under the Creative Commons Attribution License, which permits unrestricted use, distribution, and reproduction in any medium, provided the original work is properly cited.

Citation: Ambati Dharanija, Monish. C. Reddy, Pradeep Raghav, Shalu Jain, Stuti Mohan and Sourabh Jindal, 2019. "Treatment Of Class II Division I By Powerscope –Case Report", International Journal of Current Research, 11, (04), 2947-2949.

#### ABSTRACT

Treatment of class II malocclusions poses a major challenge for orthodontist. Class II malocclusion due to mandibular retrognathism during active growth can be treated using removable myofunctional appliances. Fixed functional appliance are given in non compliant patient. The present case report shows efficiency of Powerscope in correcting mandibular retrognathism in a patient aged 14-year-old male patient with a chief complaint of irregularly placed upper front teeth. Diagnosis revealed retrognathic mandible, orthognathic maxilla, Class II skeletal base with average towards vertical growth pattern with end on molar and canine relation on both side, crowding in upper and lower arch, overjet of 6mm, overbite of 4 mm and maxillary mid line shifted towards right side by 1mm. The case was treated initially with MBT 0.22" prescription followed by Powerscope. Stable and successful results were obtained with improvement in facial profile, skeletal jaw relationship. Power scope proved to be effective in achieving correction by combination of skeletal and dental changes, also reduces time and helps in managing non-compliant patients.

#### INTRODUCTION

Class II malocclusion accompanied by skeletal discrepancy occurs due to maxillary prognathism or mandibular retrusion both. According to McNamara (McNamara, 1981) class II malocclusion due to mandibular retrusion is more common and occurs due to various etiological factors such as reduced mandibular length, posterior placement of condyle in glenoid fossa or functional mandibular shift. Management of such malocclusion is therefore a major challenge in terms of treatment planning and successful management. In growing patients, Myofunctional appliance achieves mandibular advancement by redirecting or impeding the maxillary growth with simultaneous stimulation of mandibular growth. Removable functional appliances such as activator, bionator, Twin block and Frankel regulator is advocated in patients where active growth is present (Chen, 2002). The use of fixed functional appliances like fixed twin block, Jasper Jumper, Herbst appliance, universal bite jumper, Ritto appliance, Eureka spring, Churro jumper, Forsus appliance etc. are commonly advocated in non-compliant patients who are in their deceleration phase of growth (Ritto, 2001). The effects seen by these appliances are mainly due to dento-alveolar changes rather than skeletal changes (Cozza, 2006). Dr. Andy Hayes developed Power Scope in conjunction with American Orthodontics in 2014 which is a derivative of the Herbs

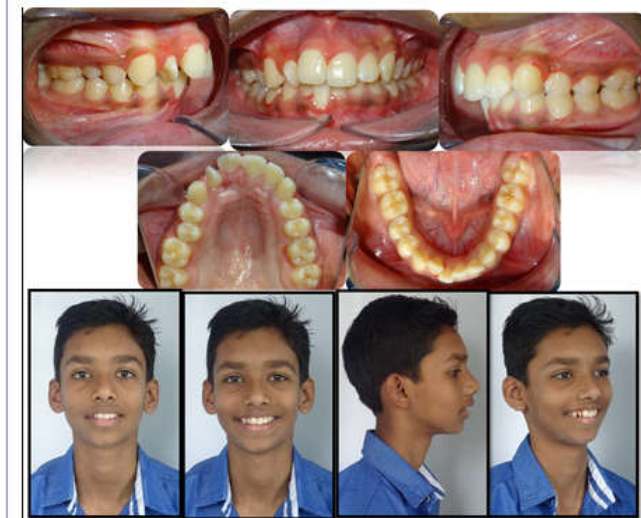
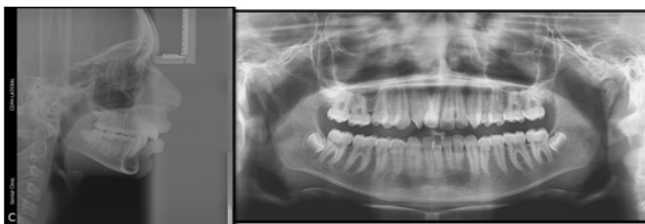appliance type II appliance. It is spring loaded rigid appliance which works on telescopic mechanism of action. It has ball and socket type joint hence provides lateral movements. It is comfortable and hence widely accepted by patients. For Orthodontists it is a simple appliance to install in a patient requiring less chair side time. This paper presents a case report in which a non-extraction approach for the treatment of skeletal Class II div I malocclusion with mandibular deficiency and impinging overbite has been treated using Power Scope.

**Diagnosis and treatment planning:** A 14-year-old male patient presented with a chief complaint of irregularly placed upper front teeth. On Clinical examination revealed obtuse nasolabial angle, lip incompetence, slightly convex profile with mandibular retrusion, posterior facial divergence and positive visual treatment objective. The intraoral findings reveals class II division I malocclusion with end on molar and canine relation on both side, crowding in upper and lower arch, overjet of 6mm, overbite of 4 mm and maxillary mid line shifted towards right side by 1mm (Figure 1). The cephalometric readings shows skeletal class II malocclusion ANB of 5°, retrognathic mandibular length with SNB 76°, average towards vertical growth pattern, proclined and forwardly positioned maxillary incisor and mildly proclined mandibular incisors (Figure 2), (Table 1).

**Table 1. Pre-treatment and post-treatment cephalometric readings of the patient's ateralcephalograms**

	Pre-treatment	Post-treatment
SNA	82°	82°
SNB	77°	79°
ANB	5°	3°
N ⊥ to Point A	-4 mm	-1.5 mm
N ⊥ to Pog	-16mm	-13 mm
LAFH	64mm	71.5 mm
Go-Gn to SN	28°	28°
Max. Length	84mm	85 mm
Mand. Length	100mm	108 mm
Facial Axis	7°	7°
Sum of Posterior Angles	391°	391°
UI to NA (Angle)	23°	23°
UI to NA (Linear)	5mm	3.5mm
LI to NB (Angle)	28°	33°
LI to NB (Linear)	5.5 mm	8 mm
LI to Mand. Plane	96°	99°
LI to APog	2mm	4.5mm
S Line (Upper)	3mm	2mm
S Line (Lower)	4mm	2mm

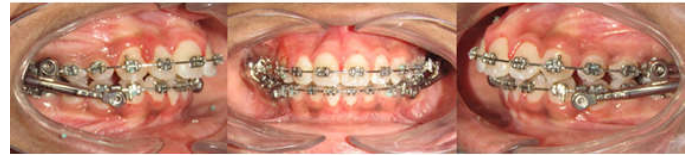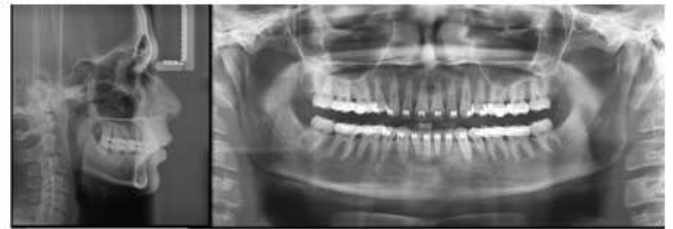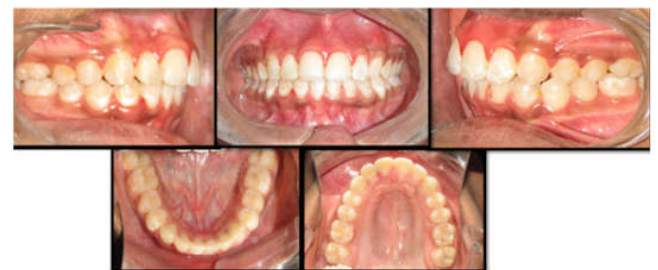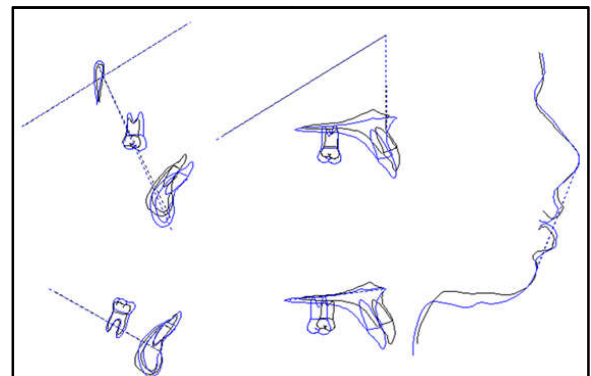
The patients reveal CVMI III staging. The panoramic radiograph showed the presence of all permanent teeth (Figure 3).

**Figure 1. Pre-treatment extra-oral and intra-oral photographs****Figure 2. Pre-treatment lateral cephalograms and OPG**

**Treatment objectives:** To correct crowding rotations and maintaining inter-canine and inter-premolar widths, improve facial profile, achieve adequate over jet and overbite relations and to obtain Class I canine and molar relation without extracting teeth.

**Treatment Progress:** Full fixed preadjusted Edgewise appliance MBT 0.022" prescription was placed to level and align both arches. After achieving the leveling and alignment within eight months and transpalatal arch placed in maxillary arch for reinforcement of anchorage. 0.019" × 0.025" stainless

steel arch wires were inserted after figure of eight ligation from first molar to first molar in both arches with 10° of lingual crown torque was given in in lower anteriors. A fixed functional Class II corrector appliance, the Power scope TM, was placed with more activation on left side to correct the lower dental midline deviation and improve the mandibular retrognathism and achieve Class I relationship on both side (Figure 4). After eight months, the Power scope appliance was removed. Finishing was accomplished with 0.019" × 0.025" TMA archwires and lighter .016" stainless steel lighter with vertical elastics for final settling. Final stage OPG, lateral cephalograms and photographs were taken (Figure 5, 6). Pre-treatment and posttreatment cephalometric readings were compared and superimpositions were made.

**Figure 3. Intra-oral photograph with the powerscope appliance****Figure 4. Final stage lateral cephalogram and OPG (before debonding)****Figure 5. Post-treatment extra-oral and intra-oral photographs****Figure 6. Cephalometric superimpositions**

Within total time period of 19 months; skeletal and dental Class I relationships had been attained, after which the fixed appliances were removed with lower lingual retainer placed.

### Treatment results

- Improved facial profile
- Increased mandibular length
- Proclination of upper and lower incisors
- Class I molar and canine relation achieved on both sides
- Increased lower anterior facial height
- Improved facial balance.

### DISCUSSION

Among all malocclusions, Class II malocclusion presents a constant challenge to the orthodontists. Class II malocclusions due to mandibular retrusion in growing patients are most commonly treated with functional appliance followed by fixed orthodontic appliances. The functional appliances work by initiating remodeling changes at the mandibular condyle and glenoid fossa, repositioning the mandibular condyle in the glenoid fossa and by autorotation of the mandibular bone (Pancherz, 1998). Fixed functional appliances are currently the most sought after treatment approach in place of removable functional appliances particularly in non-compliant growing skeletal class II patients. Among fixed functional appliance, PowerScope has been used for this case due to its advantage over others. It is one piece appliance that doesn't dislodge on various jaw movements. Customization of this appliance could be done with the help of crimpable shims provided by the manufacturers along with PowerScope armamentarium. The appliance allows quick and easy wire-to-wire installation preventing bond failures of bracket and buccal tube. The ball and socket joint at the two ends of the appliance allows excellent jaw movements reducing much of patient discomfort. Literature is abundant with studies on many fixed functional appliances such as Jasper jumper, Herbst, Universal bite jumper, Eureka Spring, and Forsus FRD, but no reports are currently available with regard to Power Scope. On comparing the cephalometric outcomes, a considerable improvement in skeletal, dental, and soft tissue parameters were observed at the end of Power Scope treatment. The entire period of treatment with PowerScope was uneventful. Post treatment cephalometric measurements revealed favourable sagittal skeletal changes showing no change in SNA (82°) throughout the treatment. A mandibular advancement was clearly evident as SNB angle increased from 77° to 79°, a 2° reduction in ANB angle and there was increase in effective mandibular length by 8mm. A mild increase in lower facial height within normal limits was noticed at the end of the treatment (Table 1).

The maxillary incisors angulation remained unchanged whereas mandibular incisors proclined by 2.5 mm linear and 5° angular after Power Scope correction (Table 1), (Figure 6). The slight proclination at the end of the treatment could be attributed to the force concentrated in the lower anterior segment during fixed functional appliance treatment. However, the use of MBT brackets (-6° torque in the lower incisor), molar to molar consolidation in both arches, cinching off the lower arch wire, and use of pre-torqued wire before insertion of the PowerScope has helped us to counteract the protrusive effect on mandibular incisors. A near to normal interincisal angle was established. The lower lip relation to E line improved greatly from 4 mm to 2 mm (Table 1), (Figure 6). The treatment could thus accomplish a well-balanced face with a pleasant smile which could be well ascertained from the superimposition of soft tissue and hard tissue. The results were stable and extremely satisfying for both the clinician as well as the patients.

### Conclusion

Powerscope proves to be a good cost-effective appliance in treating Class II skeletal malocclusion with shortened overall treatment time. Excellent results are achieved by limiting the side effects, minimizing the need for patient compliance, and avoiding appliance breakage. It achieves correction by combination of skeletal and dental changes.

### REFERENCES

- Chen JY., Will LA., Niederman R. 2002. Analysis of efficacy of functional appliances on mandibular growth. *Am J Orthod Dentofacial Orthop.*, 122:470-6.
- McNamara JA. 2013. Jr Components of class II malocclusion in children 8-10 years of age. *Angle Orthod.* 1981;51:177-202. Proffit WR, Field HW, Sarver DM. Contemporary Orthodontics 5th edn, CV Mosby Co
- ozza P., Baccetti T., Franchi L, De Toffol L, McNamara JA., Jr Mandibular changes produced by functional appliances in class II malocclusion: A systematic review. *Am J Orthod Dentofacial Orthop.* 2006;129:599.e1-12.
- Pancherz H., Ruf S., Kohlhas P. 1998. "Effective condylar growth" and chin position changes in Herbst treatment: A cephalometric roentgenographic long-term study. *Am J Orthod Dentofacial Orthop.*, 114:437-46.
- Ritto AK., Ferreira AP. 2000. Fixed functional appliances – A classification. *Func Orthod.*, 17:12-30.

\*\*\*\*\*