



ISSN: 0975-833X

Available online at <http://www.journalcra.com>

International Journal of Current Research
Vol. 11, Issue, 12, pp.8917-8919, December, 2019

DOI: <https://doi.org/10.24941/ijcr.37306.12.2019>

INTERNATIONAL JOURNAL
OF CURRENT RESEARCH

RESEARCH ARTICLE

SEVERE MACROPHAGE ACTIVATION SYNDROME IS ASSOCIATED WITH ACUTE HAV INFECTION-A VERY RARE CASE REPORT

*Dr. K.C. Das, Dr. Rajat Khandelwal, Dr. Rashmi Ranjan Pradhan and Dr. Pepse Pradhan

Department of Gastroenterology and Hepatology, Apollo Hospitals, Bhubaneswar, Odisha, India

ARTICLE INFO

Article History:

Received 24th September, 2019
Received in revised form
18th October, 2019
Accepted 05th November, 2019
Published online 31st December, 2019

Key Words:

MAS, HAV Infection,
Acute Pancreatitis,
IVIG.

Copyright © 2019, Das et al. This is an open access article distributed under the Creative Commons Attribution License, which permits unrestricted use, distribution, and reproduction in any medium, provided the original work is properly cited.

Citation: Dr. K.C. Das, Dr. Rajat Khandelwal, Dr. Rashmi Ranjan Pradhan and Dr. Pepse Pradhan. "Severe Macrophage activation syndrome is associated with acute hav infection-A very rare case report.", *International Journal of Current Research*, 11, (12), 8917-8919.

ABSTRACT

Macrophage activation syndrome (MAS) is a life-threatening complication of rheumatic disease that, for unknown reasons, occurs much more frequently in individuals with systemic juvenile idiopathic arthritis (SJIA) and in those with adult-onset Still disease. Macrophage activation syndrome is characterized by pancytopenia, liver insufficiency, coagulopathy, and neurologic symptoms and is thought to be caused by the activation and uncontrolled proliferation of T lymphocytes and well-differentiated macrophages, leading to widespread hemophagocytosis and cytokine overproduction. We treated a young man who had severe form of Macrophage activation syndrome which was associated with acute HAV infection. This kind of severe complication in acute HAV infection has not yet been reported in the literature.

INTRODUCTION

Macrophage activation syndrome (MAS) is a life-threatening complication of rheumatic diseases, requiring immediate and appropriate treatment. MAS is a disorder related to hemophagocytic lymphohistiocytosis (HLH), which may be divided into primary and secondary HLH. Primary HLH is an inherited disease, whereas secondary HLH is triggered by other diseases, including infections, malignancy, and autoimmune diseases. MAS is a secondary HLH, which is associated with autoimmune diseases (Ravelli et al., 2016; Grom, 1996). The most common autoimmune diseases associated with MAS are systemic juvenile idiopathic arthritis (SJIA), followed by systemic lupus erythematosus (SLE), Kawasaki disease (KD), and juvenile dermatomyositis (JDM) (Lin, 2012). MAS is caused by an imbalance of the immune system, leading to uninterrupted hyperstimulation of the immune cells. The symptoms of MAS are quite similar to those of many active autoimmune diseases or severe sepsis; therefore, it is quite difficult to make a diagnosis. MAS is still under-recognized, and its treatment is usually delayed, which then leads to high morbidity and mortality. The classical signs and symptoms of patients with MAS are a persistent high-

grade fever, hepatosplenomegaly, lymphadenopathy, and hemorrhagic manifestations. Abnormal results of investigation include cytopenia, coagulopathy, and hyper-ferritinemia. These distinctive features usually occur in the later stages of MAS; this leads to a delay in the diagnosis of the condition, resulting in a worse outcome. Therefore, early recognition of MAS is important and is the key to improving the morbidity and the mortality associated with this condition. Here we are going to bring into attention that MAS could be associated with documented acute HAV infection in a tertiary care hospital.

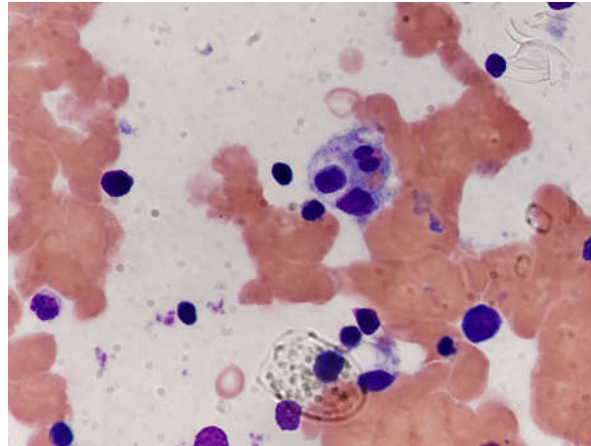
Case presentation: 23 years young male presented to us with complaints of fever for 10 days associated generalised weakness, jaundice for 4 to 5 days and altered sensorium one day prior to admission. He was previously treated elsewhere before being referred to us. He was admitted and evaluated as per protocol. On examination, he had features of Gr-III Hepatic encephalopathy having deep icterus, tachycardia and was tachypneic. He was admitted in the ICU. Initial investigations showed Hb 5.6, TLC 21.9 X 1000, platelet-236000, Total bilirubin -47.9, SGOT -461, SGPT- 726, ALP -94, GGT- 84, Albumin -2.9, ammonia -71, INR-1.55, Creat -0.98, Na -123, K -3.6. Hepatitis A virus IgM was positive. HEV IgM-negative, Scrub Typhus-negative, Lepto, MP and Dengue and Widal was negative. HBsAg and Anti-HCV were non reactive. Blood and urine culture on admission showed no growth. LDH was raised 1670.

*Corresponding author: Dr. Das, K.C.,

Department of Gastroenterology and Hepatology, Apollo Hospitals, Bhubaneswar, Odisha, India.

Table1. Laboratory investigations

DATES	HB	TLC	PC	T.BILIRUBIN	S.ALBUMIN	AST	ALT	GGTP	ALP
25.6.19	5.6	21.9	236	47.9	2.9	461	726	84	94
29.6.19	7.5	14.94	180	23.8	2.4	62	167	45	70
1.7.19	8.2	8.72	172	21.9	3.1	106	88	110	90
2.7.19	-	-	-	10.8	3.1	143	181	143	128
3.7.19	-	-	-	13.1	2.8	133	70	169	107
8.7.19	-	-	-	14.2	2.7	242	111	161	144
10.7.19	8.5	0.7	26.1	-	-	-	-	-	-
15.7.19	9.3	6.3	306	-	-	-	-	-	-
16.7.19	10.2	18.5	348	10.2	3.0	112	86	134	125



Oedematous marrow with erythroid hyperplasia, Megakaryocytes were increased in number, Macrophages were markedly increased with haemophagocytosis. Courtesy adapted from Department of Pathology, Apollo Hospital Bhubaneswar.

Figure 1. Bone marrow biopsy

He received Blood transfusion and Anti - coma regimen. He was started on broad spectrum antibiotics.. Patient continued to have fever spikes but sensorium and other parameters improved. He was shifted to ward. However he continued to have fever, tachycardia, tachypnea requiring NIV support and he had significant epigastric pain and vomiting and his serum lipase was found to be raised 1132. He was again shifted to ICU. He continued to have fever spikes and repeat CBC showed that his Leukocyte count had dropped to 700 cell per cu.mm. Serum triglycerides was mildly raised and serum ferritin was found high. Bone marrow aspiration and biopsy was planned in view of progressive pancytopenia which showed marked myeloid suppression with Haemophagocytosis, features suggestive of marked Macrophage activation syndrome. EBV IgM and Parvo B19 were negative. Rheumatology and haematology consultation were taken. Patient was isolated in view of severe neutropenia. He was started on IV methylprednisolone 500mg IV for 3 days and Granulocyte stimulating factor but no satisfactory result was achieved and subsequently he was started on IVIG and received total of 4 days. He optimally responded to IVIG where it is showed increasing trend of TLC and haemoglobin. Repeat LFT showed normalising trend. He became afebrile after 3 days of IVIG. Subsequent tapering dose of steroid and low dose of cyclosporine was continued. Features of acute pancreatitis resolved slowly after conservative management. This episode of acute pancreatitis could be due to HAV induced.

DISCUSSION

MAS is a disorder related to hemophagocytic lymphohistiocytosis (HLH), which may be divided into primary and secondary HLH.

Primary HLH is an inherited disease, whereas secondary HLH is triggered by other diseases, including infections, malignancy, and autoimmune diseases (Ravelli et al., 2016; Grom, 1996; Lin, 2012; Henter et al., 2004). MAS is caused by an imbalance of the immune system, leading to uninterrupted hyperstimulation of the immune regulatory cells. It is quite difficult to make a diagnosis. MAS is still under-recognized, and its treatment is usually delayed, which then leads to high morbidity and mortality. The classical signs and symptoms of patients with MAS in our case were not present only a persistent high-grade fever, acute pancreatitis, hepatic encephalopathy and pancytopenia. Abnormal results of investigation include cytopenia, coagulopathy, and hyperferritinemia had clue to clench the diagnosis. These distinctive features usually occur in the later stages of MAS; this leads to a delay in the diagnosis of the condition, resulting in a worse outcome. We proceeded for bone marrow biopsy (Figure-1) which established the diagnosis. He required IVIG to control the disease activity where steroid alone was unsuccessful. Therefore, early recognition of MAS is important and is the key to improving the morbidity and the mortality associated with this condition. Here we are going to bring to an attention that MAS could be associated with documented acute HAV infection which could subsequently responded to IVIG.

Summary

An early diagnosis and prompt initiation of treatment are both key factors for a positive outcome in MAS. Although the clinical presentations of both MAS and active autoimmune diseases were quite similar, there were some clues from the serial monitoring of laboratory parameters, which helped the physicians in making an early diagnosis of MAS. This patient had acute HAV infection and hepatic encephalopathy which was managed with all supportive care.

The relative changes in the laboratory parameters during the early stages of this MAS included changes haemoglobin and white blood cell counts, as well as levels of ferritin, LDH, and liver enzymes which were present in our patient. Subsequent bone marrow biopsy established his diagnosis as Macrophage activation syndrome. At present, diagnostic criteria have been proposed for MAS in the various autoimmune diseases. Selecting the proper diagnostic criteria to diagnose MAS is essential, because not all of the criteria are suitable for every autoimmune disease.

Prior Publication: This article has not been published or submitted for publication elsewhere, in whole or in part, before submission to the Case

Consent: The authors declare that they have provided written informed consent from the described patient for the case report to be published.

Conflict of Interests: The authors declare that there is no conflict of interests regarding the publication of this paper.

Acknowledgements

I would like to extend my thanks for the manuscript to be published.

Abbreviation: MAS-Macrophage activation syndrome.
IVIG-IV Immunoglobulin.
HAV-Hepatitis –A virus.

REFERENCES

- Ravelli A., Minoia F., Davi S. et al. 2016. Classification criteria for macrophage activation syndrome complicating systemic juvenile idiopathic arthritis: a European League Against Rheumatism/American College of Rheumatology/Paediatric Rheumatology International Trials Organisation Collaborat. *Arthritis Rheumatol.* 2016;68(3):566–576.
- Grom AA., Passo M. 1996. Macrophage activation syndrome in systemic juvenile rheumatoid arthritis. *J Pediatr.*, 129(5):630–632.
- Lin CI., Yu HH., Lee JH., et al., 2012. Clinical analysis of macrophage activation syndrome in pediatric patients with autoimmune diseases. *Clin Rheumatol.*, 31(8):1223–1230.
- Henter JL., Horne A., Aricó M. et al., 2007. HLH-2004: diagnostic and therapeutic guidelines for hemophagocytic lymphohistiocytosis. *Pediatr Blood Cancer.*, 48(2):124–131.
- Ravelli A., Magni-Manzoni S., Pistorio A. et al., 2005. Preliminary diagnostic guidelines for macrophage activation syndrome complicating systemic juvenile idiopathic arthritis. *J Pediatr.*, 146(5):598–604.
- Behrens EM., Beukelman T., Paessler M., Cron RQ., 2007. Occult macrophage activation syndrome in patients with systemic juvenile idiopathic arthritis. *J Rheumatol.*, 34(5):1133–1138.
- Parodi A., Davi S., Pringe AB. et al., 2009. Macrophage activation syndrome in juvenile systemic lupus erythematosus: a multinational multicenter study of thirty-eight patients. *Arthritis Rheum.* 60(11):3388–3399.
- Morales PM., Jimenez BF., Yanes P., Rios D., Godinez R. 1992. Marrow B with reactive histiocytosis (RH), hemophagocytosis and storage histiocytes (SH) in systemic lupus erythematosus. *Arthritis Rheum.*, 35(Suppl):S239.
- Wang W., Gong F., Zhu W., Fu S., Zhang Q. 2015. Macrophage activation syndrome in Kawasaki disease: more common than we thought? *Semin Arthritis Rheum.*, 44(4):405–410.
- Minoia F., Davi S., Horne A., et al., 2014. Clinical features, treatment, and outcome of macrophage activation syndrome complicating systemic juvenile idiopathic arthritis: a multinational, multicenter study of 362 patients. *Arthritis Rheumatol.* 66(11):3160–3169.
- Ravelli A., Minoia F., Davi S., et al., 2016. Expert consensus on dynamics of laboratory tests for diagnosis of macrophage activation syndrome complicating systemic juvenile idiopathic arthritis. *RMD Open.*, 2(1): e000161.
- Zeng HS., Xiong XY., Wei YD., Wang HW., Luo XP. 2008. Macrophage activation syndrome in 13 children with systemic-onset juvenile idiopathic arthritis. *World J Pediatr.*, 4(2):97–101.
- Sawhney S., Woo P., Murray KJ. 2001. Macrophage activation syndrome: a potentially fatal complication of rheumatic disorders. *Arch Dis Child.*, 85(5):421–426.
- Gavand PE., Serio I., Arnaud L. et al., 2017. Clinical spectrum and therapeutic management of systemic lupus erythematosus-associated macrophage activation syndrome: a study of 103 episodes in 89 adult patients. *Autoimmun Rev.* 16(7):743–749.
- Ahn SS., Yoo BW., Jung SM., Lee SW., Park YB., Song JJ. 2017. In-hospital mortality in febrile lupus patients based on 2016 EULAR/ACR/PRINTO classification criteria for macrophage activation syndrome. *Semin Arthritis Rheum.*, 47(2):216–221.
- Borgia RE., Gerstein M., Levy DM., Silverman ED., Hiraki LT., Features HLT. 2018. Features, treatment, and outcomes of macrophage activation syndrome in childhood-onset systemic lupus erythematosus. *Arthritis Rheumatol.*, 70(4):616–624.
- Liu AC., Yang Y., Li MT., et al. 2018. Macrophage activation syndrome in systemic lupus erythematosus: a multicenter, case-control study in China. *Clin Rheumatol.*, 37(1):93–100.
- Li X., Qu B., Nie Y., Zhu G., Li W., Mu F. 2014. Clinical features of macrophage activation syndrome in the adult northern Chinese population. *Lupus.* 23(8):785–792.
- Grom AA., Villanueva J., Lee S., Goldmuntz EA., Passo MH., Filipovich A. 2003. Natural killer cell dysfunction in patients with systemic-onset juvenile rheumatoid arthritis and macrophage activation syndrome. *J Pediatr.*, 142(3):292–296.
- Cifaldi L., Prencipe G., Caiello I. et al., 2015. Inhibition of natural killer cell cytotoxicity by interleukin-6: implications for the pathogenesis of macrophage activation syndrome. *Arthritis Rheumatol.*, 67(11):3037–3046.
- Kaufman KM., Linghu B., Szustakowski JD. et al., 2014. Whole-exome sequencing reveals overlap between macrophage activation syndrome in systemic juvenile idiopathic arthritis and familial hemophagocytic lymphohistiocytosis. *Arthritis Rheumatol.*, 66(12):3486–3495.
- Vastert SJ., van Wijk R., D'Urbano LE. et al., 2010. Mutations in the perforin gene can be linked to macrophage activation syndrome in patients with systemic onset juvenile idiopathic arthritis. *Rheumatology.*, 49(3):441–449.
- Hazen MM., Woodward AL., Hofmann I. et al., 2008. Mutations of the hemophagocytic lymphohistiocytosis-associated gene UNC13D in a patient with systemic juvenile idiopathic arthritis. *Arthritis Rheum.* 58(2):567–570.