



ISSN: 0975-833X

Available online at <http://www.ijournalcra.com>

International Journal of Current Research  
Vol. 12, Issue, 01, pp.9224-9227, January, 2020

DOI: <https://doi.org/10.24941/ijcr.37761.01.2020>

INTERNATIONAL JOURNAL  
OF CURRENT RESEARCH

## REVIEW ARTICLE

# DISREGARDED MISUSE OF IRRATIONAL CORTICOSTEROID COCKTAILS AND RECALCITRANT FUNGAL INFECTIONS

1.\* Joise P and 2Jennet P

\*1Pharm D Intern, National College of Pharmacy, Manassery, Calicut, Kerala

2Pharm D IV<sup>th</sup> year, National College of Pharmacy, Manassery, Calicut, Kerala

### ARTICLE INFO

#### Article History:

Received 04<sup>th</sup> October, 2019

Received in revised form

28<sup>th</sup> November, 2019

Accepted 19<sup>th</sup> December, 2019

Published online 30<sup>th</sup> January, 2020

#### Key Words:

Topical corticosteroids, recalcitrant fungal infections, irrational prescription, Dermatophytosis

### ABSTRACT

Indian market is flooded with several fixed-dose combinations (FDCs) of corticosteroids with one or more broad spectrum antimicrobial (antifungal and antibacterial) agents which under no circumstances can be considered as rational. In 2013, such 2 irrational steroid cocktails were the highest selling corticosteroids in the country. This haphazard use of topical corticosteroid preparations is triggering off recalcitrant infections, distorting clinical diagnoses and is indubitably a public health concern. Indian Dermatologists are witnessing an epidemic of fungal infections. The current alarming situation of emerging chronic, recurrent or recalcitrant dermatophytosis haunts the country. Fungal infections that were easily manageable are now resistant – with even the most potent antifungal creams failing to treat them. A big concern surrounding topical steroid cocktails i.e. fixed dose combination of a steroid and one or more antimicrobial agent(s), is the reduction of local cellular immunity that is vital to curb dermatophytes. This paves the way to recalcitrant mycosis and other atypical presentations. The daunting dearth of comparative clinic-epidemiological data necessitates dire need for well-designed large-scale studies to combat this dermatophytosis epidemic in India.

Copyright © 2020, Joise and Jennet. This is an open access article distributed under the Creative Commons Attribution License, which permits unrestricted use, distribution, and reproduction in any medium, provided the original work is properly cited.

Citation: Joise P and Jennet P. 2020. "Disregarded misuse of irrational corticosteroid cocktails and recalcitrant fungal infections", *International Journal of Current Research*, 12, (01), 9224-9227.

## INTRODUCTION

**Dermatophytosis:** Dermatophytosis is a group of superficial infections instigated by a specialized aerobic fungal group (*ring worm fungi/dermatophyte*). They are common in developing countries like India with a prevalence of 36.6 – 78.4% (Khurana, 2019). The main aetiological agents of dermatophytosis in humans are the species of Epidermophyton (*E.floccosum*), Microsporum (*M. canis*) and Trichophyton (*T. tonsurans*, *T. rubrum*, *T. mentagrophytes*, *T. interdigitale*) (Alemayehu, 2016). These dermatophytes invade and infect the keratinized layers of hair, skin, and nails. A 6 year study in North India reported the leading etiological cause of dermatophytosis to be *Trichophyton mentagrophytes* (62.28%) followed by *T. rubrum* (23.4%) (Verma, 2019).

**Mechanism of Dermatophytic Infection:** The pathological mechanisms for recalcitrant and recurrent dermatophytic infections are less understood (Figure 1). The severity of the disease could be secondary to host, etiological and other factors related to the habitat or pharmacology.

Dermatophytosis is predominant in tropical and sub-tropical countries like India due to the favorable conditions for acquisition, invasion, and maintenance and progression of the disease. Host specific nature of the pathogen is due to the difference in keratin composition of the host and this determines the chronicity/severity of the cutaneous manifestations.

**Steroid modified tinea and hypothetic mechanism of recalcitrance:** Long term misuse of Topical Corticosteroids (TCS) – of both high and low potency – have an enormous potential to cause steroid dependence. Repeated application of cocktail creams inhibits the release of vasodilator nitric oxide, resulting in chronic vasoconstriction. The added immunosuppressive effect of corticosteroids causes the overgrowth of secondary organisms, the super antigens. Sub-therapeutic dose, and incomplete dosage may lead to antigen mediated cutaneous reaction, manifesting as inflammatory papules and pustules, altering the typical appearance of tinea. Lesions attain widespread, bizarre shapes losing the active erythematous boundaries and mimic cutaneous diseases (Verma, 2017; Panda, 2017; Verma, 2017). Activation of T-helper (Th-1 and Th-17) dependent cell mediated immunity (CMI) destroys dermatophytes in both acute and chronic cases (Verma, 2017). Chronic dermatophytosis often present with

\*Corresponding author: Joise, P.,

Pharm D Intern, National college of Pharmacy, Manassery, Calicut, Kerala.

higher levels of IgE, IgG due to Th-2 dependent CMI. Acute dermatophytosis is most commonly associated with Th-1 cytokine response (Verma, 2017).

**Fungal superbug reign and Antifungal therapeutic failure [AFTF]:** Even experienced Indian dermatologists are in dire straits from the alarming spectre of dermatophytosis, changing their current perception of management as the clinical presentations often vary (Panda, 2017). Unattended issue of therapeutic failure due to emergence of antifungal resistance over the past decade needs to be addressed. Research studies globally, now notices the rising rates of resistant cases to common anti-fungal therapy of dermatophytic infections causing substantial rise in AFTF (Aggarwal, 2019). The resistance to the treatment can either be clinical or microbiological or a variegate of the two (Panda, 2017; Aggarwal, 2019). Microbiological resistance refers to in-vitro susceptibility testing, in which the MICs of the organism exceed the susceptibility breakpoint for the organism which can be either primary or secondary (Pai, 2017; Shivanna, 2017).

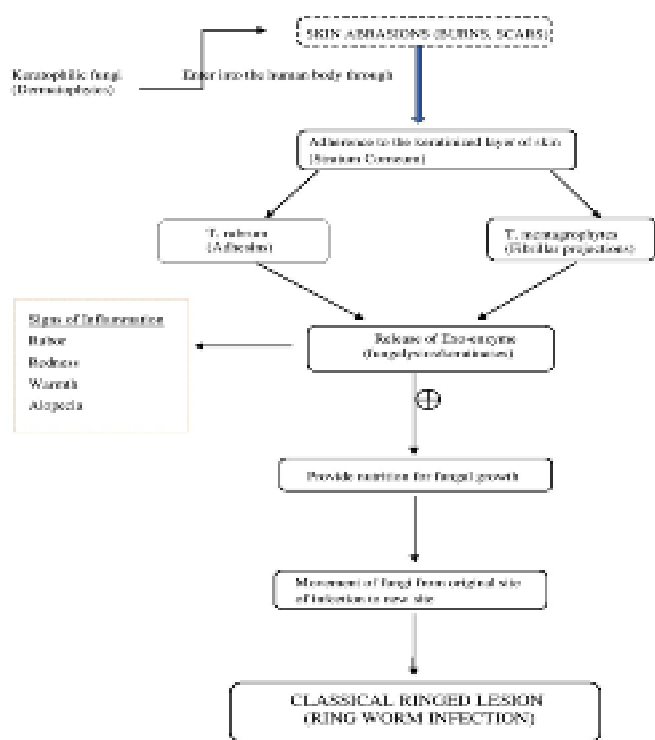
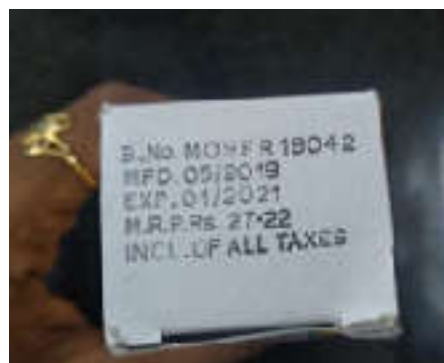
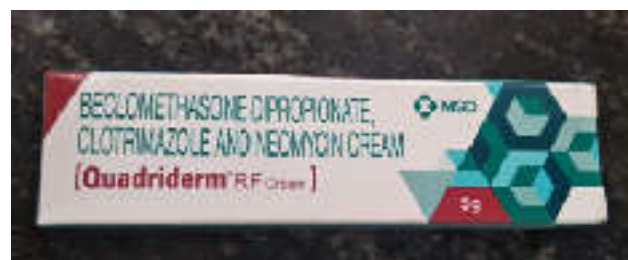
Fig. 1. Proposed Mechanism for various dermatophytic infections (Dogra, 2016; Tainwala, 2011)

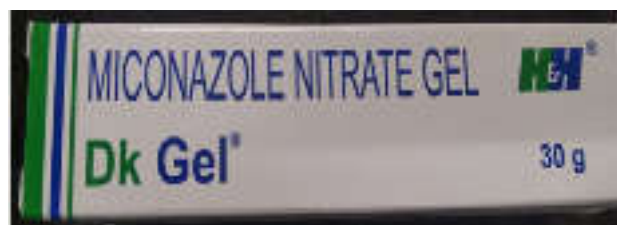Certain fungi present with a natural resistance without prior exposure, termed as primary resistance while the previously exposed fungal strains develop secondary resistance (Loeffler, 2003). Several instances of clinical resistance have been noted while the demonstration of microbiological proven resistance is parsimoniously deficient. Clinical resistance is defined as treatment failure despite indicated therapy that make the disease to progress and persist that necessitates the need for invasive therapy. The pathogen fails to get eradicated despite the result from imprecise diagnosis, and immune-compromised conditions (Panda, 2017; Shivanna, 2017; Loeffler, 2003). Successful clinical response relies on the factors like host immunity, drug absorption and distribution following its administration and medication adherence.

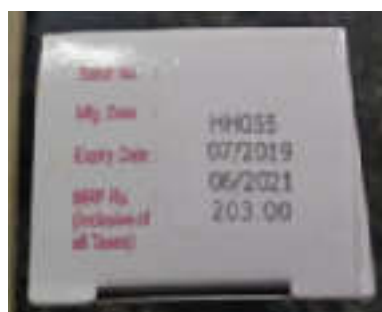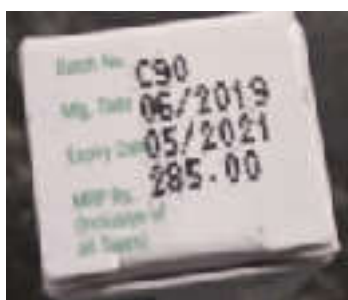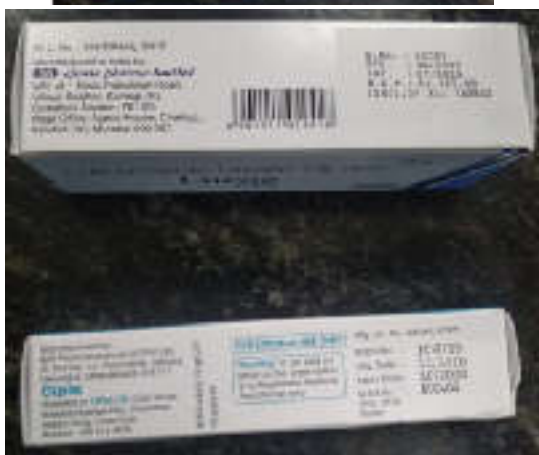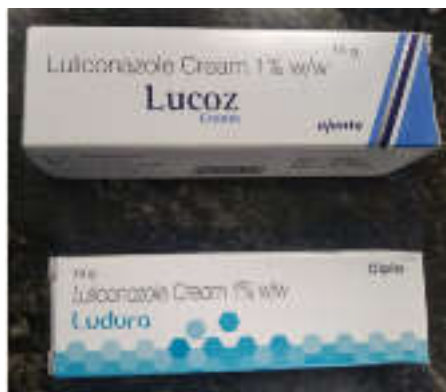**Recurrent dermatophytosis in clinico-epidemiological literature:** According to a study by Dongra et al. to evaluate the clinical pattern of the chronic, recurrent cutaneous mycosis,



Costlier single agent anti-fungal agents

LULICONAZOLE





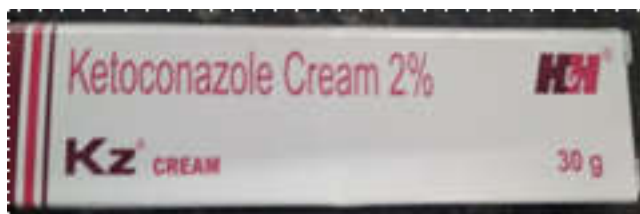
over half of the study patients had been topical steroid cocktails misusers (Panderm, Quadri-derm, Candid B) that led to atypical presentations of papulo-squamous, eczematous, pustular, pseudo imbricate (reminiscent of tinea imbricate characterized by concentric rings), lichenoid, pityriasis rosea like and bullous lesions. Another Indian study by Nibedita Patio et al., reported a prevalence of about 5-10% for new cases of dermatophytosis with atypical presentations. Another study involving 85 dermatophytosis patients treated with TCS FDCs found that 90% of the patients were resistant to terbinafine, a key anti-fungal agent for long term treatment of superficial fungal infections. This highlights an adverse role of steroid-cocktails comparing to single agents in the development of resistant and recalcitrant dermatomycosis.

**Predisposing factors to recalcitrant infections**

**Over-the-counter (OTC) availability of TCS FDCs:** Apart from the factors that rely on the development of recurrent, recalcitrant superficial mycosis, unchecked OTC availability of inexpensive TCS FDCs is another cause of concern as they are rampantly being misused all over the country as fairness creams. Superficial fungal infection management strategies by dermatologists, general physician and alternative medicine practitioners even self-medicated by the population as a blanket treatment option for various kinds of cutaneous infections (Bishnoi, 2018). The available brands of irrational steroid cocktails are Panderm (Clobetasol propionate (0.05%w/w) + Miconazole (2%w/w) + Neomycin (0.5% w/w) Quadri-derm (Beclomethasonevalerate (0.61%w/w), Clioquinol (10 mg), Gentamicin (1 mg), Tolnafate (10 mg). Quadri-derm RF (Beclomethasone (0.025%w/w), Clotrimazole (1%w/w), Neomycin (0.5%w/w) (Figure 1)

**Surging sales and the need of regulations:** These FDC of corticosteroids and antimicrobials sums for 85% of the pharmaceutical market (INR 13.22 billion in 2014-15) (Verma, 2015). The deals have risen 26% in 2014-15 contrasting with earlier year, when the market was worth Rs 10.5 billion (Verma, 2015). In 2018, India devoured Rs 1,400 crore worth of topical steroid creams a fragment which recorded an annual growth of 16% and surprisingly these figures don't factor in OTC clearance of these topical creams (Roli Srivastava, 2016; Kumar, 2016). TCS has progressed toward becoming ubiquitous with dermatologists and concerns have additionally been raised with regard to its abuse for non-labeled indication. Currently, the number of available FDCs of these corticosteroids with antibiotics is 119. CDSCO's approved list of FDCs from 1961 to 2014 features only 27 out of those available 119 formulations in India. Surprisingly, none of the best-selling dermatology FDCs is included in the regulator's approved list (Kumar, 2016). Non-inclusion on this list means that these irrational FDCs are manufactured and marketed without authorization. These irrational broad-spectrum steroid

**Ketoconazole**



cocktails allow the misuse of the topical formulations as the physicians are forced to prescribe them when they are unsure about the diagnosis (Kumar, 2016; <https://www.sciencedaily.com/releases/2015/11/151125233022.html>).

**Non-adherence and economic burden:** The cheaper steroid FDC creams which might act as a quick relief, give rise to notorious and clinically unresponsive recalcitrant dermatophytosis. Newer single agent antifungal creams that are introduced to the market, are often unaffordable. Adherence to the treatment has a direct link to affordability. Non-adherence from unaffordability of costlier creams could be a reason for the rampant misuse of the cheaper cocktails (<https://qz.com/india/578793/indias-middle-class-is-almost-impossible-to-define/>). 38 % of the Indian population is comprised by middle class people according to the Asian Development Bank estimate who are relentlessly in risk of slipping back to poverty due to economic crisis (Verma, 2019; <https://qz.com/india/578793/indias-middle-class-is-almost-impossible-to-define/>). A significant financial burden arises from out-of-pocket expenditure due to ping pong effect, when the family and contacts are affected.<sup>19</sup>

**Taskforce:** An online petition started by Indian Association of Dermatologists, Venereologists and Leprologists– Taskforce Against Topical Steroid Abuse (ITATSA) – about OTC availability of TCs is a welcome step in this direction.<sup>20</sup> ITATSA is a special task force to look into issues related to TC abuse (Bureau, 2019; Verma, 2018). It has raised the issue of TC misuse at various fronts including physicians, manufacturers, pharmaceutical companies and regulators. One such effort is this online petition, which is being given to the Ministry of Health and Family Welfare, Government of India and CDSCO, that stresses upon issues related to the indiscriminate sale of TCs without prescription in India. Avenues that require further research include specific host immunodeficiency (CARD 9 mutations), virulence factors of dermatophytes (biofilms), novel treatments, and possible vaccination. There is an impending need for antifungal stewardship in dermatology. Public health campaigns can be conducted to train the peripheral health workers to diagnosed and rationally treat the cutaneous mycosis.

## REFERENCES

Aggarwal P., Agrawal M., Sonthalia S. 2019. South Asian Epidemic of Antifungal Therapeutic Failures: Congress Proceedings and Take-home Messages. First International Congress of SAARCUM: South Asian Alliance against Recalcitrant Cutaneous Mycosis. 17 November 2018, Medanta - The Medicity, Gurugram, India. *Indian Dermatol Online J.*, 10(2):214–224.

Alemayehu A., Minwuyelet G. and Andualem G. 2016. Prevalence and Etiologic Agents of Dermatophytosis among Primary School Children in Harari Regional State, Ethiopia. *J. Mycol.*, 7:1-5

Bishnoi A., Vinay K., Dogra S. 2018. Emergence of recalcitrant dermatophytosis in India. *Lancet Infect Dis.*, 250 -251.

Bureau O. 2019. Dermatologists decry use of powerful steroids [Internet]. @businessline. The Hindu Business Line; 2019 [cited]. Available from: <https://www.thehindubusinessline.com/news/dermatologists-decry-use-of-powerful-steroids/article25934076.ece>

Dogra S., Uprety S. 2016. The menace of chronic and recurrent dermatophytosis in India: Is the problem deeper than we perceive?. *Indian Dermatol Online J.*, 7:73-6

Economy RU 2019. for P. India's middle class is almost impossible to define [Internet]. Quartz India. Quartz; 2015 [cited]. Available from: <https://qz.com/india/578793/indias-middle-class-is-almost-impossible-to-define/>

Harmful use of topical steroids in India is out of control, says expert [Internet]. Science Daily. Science Daily; 2015 [cited 2019Dec11]. Available from: <https://www.sciencedaily.com/releases/2015/11/151125233022.htm>

Khurana A., Sardana K., Chowdhary A. 2019. Antifungal resistance in dermatophytes: recent trends and therapeutic implications. *Fungal Genet Biol.*, 132:103255

Kumar S., Goyal A., Gupta YK. 2016. Abuse of topical corticosteroids in India: Concerns and the way forward. *J Pharmacol Pharmacother.* 7:1-5.

Loeffler J., Stevens D. A. 2003. Antifungal Drug Resistance. *Clin Infect Dis.*, 36(15):31–41

Pai V., Ganavalli A., Kikkeri NN. 2018. Antifungal resistance in dermatology. *Indian J Dermatol.*, 63:361-8

Panda S., Verma S. 2017. The menace of dermatophytosis in India: The evidence that we need. *Indian J Dermatol Venereol Leprol.*, 83:281-4.

Roli Srivastava. 2016. An era of untreatable infections. The Hindu. Retrieved from <https://www.thehindu.com/opinion/op-ed/An-era-of-untreatable-skin-infections/article14621962.ece>

Shivanna R., Inamadar AC. 2017. Clinical failure of antifungal therapy of dermatophytoses: Recurrence, resistance, and remedy. *Indian J Drugs Dermatol.*, 3:1-3

Tainwala R., Sharma Y. 2011. Pathogenesis of Dermatophytoses. *Indian J Dermatol.*, 56:259–61

Verma S B., Zouboulis C. 2018. Indian irrational skin creams and steroid-modified dermatophytosis - an unholy nexus and alarming situation. *J Eur Acad Dermatol Venereol.*, 2(11):e426-e427

Verma S. 2017. Steroid modified tinea. *BMJ.*, 357:j2752.

Verma S., Madhu R. 2017. The great Indian epidemic of superficial dermatophytosis: An appraisal. *Indian J Dermatol.*, 62:227–36

Verma S., Verma G., Sharma S. 2019. Current Spectrum of Dermatophytosis in a Tertiary Care Hospital of North India-A 6-Year Clinico-Mycological Study. *JMSCR.*, 5(3):19488-19494

Verma SB. 2015. Topical steroid misuse in India is harmful and out of control. *BMJ.* 351:h6079

Verma SB. 2019. Complex cost issues in treating dermatophytoses in India—”It all builds up”. *Indian Dermatol Online J.*, 10:441-3

\*\*\*\*\*