



ISSN: 0975-833X

Available online at <http://www.journalcra.com>

International Journal of Current Research
Vol. 12, Issue, 02, pp.10407-10408, February, 2020

DOI: <https://doi.org/10.24941/ijcr.36809.01.2020>

INTERNATIONAL JOURNAL
OF CURRENT RESEARCH

RESEARCH ARTICLE

PROSTATE CANCER AS RECTAL MASS A RARE FINDING: A CASE REPORT

*Kunal Singh

India

ARTICLE INFO

Article History:

Received 14th November, 2019

Received in revised form

20th December, 2019

Accepted 29th January, 2020

Published online 28th February, 2020

Key Words:

Rectal Mass.

ABSTRACT

Prostate cancer invasion to the rectum mucosa as T4a disease is common scenario, but as rectal mass quite uncommon. Findings in the patient reported here emphasize the importance of the relationship between urinary and gastrointestinal symptoms in detecting prostatic neoplasms in older male patients.

Copyright © 2020, Kunal Singh. This is an open access article distributed under the Creative Commons Attribution License, which permits unrestricted use, distribution, and reproduction in any medium, provided the original work is properly cited.

Citation: Kunal Singh, 2020. "Prostate cancer as rectal mass a rare finding: A case report", *International Journal of Current Research*, 12, (02), 10407-10408

INTRODUCTION

Prostate cancer has the potential to advance locoregionally to adjacent organs. This spread can take place via different routes, including direct invasion and through lymphatic channels. It is very rare for prostate cancer to invade rectum to extent as rectal mass. We describe here a patient presenting with prostate cancer presenting as rectum mass.

CASE REPORT

A 78-year-old man was referred to our hospital for constipation and voiding difficulty with history of occasional hematuria as well as bleeding per rectum. He also experienced severe weight loss (30 kg in 3 months) and bleeding from the rectum, together with vague abdominal pain and vomiting. Over the previous year, he had voiding difficulty. He was thoroughly examined, digital rectal examination suggested rectal growth predominantly through posterior surface. The colonoscopy showed a hard ulceroinfiltrative lesion seen upto 6 cm from anal verge, however examination could not be completed due to poor bowel [Figure]

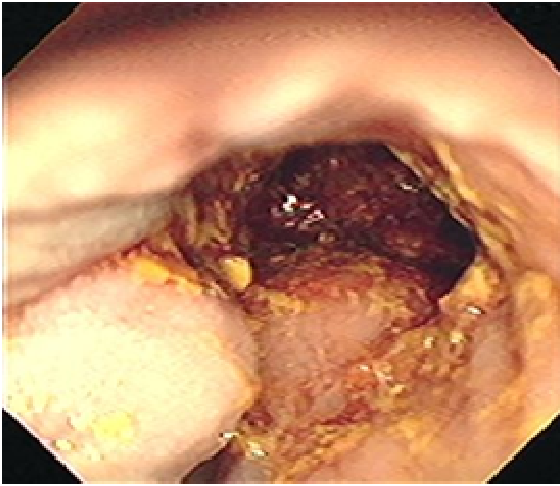
Ultrasonography abdomen suggested heterogeneous echotexture of prostate with irregular outline of prostate (Volume 65 cc) and residual urine about 650 ml, liver had

Multiloculated heterogeneous lesion in bilateral lobes. Per urethral catheterisation tried failed, finally suprapubic cystostomy done. CEA (6.9ng/ml), CA 19 -9(238 U/ml), AFP (1.69ng/ml) S. PSA T (1012ng/ml), LFT markedly dearranged (Alkaline phosphatase = 736 U/L), KFT markedly dearranged. Digitally guided core biopsy done, histopathologic examination of the biopsy showed that it was prostatic adenocarcinoma, Gleason score (4+5). TC-99 MDP bone scintigraphy showed widespread bone metastatic lesions. He was advised for castration, opted for surgical castration (bilateral orchiectomy) and referred to medical oncology department for further management.

DISCUSSION

Prostate cancer is a slowly growing neoplasm, often missed during its early stages. Patients not previously diagnosed with prostatic adenocarcinoma may present initially with metastases [Hematpour et al., 2006]. In contrast, PSA may not be expressed in all patients with prostatic adenocarcinoma [Gallee, 1998]. Prostate cancer extension to colorectal tissue can occur through at least 3 potential routes. The first is direct invasion through Denonvilliers fascia and infiltration into the rectum. The second is through lymphatics, since the prostate and rectum share some lymphatic drainage to groups of pelvic lymph node [Murray, 2004]. Third, prostate cancer cells can spread through needle biopsy, by seeding into peri-rectal or rectal tissue along the needle biopsy; this, route, however, is extremely rare [Vaghefi, 2005; Lane, 2008]. Prostate cancer metastasis to the recto-sigmoid region can occur by subserosal metastatic implant of the malignant tissues [Gengler, 1975].

*Corresponding author: Kunal Singh,
India.



The incidence of rectal infiltration by prostatic adenocarcinoma is extremely rare, being encountered on average once every two years by a busy colorectal practice [Bowrey, 2003].

Conclusion

Patient's findings reported to highlight the importance of the relationship between urinary and gastrointestinal symptoms in detecting prostatic neoplasms in older male patients. Rectal mass due to prostatic carcinoma is a rare terminal manifestation.

REFERENCES

- Bowrey DJ., Otter MI., Billings PJ. 2003. Rectal infiltration by prostatic adenocarcinoma: report on six patients and review of the literature. *Ann R Coll Surg Engl.*, 85:382-385. doi:10.1186/1477-7819-9-56
- Gallee MP, Visser-de Jong E, van der Korput JA, van der Kwast TH, tenKate FJ, Schroeder FH, Trapman J. 1990. Variation of prostate-specific antigen expression in different tumour growth patterns present in prostatectomy specimens. *Urol Res.*, 18(3):181-187.
- Gengler L., Baer J., Finby N. 1975. Rectal and sigmoid involvement secondary to carcinoma of the prostate. *Am J Roentgenol Radium Ther Nucl Med.*, 125(4):910-917.
- Hematpour K., Bennett CJ., Rogers D., Head CS. 2006. Supraclavicular lymph node: incidence of unsuspected metastatic prostate cancer. *Eur Arch Otorhinolaryngol* 263(9):872-874.
- Lane Z., Epstein JI., Ayub S., Netto GJ. 2008. Prostatic adenocarcinoma in colorectal biopsy: clinical and pathologic features. *Hum Pathol.*, 39(4):543-549.
- Murray SK., Breau RH., Guha AK., Gupta R. 2004. Spread of prostate carcinoma to the perirectal lymph node basin: analysis of 112 rectal resections over a 10-year span for primary rectal adenocarcinoma. *Am J Surg Pathol.*, 28(9):1154-1162.
- Vaghefi H., Magi-Galluzzi C., Klein EA. 2005. Local recurrence of prostate cancer in rectal submucosa after transrectal needle biopsy and radical prostatectomy. *Urology*, 66:881.
