



ISSN: 0975-833X

Available online at <http://www.ijournalcra.com>

International Journal of Current Research
Vol. 12, Issue, 02, pp.10421-10424, February, 2020

DOI: <https://doi.org/10.24941/ijcr.38086.02.2020>

INTERNATIONAL JOURNAL
OF CURRENT RESEARCH

RESEARCH ARTICLE

ISOLATED MYOCYSTICERCOSIS OF LEFT MASTICATOR SPACE: A CASE REPORT

¹Dr. Sathe Nilam Uttam ²Dr. Gupta Vani Krishana ³Dr. Srinivas Anup and
⁴Dr. Chiplunkar Dhanashree

¹Associate Professor, ENT Dept, Seth G.S Medical College, Mumbai, Maharashtra, India

²Senior Resident, ENT Dept, Seth G.S Medical College, Mumbai, Maharashtra, India

³Resident, ENT Dept, Seth G.S Medical College, Mumbai, Maharashtra, India

⁴Assistant Professor, ENT Dept, Seth G.S Medical College, Mumbai, Maharashtra, India

ARTICLE INFO

Article History:

Received 24th November, 2019

Received in revised form

10th December, 2019

Accepted 09th January, 2020

Published online 28th February, 2020

Key Words:

Taenia Solium, Masseter,
Myocysticercosis.

Copyright © 2020, Sathe Nilam Uttam et al. This is an open access article distributed under the Creative Commons Attribution License, which permits unrestricted use, distribution, and reproduction in any medium, provided the original work is properly cited.

Citation: Dr Sathe Nilam Uttam, Dr Gupta Vani Krishana, Dr Srinivas Anup and Dr. Chiplunkar Dhanashree. 2020. "Isolated myocysticercosis of left masticator space: a case Report", International Journal of Current Research, 12, (02), 10421-10424.

ABSTRACT

Cysticercosis is infestation by the larval form of pork tapeworm, Taenia Solium. Humans acquire it by ingestion of contaminated water or uncooked pork. These larvae penetrate the gastric mucosa and are absorbed into the blood vessels or lymphatics and are distributed in the body. The most commonly affected system is the central nervous system leading to neurocysticercosis. Very rarely it can be deposited in muscles and cause symptoms. We present a rare case of cysticerci in the masseter, temporalis & pterygoid muscles of the left side leading to isolated myocysticercosis.

INTRODUCTION

Taenia Solium also known as the pork tapeworm is found in two forms- adult and larval form. Intestinal infection by adult tapeworms that follows ingestion of contaminated pork is called taeniasis. Cysticercosis is infection in secondary hosts by the larval form which develops after ingestion of ova excreted in human feces (García, 2003). These larval forms of the helminth penetrate the gastric mucosa, are absorbed into the blood vessels and lymphatics and can infest any tissue of the body. The commonly involved systems are central nervous system, subcutaneous tissues, orbit and skeletal muscles (Report, 2018). It remains a major public health issue as ingestion of eggs by contaminated food and water is common in developing countries (Pang, 2004).

Case Report: A 24 year old male presented with complains of swelling and pain in left cheek with prominence of zygomatic of same side since 4 months. It was insidious in onset and gradually increased to current size. He gave history of trauma to right eye one year ago when a metal splinter entered his eye following which he had a complete loss of vision. He underwent evisceration of eyeball and placement of prosthesis in the socket following orbital trauma.

*Corresponding author: Dr. Sathe Nilam Uttam,

Associate Professor, ENT Dept, Seth G.S Medical College, Mumbai, Maharashtra, India.

He had no complaints of fever, nasal symptoms, tooth pain or any visual complaint of left eye. He had no other systemic diseases. He consumed a mixed diet including chicken and mutton, but had never consumed pork. On examination, both sides' zygomatic arches were prominent (Figure 1). There was no obvious swelling on the left side. Moreover, there was mild tenderness at the root of zygoma on the left side. The prosthetic eye on right side was noted. The examination of ear, nose and oral cavity was normal. Mouth opening was normal and not painful. On investigations, all routine blood workup were normal. Computed Tomography of face was done and showed multiple (at least 9) well defined peripherally calcified lesions seen in muscles of left masticator space. Few of these lesions showed calcified scolex within. Surrounding muscles and subcutaneous tissues were mildly bulky and edematous (Figure 2,3, and 4). Phthisis bulbi of right eye with hyperdense prosthesis was seen anteriorly. These features suggested of multiple myocysticercosis in the left masticator space: An ultrasound was done to look for evidence of any alive cysts. It also revealed presence of calcified scolex in masticator space (Figure 5). CT scan of brain was done to look for evidence of presence of any cysts in the brain and was found to be normal. X rays of long skeletal muscles didn't reveal any cysts. Ophthalmological examination and orbital CT scans didn't reveal presence of any cysts. Physician's opinion was taken for the same. As the scolex were all calcified, there was no role of anthelmintic treatment.

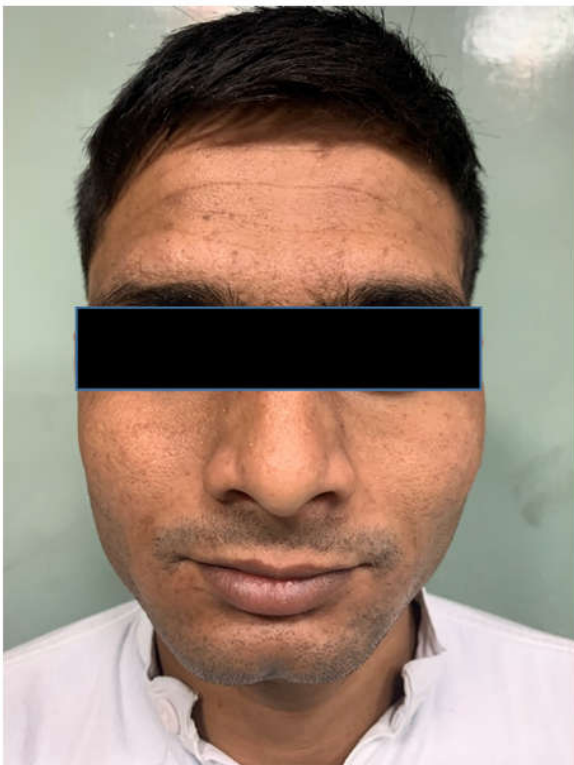
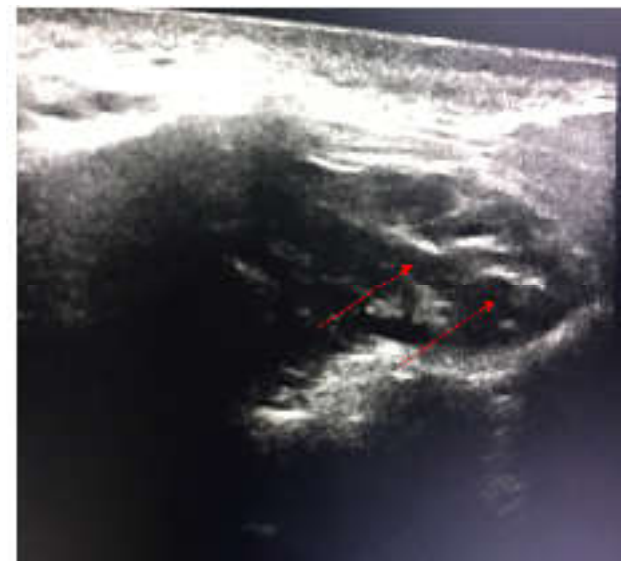
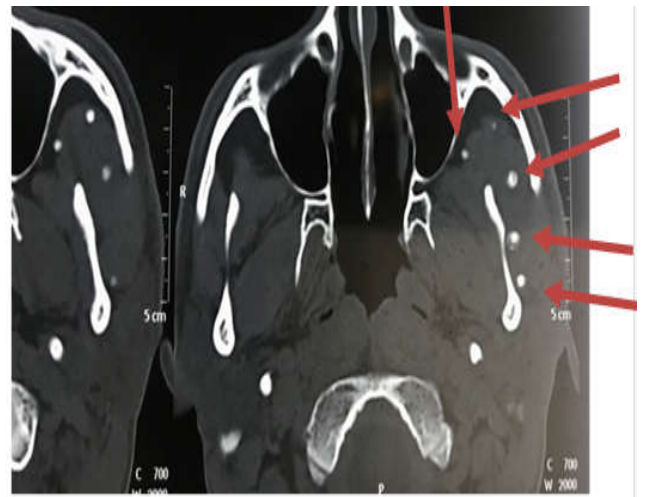Figure 1. Clinical image of patient



Figures 2,3,4. Axial cuts of CT scan showing calcified scolex within cysts in muscles of mastication of the left side.

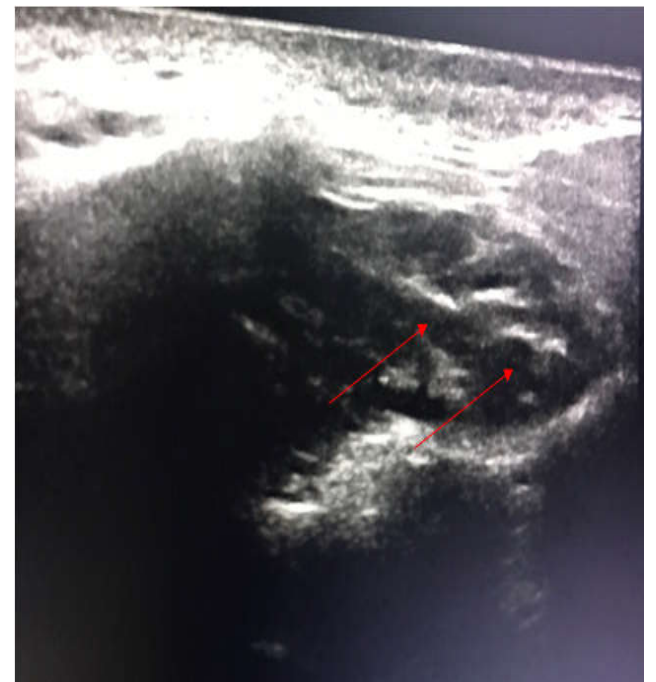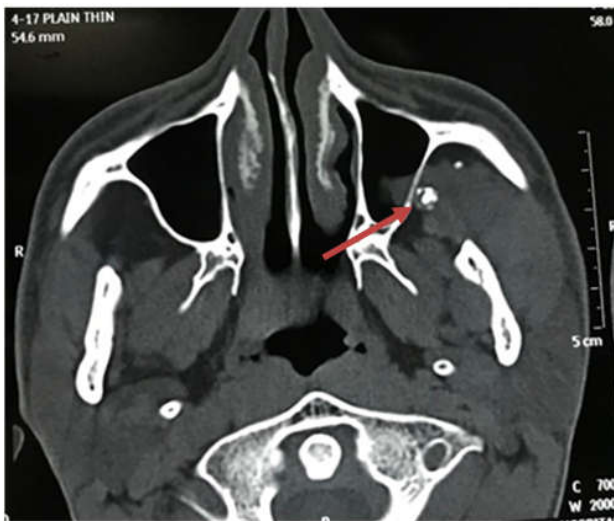


Figure 5. Ultrasonography showing calcified scolex in masseter muscle

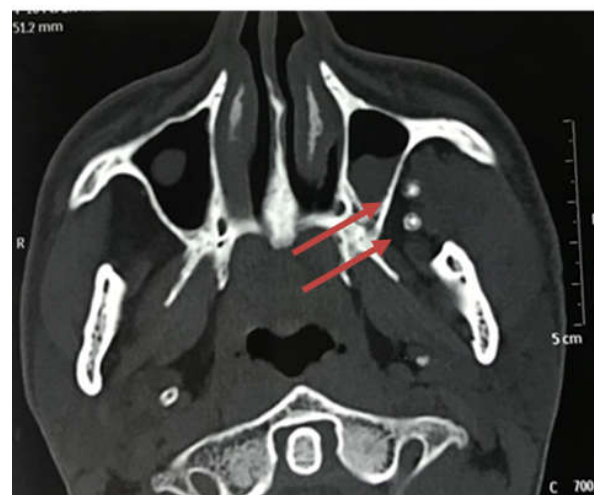

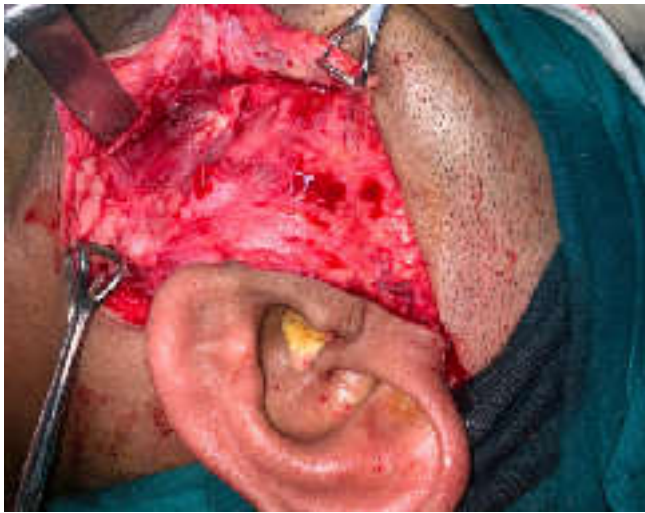


Figure 6. Intraoperative picture showing raised subcutaneous flaps on the left side.

Oral steroids and anti-inflammatory were given for symptomatic relief. Patient followed up after 4 months with persistent symptoms of left cheek pain. Repeat imaging showed similar cysts as 4 months ago. Based on the symptoms, it was decided to post the patient for excision of the cysts under general anesthesia. Incision was taken in pre auricular region and subcutaneous flap was raised (Figure 6). The masseter muscle was explored for cysts under microscope but location of cysts couldn't be made. Post-operative, the patient was fine.

Patient was followed up every weekly for two months postoperatively. Figure 6: Intra operative picture demonstrating raised subcutaneous flap on left side.

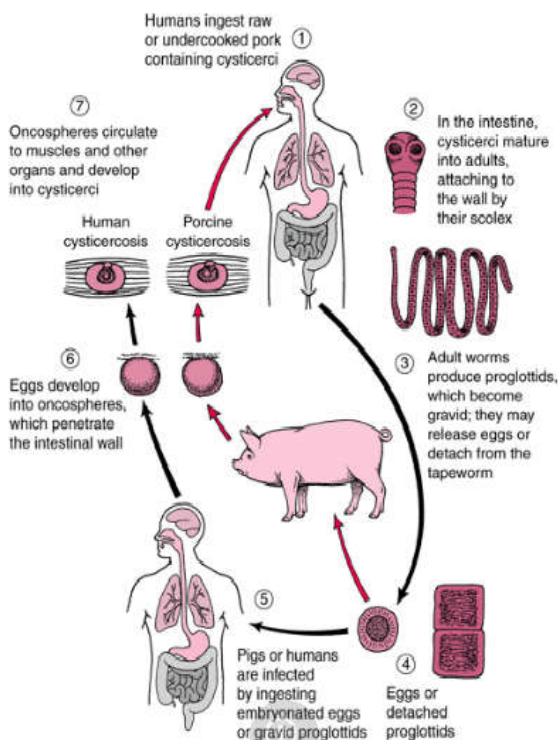


Figure 7. Life cycle of *Taenia Solium* From Merck manual.

DISCUSSION

Cysticercosis of soft tissue is caused by the encysted larvae of *Taenia Solium* which is endemic in developing countries in

Central and South America, Asia and Africa (Sharma, 2011). In the life cycle of tapeworm, human is the definitive host while pig is the intermediate host. Humans are infected due to ingestion of contaminated food, water and undercooked meat of pig containing larvae. After ingestion, these cysts evaginate and their scolex attach to small intestine and mature into adult worms. These produce proglottids which detach from the tapeworm and migrate to the anus and are excreted in feces. These are usually ingested by the pigs but occasionally, auto infection may occur. After eggs are ingested, they penetrate the gastric mucosa and travel through the blood stream to various parts of the body leading to cysticercosis (Figure 7) (Report, 2018). The eggs can contaminate any food sources, hence people who do not eat pork, including vegetarians, can also develop cysticercosis (Ilyas, 2018).

Head and neck is an uncommon area for cysticercosis with the exception of brain and orbit. Rarely cases of isolated involvement of tongue, masseter, lip, sternocleidomastoid and soft palate have been reported (Report, 2018; Sharma, 2011; Ilyas, 2018; Yogal, 2017). Involvement of skeletal muscles is usually asymptomatic. In case of trauma to the cyst, it can cause myositis leading to release of antigens. These antigens initiate an immune reaction and patient may present with fever and pain. Most of the cysts usually remain viable for 5-10 years before they start degenerating, creating a host response of fibrosis and necrosis of the capsule with caseation or calcification of the larvae (Ilyas, 2018). Myocysticercosis of three types have been described namely, myalgic type, myopathic and mass or pseudotumor type.

In myalgia type, the patient complains of muscle pain caused by acute inflammation caused by the dead larva and leakage of cyst fluid. In myopathic type, there is calcification of scolex, thickening of capsule wall and retraction of the cyst. In pseudotumor type, the mass develops due to chronic inflammation and fluid collection around the cyst (Mittal, 2008). Our patient falls in the myopathic type of myocysticercosis. Diagnosis can be done by magnetic resonance imaging, computed tomography and ultrasonography. Plain X ray can show cysticerciae in chronic cases with degeneration and calcification. High resolution ultrasonography reveals pathognomonic well defined anechoic or hypoechoic lesion with or without calcification, with a hyperechoic area within which is the scolex. CT and MRI show the exact number, location and relation of cysts to surrounding structures (Vijayaraghavan, 2004). A combination of radiological imaging helps in determining whether the cysts are alive or calcified (Sekhar, 1999). The treatment of both varies. In our case, the cysts contained calcified scolex, hence were majorly dead. Screening of brain, abdomen, orbit and skeletal muscles must be done to look for other areas of involvement. The treatment of soft tissue cysticercosis depends on its location. Isolated muscular or subcutaneous cysticercosis require no specific treatment unless they are painful. This requires excision along with antihelminthic medications like albendazole (15 mg/kg/day in divided doses for 2-4 weeks) or praziquantel (50-100 mg/kg/day in divided doses thrice daily for 2 weeks) (Sidhu, 2002).

Conclusion

Myocysticercosis is uncommon in isolated muscles of masticator space but should be considered as a rare possibility in chronic symptoms in developing countries like India. Adequate radiological investigations must be done to diagnose

the same. Preventive measures like eating cooked meat, good sanitation, drinking clean and boiled water must be practiced. An early diagnosis and treatment of cysticercosis is always beneficial.

REFERENCES

- García HH, Gonzalez AE, Evans CAW, Gilman RH. 2003. Cysticercosis Working Group in Peru. *Taenia solium* cysticercosis. *Lancet (London, England)*. 362(9383):547-556. doi:10.1016/S0140-6736(03)14117-7
- Horton J. 1996. Biology of tapeworm disease. *Lancet*. 348(9025):481. doi:10.1016/S0140-6736(05)64584-9
- Ilyas M., Bhat A. 2018. Myocysticercosis: an unusual presentation in sternocleidomastoid muscle diagnosed by high frequency ultrasonography. *Eur Res J.*, 5(1):174-177. doi:10.18621/eurj.384825
- Mittal A., Das D., Iyer N., Nagaraj J., Gupta M. 2008. Masseter cysticercosis - a rare case diagnosed on ultrasound. *Dentomaxillofac Radiol.*, 37(2):113-116. doi:10.1259/dmf/31885135
- Pang H. 2004. *Taenia solium* Transmission in a Rural Community in Honduras: An Examination of Risk Factors and Knowledge by Haiyan Pang.
- Report C. 2018. Case Report Solitary myocysticercosis of masseter muscle: A rare presentation. 2018-2020. doi:10.4103/njms.NJMS
- Sekhar GC., Honavar SG. 1999. Myocysticercosis: experience with imaging and therapy. *Ophthalmology*. 106(12):2336-2340. doi:10.1016/S0161-6420(99)90537-7
- Sharma R., Gautam P., Kumar S., Elhence P., Bansal R., Gupta G. 2011. Isolated cysticercosis cellulosa of sternocleidomastoid muscle: A case report with review of literature. *Indian J Otolaryngol Head Neck Surg*. 63(July):S127-S130. doi:10.1007/s12070-011-0140-y
- Sidhu R., Nada R., Palta A., Mohan H., Suri S. 2002. Maxillofacial cysticercosis: uncommon appearance of a common disease. *J Ultrasound Med.*, 21(2):199-202. doi:10.7863/jum.2002.21.2.199
- Vijayaraghavan SB. 2004. Sonographic appearances in cysticercosis. *J Ultrasound Med*. 2004;23(3):423-427. doi:10.7863/jum..23.3.423
- Yogal R., Singh CA., Sakthivel P., Nath A., Rajeshwari M. 2019. Isolated Myocysticercosis of neck-A rarity with review Otorhinolaryngology Isolated Myocysticercosis of neck – A rarity with review. 2017;(September):10-13. doi:10.21276/sajb.2017.5.12.4
