



ISSN: 0975-833X

Available online at <http://www.journalcra.com>

International Journal of Current Research
Vol. 12, Issue, 06, pp.11883-11889, June, 2020

DOI: <https://doi.org/10.24941/ijcr.38842.06.2020>

INTERNATIONAL JOURNAL
OF CURRENT RESEARCH

RESEARCH ARTICLE

USE OF CLOSED SURGICAL EXPOSURE FOR THE TREATMENT LABIALLY IMPACTED MAXILLARY CANINE CONTAINING DENTIGEROUS CYST: CASE REPORT

¹Dr. Venkatesh Balaji Hange, ²Dr. Shishir Mohan Devki, ³Dr. Raunak Manjeet, ⁴Dr. Amit Kumar and ⁵Dr. Swati Srivastava

¹Postgraduate Student, Department Of Oral & Maxillofacial Surgery, Mathura, Uttarpradesh, India

²Head of Department, Department Of Oral & Maxillofacial Surgery, Mathura, Uttarpradesh, India

³Postgraduate Student, Department of Orthodontics, K.D. Dental College & Hospital, Mathura, Uttarpradesh, India

⁴Postgraduate Student, Department Of Oral & Maxillofacial Surgery, Mathura, Uttarpradesh, India

⁵Postgraduate Student, Department Of Oral & Maxillofacial Surgery, Mathura, Uttarpradesh, India

ARTICLE INFO

Article History:

Received 10th March, 2020

Received in revised form

19th April, 2020

Accepted 27th May, 2020

Published online 29th June, 2020

Key Words:

Maxillary Canine Impaction,
Buccal Eruption,
Surgical Exposure,
Orthodontic Biomechanics.

ABSTRACT

The most prevalent impacted teeth are the mandibular third molars, maxillary canines, mandibular second premolars, and maxillary central incisors. Maxillary canines are the 2nd most commonly impacted teeth encountered during orthodontic treatment. Studies by Johnston WD have shown that about two-thirds of maxillary canines are impacted on palatal side, one third are impacted labial side.(1) during the ages of 11 and 12 years permanent maxillary canine usually erupts into the oral cavity; but approximately 1-3% of the population has missing one or both the cuspids.(2) The incidence of impacted canine has been reported between 0.92% to 1.7% in the literature review .Dachi and Howell reported an incidence of 0.92%, Ericson and Kurol also reported an incidence of 1.7%,commonly seen in females (1.17%) than in men (0.51%) with a ratio of 2:1.4 .Bilateral impaction is rare seen in approx 8% of people with maxillary impacted cuspids.(3,4,5) Yamaoka *et al*, suggested that there was no difference in the incidence of completely impacted canines in the edentulous as compared with the maxillary arch having teeth.(6) Dewel concluded that the maxillary canines have not only the longest duration of evolution, but also the longest and perhaps most tortuous route to migrate from their point of origin, lateral to the piriform fossa, before they reach the point in full-occlusion .developmental point of view the crowns of the permanent canines is in close contact with the roots of the lateral incisors.(7) The management of a impacted cuspid commonly comprises of a surgical procedure to enable the tooth to be aligned via orthodontics. Two techniques of surgical exposure are given: An 'Open' exposure, which involves raising a mucoperiosteal flap, followed by removal of bone and mucosa overlying the tooth and placement of a surgical pack. The cuspid is subsequently aligned above the mucosa by orthodontics. shorter treatment time, and improved hygiene during treatment ,minimal effects on the periodontium are one of the advantages of open exposure. A 'Closed' exposure, comprises of raising a mucoperiosteal flap, limited removal of bone and instead of excision of the overlying mucosa, an attachment is bonded to the crown of the exposed cuspid, enabling proper alignment of the tooth from below the mucosa (2,8)

Copyright © 2020, Venkatesh Balaji Hange *et al*. This is an open access article distributed under the Creative Commons Attribution License, which permits unrestricted use, distribution, and reproduction in any medium, provided the original work is properly cited.

Citation: Dr. Venkatesh Balaji Hange, Dr. Shishir Mohan Devki, Dr. Raunak Manjeet, Dr. Amit Kumar and Dr. Swati Srivastava, 2020. "Use of closed surgical exposure for the treatment labially impacted maxillary canine containing dentigerous cyst: case report", *International Journal of Current Research*, 12, (06), 11883-11889.

INTRODUCTION

The most prevalent impacted teeth are the mandibular third molars, maxillary canines, mandibular second premolars, and maxillary central incisors. Maxillary canines are the 2nd most commonly impacted teeth encountered during orthodontic treatment. Studies by Johnston WD have shown that about two-thirds of maxillary canines are impacted on palatal side, one third are impacted labial side (Johnston, 1969) during the ages of 11 and 12 years permanent maxillary canine usually erupts into the oral cavity; but approximately 1-3% of the population has missing one or both the cuspids (Parkin, 2012).

The incidence of impacted canine has been reported between 0.92% to 1.7% in the literature review. Dachi and Howell reported an incidence of 0.92%, Ericson and Kurol also reported an incidence of 1.7%, commonly seen in females (1.17%) than in men (0.51%) with a ratio of 2:1.4 .Bilateral impaction is rare seen in approx 8% of people with maxillary impacted cuspids (Hsu *et al.*, 2019; Dachi, 1961; Ericson, 1986) Yamaoka *et al*, suggested that there was no difference in the incidence of completely impacted canines in the edentulous as compared with the maxillary arch having teeth (Yamaoka, 1996). Dewel concluded that the maxillary canines have not only the longest duration of evolution, but also the longest and perhaps most tortuous route to migrate from their point of origin, lateral to the piriform fossa, before they reach the point in full-occlusion developmental point of view the crowns of

*Corresponding author: Dr. Venkatesh Balaji Hange,
Postgraduate Student, Department Of Oral & Maxillofacial Surgery,
Mathura, Uttarpradesh, India.

the permanent canines is in close contact with the roots of the lateral incisors (Dewel, 1949). The management of a impacted cuspid commonly comprises of a surgical procedure to enable the tooth to be aligned via orthodontics. Two techniques of surgical exposure are given: An 'Open' exposure, which involves raising a mucoperiosteal flap, followed by removal of bone and mucosa overlying the tooth and placement of a surgical pack. The cuspid is subsequently aligned above the mucosa by orthodontics. shorter treatment time, and improved hygiene during treatment ,minimal effects on the periodontium are one of the advantages of open exposure. A 'Closed' exposure, comprises of raising a mucoperiosteal flap, limited removal of bone and instead of excision of the overlying mucosa, an attachment is bonded to the crown of the exposed cuspid, enabling proper alignment of the tooth from below the mucosa (Parkin, 2012; Andrew)

CASE REPORT

This 13-years-old male patient came to K.D. Dental college & hospital with chief complain of irregular arrangement of teeth. Patient does not have any prenatal & natal history, however familial history of malocclusion was present among siblings. On examination patient presents with skeletal class I jaw base relationship with normal to Hypo divergent growth pattern.(Fig.1) Patient has angle's class I malocclusion with proclined upper & lower anterior, cross bite in maxillary left side, retained deciduous canine in max. Right side & missing central incisor in mandibular left region, right maxillary canine was also missing (Fig.2) Visual inspection revealed presence of canine bulge between the lateral incisor and first premolar on the right side. Patient has convex soft tissue profile and competent lips.

A computed tomography (CT) scan was requested (Fig.3,4,5) for maxillary anterior region , which showed crown of impacted 13 placed on labial aspect which is directed in proximity with the root of 12. The root is placed palatal aspect and directed towards the floor of maxillary sinus in proximity with apical third of root of 14. The crown is enveloped with corticated well defined hypodensity Suggesting of Follicular Cyst/ Dentigerous Cyst I.R.T Impacted 13. There is ill-defined hypodensity seen in the periapical region of 13 Suggesting Of Rarefying Osteitis/ Chronic Periapical Abscess i.r.t 13. The root has open apex. A small breach is also seen in the floor of maxillary sinus. After reviewing clinical & radio-logic information surgical exposure of the maxillary right canine, followed by orthodontic guided eruption was decided closed method of surgical exposure were performed under local anaesthesia deciduous canine was extracted after achieving signs & symptoms of anaesthesia. Triangular full thickness mucoperiosteal flap raised using crevicular incision & vertical releasing incision given on right side over 1st premolar (Fig.6a). Initially bone removal done using round bur no.701 for localization of impacted canine after identifying cuspid bone removal done using straight fissure no.704 bur under saline irrigation using moor and gillbe collar technique (Fig.6b). Once the surgical exposure of the impacted teeth is over, a bracket with twisted wire ligatures was bonded to the enamel surface Crown & was linked via a ligature wire straight to the primary archwire the flaps are approximated using 3-0 black braided silk, vertical mattress suture & simple interrupted sutures were given(Fig.6c). Suture removal done after 1 week.

At the time of surgical exposure follicular tissue was removed & sent for histopathological examination.The examination revealed the cystic lesion as dentigerous cyst.

DISCUSSION

Broadly the etiology for delayed eruption of teeth is not only generalized but also localized. Generalized etiology comprise of endocrine deficiencies, febrile diseases, and irradiation , where as the most prevalent etiology for canine impactions are mostly localized and are the result of any one, or combination of the following factors: a) discrepancies between tooth size-arch length , b) prolonged retention or early loss of the deciduous canine, c) ectopic position of the developing tooth , d) the presence of gap such as alveolar cleft, e) ankylosis, f) formation of cyst & tumor, g) curved root, h) idiopathic condition with no apparent cause (Samir, 1992) If left untreated or ignored the canine impaction may lead to following consequences:- I)Labially or palatally impacted tooth trigger movement of the adjoining teeth, as well as arch length depletion. II) Unerupted cuspids may develops into a cyst or tumor and infection. III) may cause root resorption of the neighbouring lateral incisors and compromise the longevity of lateral incisors (5) IV) Internal resorption, V) referred pain VI) various combinations of these sequences.(10) In this case report the etiology was localized & mainly due to prolonged retention of the deciduous canine which is as per review literature.

Stellzig A *et al.* revealed that the occurrence of palatal impaction,exceeds that of labial impaction with a myriad range of ratio from 3:137 to 6:1.1& also suggested that arch length deficiency is one of the main culprit behind the labially impacted cuspid (11) In our case the impacted canine crown was labial aspect placed whereas root was on palatal aspect which is quite rare as per literature. In 1992, Samir E. Bishara indicated that the subsequent clinical signs may be suggestive of canine impaction: 1) Interrupted canine eruption or extended retention of the deciduous canine past the age of 14 to 15 years , 2) abnormal labial canine bulge 3) presence of a palatal bulge 4) delayed eruption, distal tipping, or migration of the lateral incisor (Samir, 1992). In this case report for surgical exposure of impacted cuspid closed surgical exposure technique were used.

This approach is convenient, as Orthodontic brackets are placed before the surgical exposure. But care should be needed as teeth are meant to be aligned and leveled before exposure because orthodontic traction is placed immediately after exposure surgical exposure can be achieved through less bone removal as compared to open eruption technique. There is no need of periodontal packs need as there is absence of open wound. Periodontal concerns are minimal as compared to open eruption technique, if gold chain is drawn through attached gingiva by the surgeon (Veerasathpurush, 2020). Parkin, NA, Deery C et.al, suggested that there was no difference in the operating time & patient reported outcomes between the Open and Closed surgical techniques for impacted canine..Even though most patients report pain , discomfort, and disruption of daily routines and necessity of regular pain relief upon surgical exposure, it was of short period of time in the most of the patients and subsidized after a few Days (Parkin, 2012). Over the period of time since discovery of x-ray ,numerous techniques are being used for the evaluation of impacted maxillary cuspids.

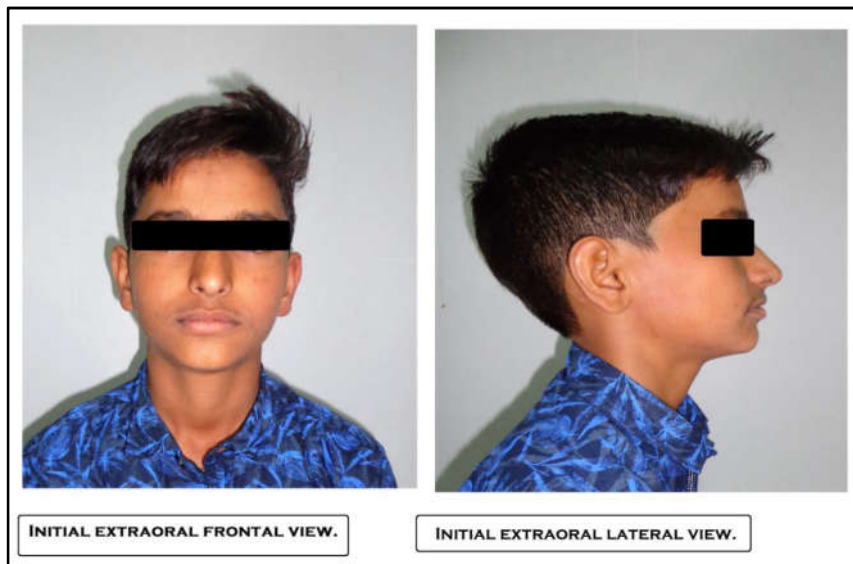

Figure 1 Clinical photographs of 14 yr old patient before treatment showing Initial extra oral frontal view & Initial extra oral lateral view.

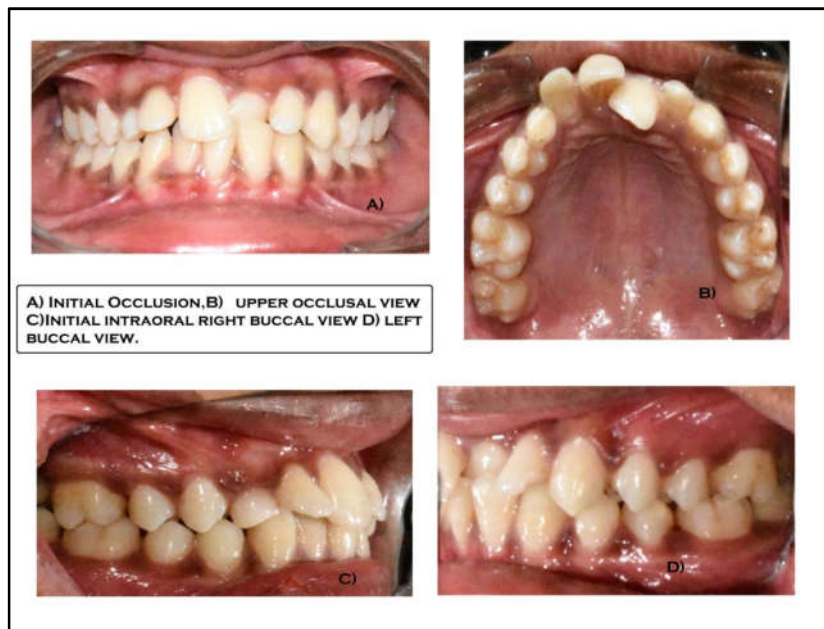

Fig.2 showing A) Initial occlusion B) upper occlusal view, C) intraoral right buccal view, D) left buccal view.

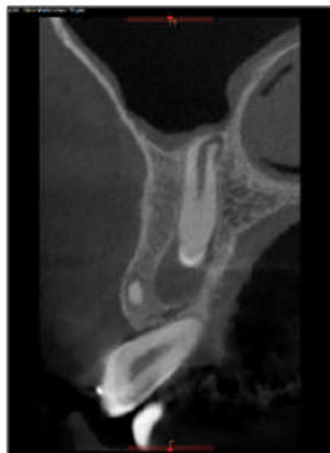

Fig. 3 showing a small breach is also seen in the floor of maxillary sinus along with corticated well defined hypodensity on sagittal CT scan.

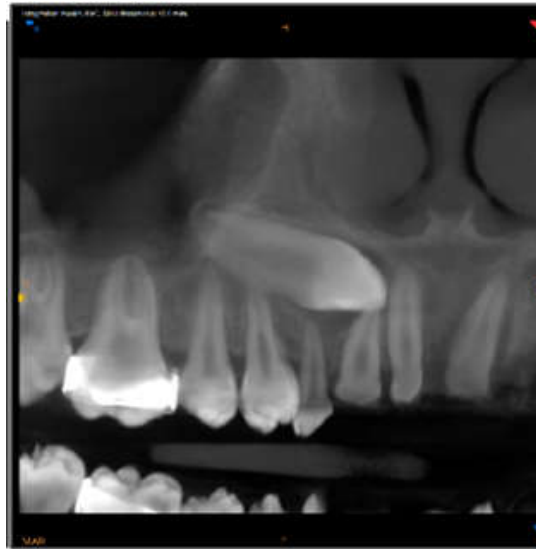

Fig.4 showing crown is enveloped with corticated well defined hypodensity i.r.t Impacted 13 on Axial CT scan.

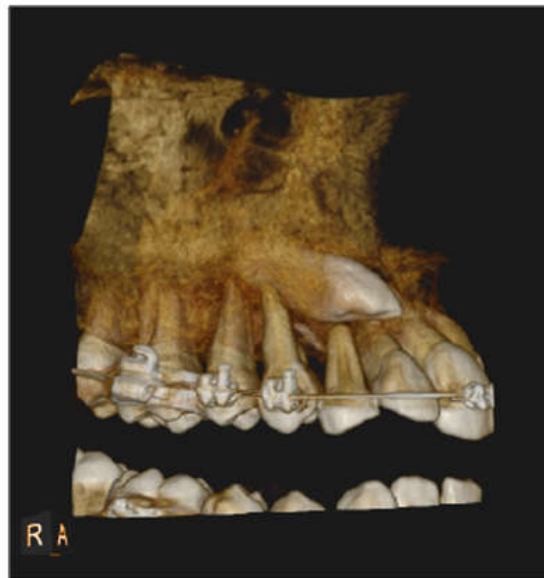

Fig.5 showing 3D reconstruction CT scan crown is placed on the labial aspect and root is placed on palatal aspect, deciduous teeth is also present.

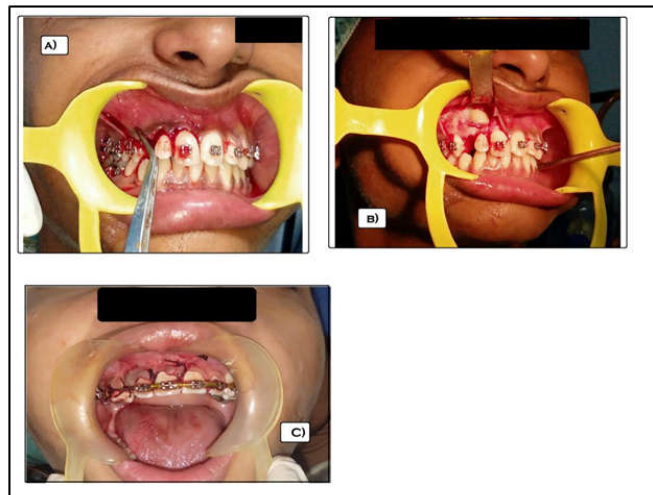


Fig.6 Showing A) Triangular full thickness mucoperiosteal flap raised using crevicular incision & vertical releasing incision. B)Surgical exposure by bone removal using moor & gillbe collar technique. C) flaps are approximated using 3-0 black braided silk, vertical mattress suture & simple interrupted sutures were given

Table 1 .Relative advantages and disadvantages of the closed surgical exposure, Gingivectomy & apically positioned flap

Feature	Closed Surgical Exposure	Gingivectomy	Apically Positioned Flap
Orthodontic treatment	Orthodontic brackets are placed before the surgical exposure. Orthodontic treatment can be started One to two weeks after surgery	Usually no need of Orthodontic traction as tooth erupts naturally. only leveling and alignment is adequate	Orthodontic treatment can be started Two to three weeks after surgery.
Visualization of exposed teeth	Not possible because a flap is placed over the exposure. Radiographs are necessary to visualize impacted tooth.	Tooth is clinically visible following exposure	Tooth is clinically visible following exposure
Bone removal	Comparatively bone removal is more	Minimum to null bone removal Comparatively	Moderate amount of bone removal
Management	No periodontal packs need to be placed because there is no open wound	periodontal packs need to be placed because there is open wound	Periodontal pack needs to be replaced periodically.
Need for re-exposures	a second surgery is needed if debonding of bracket occurs	There is no need for re-exposures unless there is tissue overgrowth	There is no need for re-exposures unless there is tissue overgrowth
Periodontal concerns	Reduced possibility of developing mucogingival problems	loss of attached gingiva, possible damage to periodontium	uneven gingival margin, Gingival inflammation, gingival recession may develop
Indications	used when tooth is in the center of alveolus or crown is significantly apical to mucogingival junction & in proximity with the nasal spine.	Indicated when Canine cusp is coronal to mucogingival junction (MGJ) along with adequate amount of keratinized gingiva is present where canine is erupted through bone.	used in labial impacted cases where gingivectomy can not be used due to amount of keratinized gingiva is less than 3mm.

These methods include intraoral techniques consist of occlusal and periapical projections and extraoral techniques consist of panoramic, posteroanterior or lateral cephalometric radiographs (Marisela, 2009). periapical film provides a two-dimensional representation impacted teeth, as we as mesial distal and superior inferior relation with neighbouring teeth using Tube-shift technique or Clark's rule, buccal-object rule. Occlusal radiographs are also useful to determine the buccolingual position of impacted teeth. Frontal and lateral cephalograms aid in determining the position of the impacted canine & its relationship to other facial structures, such as the maxillary sinus and the floor of the nose. Panorex films are also used to localize impacted teeth in all three planes of space (Samir, 1996; Marisela, 2009) computed tomography & cone beam computed tomography are the recent additions in diagnosis of impacted maxillary cuspids, they can provide more accurate information regarding location of impacted teeth. cone beam computed tomography gives 3 dimensional anatomy of impaction and also its relation with the adjacent structure without any error. in our case report we done a cone beam computed tomography (CBCT) scan of maxillary anterior region which not only showed location & relation of impacted teeth, but also presence of cyst formation & small breach in the maxillary sinus due to impacted teeth. Hence we recommend the use of CBCT scan in the surgical exposure if impacted teeth.

The most primitive prediction of an impacted maxillary canine can be deficiency of a canine bulge during regular orthodontic checkups at around 9 years of age, at which orthodontic consultation begins. If a canine is angled medially, with the crown located medially to the lateral border of the nasal cavity, the possibility of impaction should be considered. (12,14,15) presence of a palatal bulge and distal crown tipping of the lateral incisor also suggest probability of impacted canine. Palpation of the buccal surface of the alveolar process distal to the lateral incisor to help determine the position of the maxillary canine before its emergence. (15) after evaluating clinical & radiographic findings final diagnosis of impacted canine can be made.

According to Ericson and Kurok observations, increased width of the dental follicle (more than 3mm) was thought to be associated with cystic formation, but its not seen always substantially hence diagnosis of follicular or dentigerous cyst should be made on the basis of histopathological report. (5) In our case at the time of surgical exposure, follicular tissue was removed & sent for histopathological examination. The examination revealed the cystic lesion as dentigerous cyst. quick diagnosis and prediction of possible impaction are one of the most promising tools for managing impacted maxillary canines. orthodontic treatment followed by surgical exposure of the canine to bring it into occlusion should be done. Historically Orthodontic traction and self-transplants were treatment options for impacted canines in the review literature but, these are old, time-consuming and expensive treatments. Following unsuccessful orthodontic treatment, surgical extraction is performed as a prophylactic measure against the formation of pathological lesions (Marisela, 2009; Zasciurinskiene, 2008) According to Egle Zasciurinskiene; Krister Bjerklind *et al.* combined surgical-orthodontic approach in the treatment of impacted maxillary canines produces clinically acceptable periodontal conditions. Periodontal conditions of the impacted canine and adjacent teeth after surgical-orthodontic treatment depend on the initial vertical and horizontal position of the impacted canine (17) whereas the most prevalent technique for impacted canines to placed in occlusion are surgically exposing the teeth and allowing them to erupt naturally during early or late mixed dentition, or surgically exposing the teeth and placing a bonded attachment to and using orthodontic forces to move the tooth. The three methods for uncovering a labially impacted maxillary canine are gingivectomy, creating an apically positioned flap and using closed eruption techniques (Samir, 1992; Kokich, 2001). Some less commonly used treatment alternatives mentioned by Samir E. B. comprises of I) Removal of the impacted canine followed by migration of adjoining premolar in its extraction socket. II) To move the buccal segment mesially to close the residual space can be done by removal of the canine followed by posterior segmental osteotomy. III) Prosthetic replacement of the canine (Samir,

1998) The efforts should always be made to preserve the impacted canine but there are some exceptions where extractions is must so as to avoid future complications. These are :-a) if ankylosis found in impacted teeth and thus unfit for transplantation b) if impacted canine is undergoing external or internal root resorption; c) severe dilaceration of root d) the impacted canine is in unfavourable relation with adjacent structure & orthodontic treatment will worsen the condition. e) if the occlusion is acceptable, with the first premolar in the position of the canine f) if there are pathological changes, such as cystic formation, infection, etc. g) the patient not willing for orthodontic treatment (Samir, 1992). Gingivectomy:- Indicated when Canine cusp is coronal to mucogingival junction (MGJ) along with adequate amount of keratinized gingiva is present (so min. 3mm of keratinized gingiva should be left after surgery) where canine is erupted through bone. Advantages of gingivectomy includes no need of Orthodontic traction, Easy to perform & relatively less invasive technique. Approx one half to two third of crown must be uncovered for placement of orthodontic bracket using Kirkland gingectomy knife. Barrier can be placed over the exposed crown to prevent overgrowth of gingiva. disadvantages of this technique are Used only occasionally, loss of attached gingiva, possible damage to periodontium; potential gingival overgrowth at surgical site (Marisela, 2009).

- **Apically positioned flap:** This type of flap is used in labial impacted cases where gingivectomy can not be used due to amount of keratinized gingiva is less than 3mm.(Table.1)Canine crown is apical to mucogingival junction (MGJ). The crestal incision is placed over the edentulous ridge so as to preserve keratinized gingiva as much as possible, incision then extended in vertical direction into the vestibule depth to raise a split thickness flap. Approximately two third of crown must be uncovered. Finally the pedicle flap is apically positioned & sutured to the periosteum. Orthodontic treatment can be started Two to three weeks after surgery. Commonly performed in cases where less keratinized gingiva is available. Disadvantages includes gingival recession may develop post operative; height differences causing uneven gingival margin and Increased risk of orthodontic relapse due to formation of accessory frena; more invasive procedure. Gingival inflammation & loss of alveolar bone may occur in post operative stages complications may develop if canine is in proximity with nasal spine.(14,19)
- **Closed eruption:** Closed eruption approach is used when tooth is in the center of alveolus or crown is significantly apical to mucogingival junction & in proximity with the nasal spine. Orthodontic treatment can be started One to two weeks after surgery. This is more esthetic procedure when compared to that of gingivectomy & apically positioned flap. Tooth movement can be easily achieved. The crestal incision is placed over the edentulous ridge so that a full thickness flap can be raised & adequate bone removal is done for placement of orthodontic bracket (Ericson, 1986; Samir, 1998)
- Before flap closure it is recommended that gentle luxation of tooth is performed using osteotome or small straight elevator. This is done to assure that there is absence of tooth ankylosis. Flap is then approximated back to its previous position by using sutures. Its disadvantages includes a second surgery is needed if debonding of bracket occurs. Patient discomfort is more than the gingivectomy & apically positioned flap

possibility of developing mucogingival problems (Marisela, 2009; Jason Cooke, 2006) In our case report the crown of tooth was significantly apical to mucogingival junction causing breach in the maxillary sinus situated deep into the bone ,hence the closed surgical exposure .

Conclusion

Impacted maxillary canine is 2nd most prevalent impacted teeth, palatal impaction is more common than labially impacted teeth. Management of critical impacted teeth is affected by multitude of factors hence discussion among maxillofacial surgeon, orthodontist & periodontist is crucial so as to provide appropriate therapy to patient regarding function as well as esthetic. Cone beam computed tomography can provide accurate information regarding diagnosis & location of impacted teeth hence it can be routinely used in orthodontics for the diagnosis & treatment of impacted canine. Labially impacted canine can be treated using various methods such as closed approach, gingivectomy & apically positioned flap.the procedures such as gingivectomy & apically positioned flap are occasionally used because of their limitations. Closed approach if properly performed can provide more esthetic & functional result even in complex cases of labially impacted canine with reduced periodontal concerns.

REFERENCES

- Andrew D. Schmidta, Vincent G. Kokichb, American Journal of Orthodontics and Dentofacial Orthopedic, Volume 131, Number 4 ,449-456.
- Becker A. 2020. The Orthodontic Treatment of Impacted Teeth, 2nd ed, Abingdon, Oxon, England: Informa Healthcare; 2007:1-22815)Matheus Francisco Barros Rodrigues, Layla Louise de Amorim Rocha et.al., Piezosurgery-Assisted Surgical Treatment in Impacted Canine Transmigration, Case Reports in Dentistry, Volume, Article ID 2687827, 3 pages, <https://doi.org/10.1155/2020/2687827>.
- Dachi SF, Howell FV. 1961. A survey of 3,874 routine full mouth radiographs, Oral Surgery Oral Medicine Oral Pathology, 14:1165-9.
- Dewel BE. 1949. The upper cuspid: Its development and impaction, Angle Orthodontics, 19:79-90.
- Ericson S, Kurol J. 1986. Radio graphic assessment of maxillary canine eruption in children with clinical signs of eruption disturbances, *European Journal of Orthodontics.*, 8:133-40.
- Hsu YC, Kao CT, Chou CC, Tai WK, Yang PY. 2019. Diagnosis and Management of Impacted Maxillary Canines, *Taiwanese Journal of Orthodontics*. Vol. 31. No. 1, b4-b12.
- Jason Cooke, Hom-Lay Wang, 2006. Canine impactions :incidence & management ,The Int J periodontics & conservative Dent ,vol. 26,no.5,482-492.

- Johnston WD, 1969. Treatment of palatally impacted canine teeth, *Am J Orthod.*, 56:589–596.
- Kokich VG, Mathews DA, Impacted teeth: surgical and orthodontic Considerations, McNamara JA, Brudon WL, Kokich VG, eds, Orthodontics and Dentofacial Orthopedics, Ann Arbor, Mich.: Needham Press; 2001:395-422.
- Marisela M. Bedoya, Jae Hyun Park, 2009. A review of the diagnosis and management of impacted maxillary canines, *Journal of American Dental Association.*, 140(12):1485-1493.
- Parkin, NA, Deery, C, Smith, AM, Tinsley, D, Sandler, J and Benson, PE. 2012. No difference in surgical outcomes between open and closed exposure of palatally displaced maxillary canines. *Journal of Oral and Maxillofacial Surgery*, 70 (9). 2026 - 2034 .
- Parkin, NA, Deery, C, Smith, AM, Tinsley, D, Sandler, J and Benson, PE 2012. No difference in surgical outcomes between open and closed exposure of palatally displaced maxillary canines. *Journal of Oral and Maxillofacial Surgery*, 70 (9). 2026 - 2034.
- Samir E. Bishara, 1992. Impacted maxillary canines: a review, *Am j Orthoo Dentofac Orthop.*, 101:159-71.
- Samir E. Bishara, Clinical Management of Impacted Maxillary Canines, Seminars in Orthodontics, Vol 4, No 2 (June), 1998: pp 87-98.
- Stellzig A, Basdra EK, Kourposch G.1994. The etiology of canine tooth impaction: A space analysis. *Fortschritte der Kieferorthopadie.*, 55:97-103.
- Veerasathpurush Allareddy *et al.* 2019. Orthodontic and Surgical Considerations for Treating Impacted Teeth ,*Oral Maxillofacial Surg Clin N Am* 32 (2020) 15–26 ,<https://doi.org/10.1016/j.coms.08.005>.
- Yamaoka M, Furusawa K, Fujimoto K, *et al.* 1996. Completely impacted teeth in dentate and edentulous jaw, *Australia Dent J.*, 41:169-172.
- Zasciurinskiene, Bjerklin, Smailiene, Sidlauskas, Puisys, 2008. Initial Vertical and Horizontal Position of Palatally Impacted Maxillary Canine and Effect on Periodontal Status Following Surgical-Orthodontic Treatment, *Angle Orthodontist*, Vol 78, No 2, 2008,275-281.
