



ISSN: 0975-833X

Available online at <http://www.journalcra.com>

INTERNATIONAL JOURNAL
OF CURRENT RESEARCH

International Journal of Current Research
Vol. 13, Issue, 07, pp.18318-18325, July, 2021

DOI: <https://doi.org/10.24941/ijcr.41764.07.2021>

RESEARCH ARTICLE

BETTER VISUALIZATION OF PATELLO FEMORAL JOINT SPACE BY USING DIFFERENT X-RAY TUBE ANGULATION

^{1,*}Neelam Rao Bharti, ²Ms. Abhilasha Verma, ³Bhawna Solanki and ⁴Dr. Rajul Rastogi

¹Master of Science in Radio Imaging Technology (Mrit), 2018-2020

²Assistant professor, TMU

³Assistant Professor, Noida international University

⁴Associate Professor, TMU

ARTICLE INFO

Article History:

Received 25th April, 2021
Received in revised form
19th May, 2021
Accepted 24th June, 2021
Published online 30th July, 2021

Key Words:

Computed Radiography,
Image Receptor, Foam Pad.

*Corresponding author:
Neelam Rao Bharti

ABSTRACT

Aim of the study was to evaluate better visualization of patellofemoral joint space among various x-ray tube angulation of 15°, 20°, 25° craniially with flexion of 45° with use of the anterior border of the patella and tibial tuberosity. **Objectives:**

1. To determine the skyline or axial view has provided useful information about the morphology and anatomy of the patellofemoral joint.
2. To assess the clinical handiness of the new horizon, see imaging procedure as a standard strategy into clinical practice.

Methodology: our database consisted of various x-ray tube angulations of 15°, 20°, 25° craniially with flexion of 45° of the patella of the same patients. We are taking images from three different angles. And the IR read to the reader and image displayed and the evaluation will be made by blinding the radiologist and the score for the different projection will be recorded. The Final score will be tabulated according to the evaluation given by the radiologist. obtained with use of inferior –superior view of skyline projection for the radiographic diagnosis of knee-joint diseases. **Result:** A total of 29 patients ranging in age from 20 to 70 years with mean age 39.21 years. **Conclusion:** This prospective clinical study confirmed that the best visualization of the patellofemoral joint space with the skyline-view imaging technique, which uses the 25° x-ray tube angulation with the 45° knee flexion in the supine position. That provides more accurate axial images of the patella.

Copyright © 2021. Neelam Rao Bharti et al. This is an open access article distributed under the Creative Commons Attribution License, which permits unrestricted use, distribution, and reproduction in any medium, provided the original work is properly cited.

Citation: Neelam Rao Bharti, Ms. Abhilasha Verma, Bhawna Solanki and Dr. Rajul Rastogi. "Better visualization of patello femoral joint space by using different x-ray tube angulation", 2021. International Journal of Current Research, 13, (07), 18318-18325.

INTRODUCTION

X-beam are electromagnetic beams that travel in a straight line at the speed of light. Sir Wilhelm Conrad Roentgen on 8 November 1895 discovered the x-rays. when he was researching the conduction of electricity through gases in glass tubes at low pressure. He observed invisible rays because of the fluorescence of barium Platinocyanide. Roentgen received in 1901 the first Nobel Prize in physics for his discovery.

PRODUCTION OF X-RAYS: X-beams are delivered by vitality change when quick-moving electrons from the warmed fiber of the x-beam tube associate with the tungsten anode (target). At the point when quick-moving electrons are abruptly halted they have the motor vitality, that is active vitality is changed over into heat and x-beams.




Fig.1.1 Sir Wilhelm Conrad Roentgen

X-ray machine: It is the machine that produced x-rays with the help of an x-ray generator and an x-ray detector.



Figure 1.2. 800mA computed radiography

Product Descriptions

Application	Radiography
Tube Type	Rotating Anode
Current	800m A
Peak kilo voltage	100kvP
Operation Mode	Automatic
Usage/ application	TMU hospital
Power Source	Electrical

The X-ray tube: In 1933 the pivoting anode x-beam tube was invented. In this tube, the anode is pivoted before emitting the electron. It was developed to increase the speed of spinning the target during exposure. The significant segments are anode, cathode, glass envelope, rotor/stator, and cylinder housing.

Operating Console: An operator selects kVp, mA, central spot size and an exposure time, and the central spot size. Kilo voltage peak chose the x-beam pillar vulnerability. The x-beam tube current chooses the x-beam transition radiated by the x-beam tube at a given kVp. The product of the x-beam tube current & exposure time.

High voltage Transformer: The high voltage transformer is utilized to either high or low voltage and flow in an electrical circuit up to 1000mA required for the production of x-beams in the x-beam tube. It works on the principle of mutual induction.

Collimator: Collimators are modifying the shape and size of the x-rays. That are produced from the x-ray tube. Collimators are appended to the x-bam tube lodging of the x-ray tube in which the equal contradicted lead shades are available.

Patient table: The x-ray table provides perfect patient positioning with a large floating table top that can support virtually all patient sizes and has height adjustment facilities.

Framework: The essential motivation behind the x-beam framework is utilized to enhance the difference and nature of the picture by decreasing the dissipated radiation. In the item the dispersed radiation emerges is thicker than 10cm. It normally lead, nickel or aluminium.

Bucky: A Bucky is an equipment that is set up underneath the patient table, and a cabinet like a gadget that is a framework in which the tapes are slid into before shooting an x-beams.

Radiographic x-beam film: Radiographic movies consist of the emulsion-gelatin layer that contains the radiosensitive silver halide precious stones. For instance, silver chloride or

silver bromide. A base layer that is adaptable, and straightforward blue-coloured.

History of computed radiography: In 1970 computed radiography was presented and in the late 1980s it was expanding and generally utilized when the new century rolled over the same number of divisions introduced PACS and working together with the advancement of the electronic clinical record.

Introduction of Computed Radiography: Computed radiography (CR) is the photo-stimulable phosphor finder (PSP) framework. The phosphor utilized in screen-film radiography, for example, Gd2O2S produce light when struck by an x-beam bar, PSP screens are likewise called capacity phosphors or imaging plates.

Principle of CR: Computed radiography is a regular projection radiography in which the picture is obtained in a computerized position utilizing an imaging plate. In the CR framework, the imaging plate (IP) is the most recent innovation utilized in distinguishing and recording X-beam pictures data of high calibre and affectability. The pictures will be quickly transmitted through the electrical lines and shown on a cathode beam tube.

The computed radiography system components:

-) A digital image receptor (the imaging plate)
-) A digital image processing unit
-) An image management system
-) Image and data storage devices
-) Interface to a patient information system
-) A communications network
-) A display device with viewer operated controls

Computed radiographic IP: Computed Radiography IP consists of the barium fluorohalide. That is an adaptable sheet which is encased in a tape. The IP is presented to the x-beams that are like radiographic film, and the CR tape is then directed to a CR peruser.

CR Image handling unit

-) The tape is embedded into the per user and the imaging plate is precisely expelled from the tape.
-) The imaging plate is framed by a moving stage and examined by a laser pillar.
-) The laser light animates the outflow of caught vitality in the imaging plate, and obvious light is radiating from the plate.
-) The light transmitted from the plate is gathered by a fibre-optic light and strikes a photomultiplier tube (PMT), and produces an electrical sign.
-) The electrical sign is digitized and put away.
-) Then the plate is presented to splendid white light to eradicate any leftover caught vitality. and afterward the imaging.

X-RAY TUBE ANGULATION: Tube tilt is required in some procedures in which the x-beam cylinder can be angulated either up (cephalad) or down (caudal) to a specific number of degrees. A pointer of some cylinder is mounted legitimately on the x-beam tube lodging estimates tube tilt.

Focal Beam: The focal beam is a non-existent x-beam that goes to the focus of the whole x-beam shaft. We utilize the focal beam to point the x-beam shaft where we need it to go.

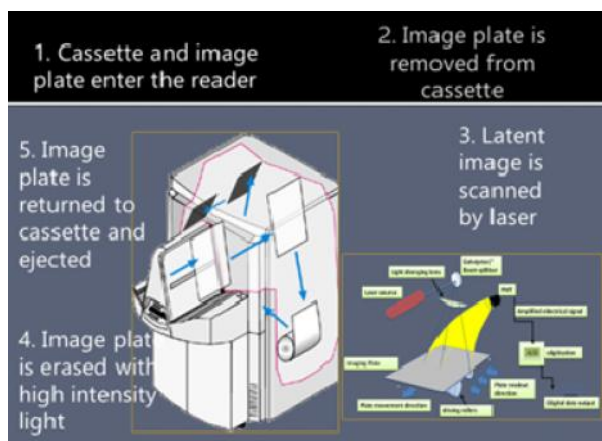


Figure 1.3: CR imaging processing

The vast majority of the x-beam's perspectives will have a particular anatomical point where the processed radiography tape ought to be put. The collimator of the x-beams machine contains a light that enlightens the life systems that will be uncovered. The focus of the light field is set apart by line of sight, which is represented by a computed radiography cassette.

IMAGE RECEPTOR: The picture receptor is a gadget that changes the x-beam bar into a noticeable picture. What's more, the picture receptor might be a radiographic film or tape, a bright screen utilized in fluoroscopy or registered radiography

SID: (Source to picture separation)- The more noteworthy the separation between the wellspring of the x-beam tube and the picture receptor tape, the more prominent the picture sharpness

EXPOSURE FACTOR: milliampere seconds (mAs)- mili amp. Second is the result of x-beam tube current and introduction time (mA) and introduction time (second). It demonstrates the measure of radiation being utilized and influences the film darkening delivered.

kilovoltage (kVp): As the kVp is increased, the penetrating power of radiation produced is increased. The kilo voltage must be with the end goal that the radiation can enter the body and arrive at the film. Greatest complexity can be acquired if the most reduced conceivable kV is utilized which will permit the radiation to infiltrate the densest piece of the body.

RADIATION PROTECTION

Protective Barriers to the radiation protection¹: Three methods to control radiation exposure levels to the radiation of the patient that is known as cardinal principle.

Time, Distance, Shielding/Barriers: The core value of radiation wellbeing is "ALARA" that's "as low as reasonably achievable" this standard implies that regardless of whether it is a little portion if getting that portion has no immediate

advantage you should attempt to maintain a strategic distance from it.

Personal Radiation Protective devices: Lead Gloves that is protection to the hand

Eye protection to the 0.15mm lead-equivalent goggles
Thyroid collar to decrease in scattered radiation in neck area
The Lead apron is a 0.5mm lead sheet which is protective to the radiation.

PROTECTION FOR FEMALE PATIENTS: Any female patients undergoing a radiological examination used the 28 days' rule.

28 DAY RULE: The radiological assessment, if so supported, can be conveyed all through the cycle until a period is missed. Subsequently, the center is moved to a missed period and the chance of pregnancy. On the off chance that there is a missed period, a female ought to be viewed as pregnant except if demonstrated something else. In such a circumstance, each care ought to be taken to investigate different techniques for getting the required data by utilizing non-radiological assessments. The primary hazard is that of premature birth if the radiation presentation brings about the death of the baby. It requires a fetal portion of more than 100 mGy for this to happen. In view of this, it was recommended to get rid of the 10-day lead and supplant it with a 28-day rule .

ANATOMY OF KNEE JOINT: The patellofemoral joint is composed of the bony patella. The patella sits within the intercondylar or trochlear groove where the lateral condyle is of slightly greater diameter than the medial. The most intricate joints in the human body are the knee joint.

ARTICULAR SURFACES^[2]: The knee joint is framed by

-) The condyles of the femur
 -) The condyle of the Tibia and fibula
 -) The patella
- The knee joint is the sort of synovial joint.

The synovial joint also contains a synovial fluid-filled sac outside the main joint cavity. The synovial permits a wide range of motion; they are all freely movable.

LIGAMENTS ^[3]: The knee joint forms one or more of the ligaments. Some ligaments provide stability for the knee joint.

-) Posterior cruciate ligament
-) Anterior cruciate ligament
-) Tibial collateral ligament
-) Fibular collateral ligament
-) Capsule ligament with synovial membrane
-) Oblique posterior ligaments
-) Arcuate ligament
-) Coronary ligaments
-) Transverse ligament
-) Ligamentum patellae

² PR Ashalatha, G. Deepa, foreword Mary sham bhat, third edition.135; textbook of anatomy & physiology for nurse

³ Stephanie Ryan et al. 3rd edition 2011,296-299; Anatomy for diagnostic imaging

¹ Satish K. Bhargava, Sumeet Bhargava, a fifth edition, 151; textbook of Radiology for residents & technicians

The primary tendons are the patellar tendon, an augmentation of the quadriceps ligament, the popliteal tendons at the rear of the knee, and the security tendons to each side. Outer tendons of the joint offer further help, making it a hard joint to disengage.

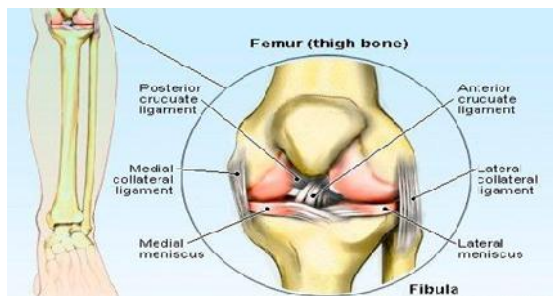


Figure 1.4. Anterior view showing with some ligaments

MENISCI: The menisci are composed of fibrocartilage. The menisci are C-molded semilunar rings between the articular surfaces of the femoral condyles and the tibial level. The medial & lateral menisci (or semilunar cartilages).

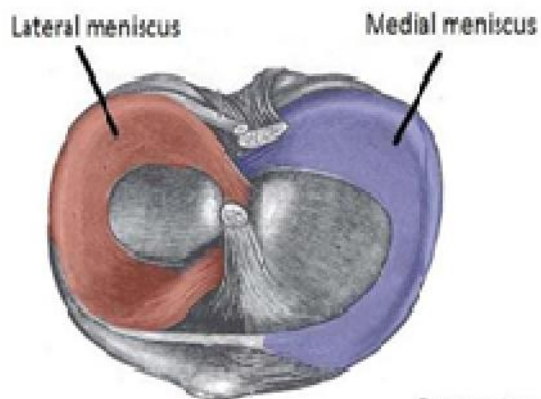


Figure 1.5. The menisci of the knee joint, superior surface of the tibia

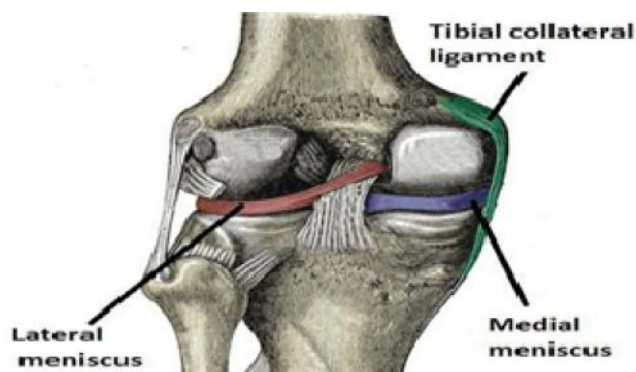


Figure 1.6. Posterior view of the knee joint

BURSA: In radiographs, the suprapatellar bursa is best observed when liquid is enlarged. It is seen to have delicate tissue thickness over the patella. Bursae and stack of fat are various. The erosion between a bone and a tendon or ligament and between the skin and the patella is forestalled by bursae.

KNEE CAP: The patella or knee top is the biggest and most consistent sesamoid bone in the body. The patella is a level triangular bone arranged at the knee joint.

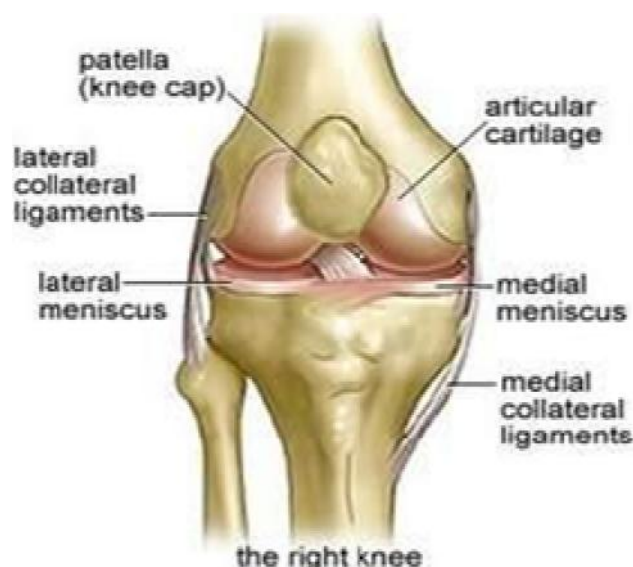

Figure 1.7. Anterior view showing some ligaments with knee cap
SYNOVIAL MEMBRANE: The synovial layer covers the cruciate tendons and the stack of the fat. Synovial membrane of a supra-patellar bursa is in communication with the synovial membrane of the joint.

Below the patella, the synovial membrane forms a fold known as alar folds. Between synovial folds and ligamentum patellae, there is a good amount of fat known as an infrapatellar pad of fat. The cruciate ligament is covered by a synovial membrane from the front and sides only.

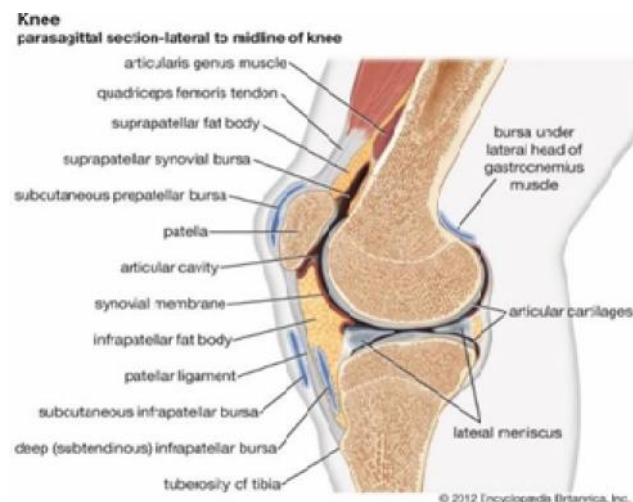


Figure 1.8. Lateral view of a knee joint showing synovial membrane

MOVEMENTS⁴: In the knee joints there are four main movement presents:

Extension: In which the tibial tuberosity inserts and furthermore, created by the quadriceps femoris
Flexion: It is delivered by the hamstrings, gracilis, Sartorius, and popliteus.

Horizontal pivot: it is delivered by the biceps femoris.

Average revolution: it is created by five muscles; semimembranosus, semitendinosus, gracilis, Sartorius, and poplite

⁴ Richard S.Snell, MD ,PhD 9TH Edition Clinical Anatomy by regions

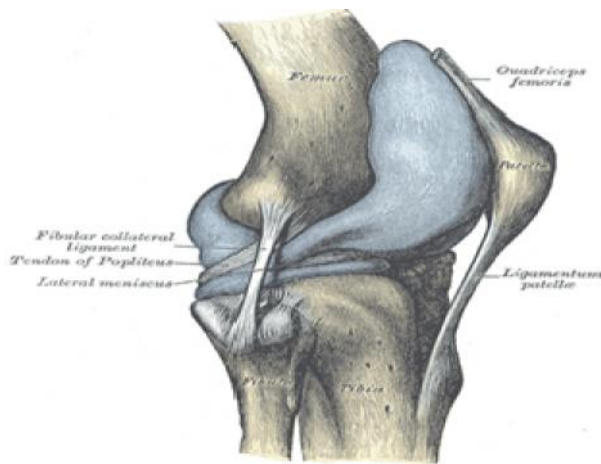


Figure 1.9. Lateral view of knee joint showing the tendon and femoris muscles

Knee joint projections

-) Antero-back
-) Lateral – fundamental
-) The parallel – level pillar
-) Antero-back – standing projections
-) Postero-foremost sideways
-) Antero-back diagonal
-) Intercondylar indent (burrow)

Routine imaging projections

-) Anterior posterior view
-) Semi flexed lateral view
-) Tunnel View
-) Skyline views

Skyline projections (skyline laurin view)⁵

The Horizon View can be utilized for:

- To assess the retro patellar joint space for degenerative malady;
- Assess the patella separation with tendon laxity;
- For findings of chondromalacia patellae;
- Affirm the nearness of a vertical patella crack in intense injury

The ideal retro-patellar joint dividing happens when the knee is flexed 45 degrees. Further flexion manoeuvres the patella into the intercondylar score, diminishing the joint dispersing; as flexion expands, the patella tracks over the horizontal femoral condyle. The patella moves a separation of 2 cm from full expansion to full flexion.

There are three strategies for accomplishing the horizon projection:

- Conventional infero-superior- beam caudo-cranially
- Supero-inferior – beam craniocaudal; (skyline merchant view)
- Infero-superior – patient prone beam 90°.

AIM AND OBJECTIVE OF THE STUDY

AIM: Better Visualization of patellofemoral joint space by using different tube angulation in the inferior –superior projection of the knee.

OBJECTIVE: To evaluate better visualization of patellofemoral joint space among various x-ray tube angulations of 15°, 20°, 25° cranially with flexion of 45°.

- To assess the clinical handiness of the new horizon, see imaging procedure as a standard strategy into clinical practice.
- To determine the skyline or axial view has provided useful information about the morphology and anatomy of the patellofemoral joint.

NEED OF STUDY

- To evaluate the clinical useful projection for demonstration of better patellofemoral joint space.
- The limited article was found which can provide consistent image quality in 30° knee flexion & not appear patellofemoral joint space in the image
- To assess the handiness of the new procedure with respect to reproducibility.

REVIEW OF LITERATURE

Ahamad et al: on their study "A Skyline view imaging technique for the axial projection of the patella; a clinical study".

They use total patient 103 ranging in age from 16-86 years & 118 pairs of knee image, the image obtained with the two techniques (patellar axial & skyline view). Hub pictures of the patella are helpful in the analysis of patellar precariousness brought about by subluxation. Hub pictures are obtained with anteroposterior and horizontal perspectives for analysis of osteoarthritis of the knee, rheumatoid joint inflammation of the knee, and foremost patellar agony. In the skyline view, they maintained a 60° flexion angle of knee joint & incident angle at 19° cranially to the reference line between the front outskirts of the patella and the tibial tuberosity. The processed radiography tape was put on the thigh opposite to the cylinder edge. The imaging conditions were followed by – Cylinder voltage of 50 kV, Cylinder current of 200mA, Imaging time of 0.1s X-beam tube frequency point separation of 110cm. The separation between the occurrence point and film is 20cm. They utilized an x-beam imaging gadget 1, A x-beam high – voltage gadget, and a picture peruser, which were BENE0 (Fujifilm clinical Tokyo, Japan), UD150L-40(Shimadzu Kyoto, Japan) and FCR – XL2 (Fujifilm clinical). The point was estimated with a neural connection programming bundle with the 3D workstation ZIO station 610 (AMIN, TOKYO Japan) on picture show gadget EIZO flex check S2100. They have found the relative errors of the axial image of the patella in 0.40 with conventional technique & significantly different at 0.30 skyline view. They conclude that the skyline –view which uses the patellar axial is an increasingly exact image picture than the regular imaging. They found various advantages of the new technique was- (a) the expanded situating opportunity makes it conceivable to perform imaging in standing burden-bearing and non-load-bearing positions. (b) imaging can be performed with the patient in the position nearest to that where they experience torment.

A.P. Davies, MRCS & J. Bayer, MRCS et al: on their study "The optimum knee flexion angle for skyline radiography is thirty degrees". They use of total 56 patients ranging in age from 12-29 year & 67 knee image,) they have to Using the radiographic technique of Settegast. In which the patient is prone with the knee flexed to 120° and the x-ray beam is

⁵ A Stewart whiteley et al 2005 12th edition Clark's positioning in radiography

vertical. And another technique is the Merchant technique in which the patient is supine and the knee is flexed to 45° and the x-ray beam is proximal to distal. And another technique of Laurin technique in which the patient is supine and knee flexed 20° to 30° with the x-ray beam distal to proximal. One another technique Facet technique in which the patient is supine and the knee flexed 30° and the x-ray beam was distal to proximal. They have to take various radiologic parameters these are defined to allow measurement of numerous patellofemoral disorders. The sulcus point with a mean of 138° and a standard deviation of 6° measures trochlear dysplasia. The congruence angle with a mean of - 6° and a standard deviation 11° measures patellar subluxation. Lateral displacement is abnormal if the average fringe of the patella is sidelong to the average condyle. This angle measures pure patellar translocation. The lateral patellofemoral angle normally open laterally and measures pure patellar tilt. The facet angle measures the depth and fit of the patella in the trochlea. They Using these methods and determined the optimum knee flexion angle for skyline patellofemoral radiographs. They have to compare the results of skyline radiographs taken at 30°, 50° & 90° knee flexion. They have change in these parameters as knee flexion increased & determine at which knee flexion angle the greatest number of abnormality detected. They need to establish that the ideal knee flexion plot for horizon radiography is 30, measurements of radiographic patella-femoral parameters are most reproducible from radiography obtained at this angle & the greatest number of abnormalities detected. Dr. Ayush Goel and Andrew Murphy et al: on their investigation "knee (horizon laurin see) "They must be the patient is semi-prostrate on the table holding an identifier prevalent of the patella in the scene direction. The patient's feet ought to be exceptionally near the x-beam tube. A pad or pad ought to be set behind the patient to help them in keeping up this position and the knee flexion 45° & central ray will be cranial angle 160 from horizontal shooting inferno-superior towards the patella.

They have to collimate horizontally to incorporate the skin edges of the knee, substandard compared to incorporating the femoro-patellar joint space, better than incorporating average skin edge. They have used the tube voltage 60-70kVp and tube current was 7-10mAs exposure factor. And the distance between the patient and the detector was 100-120cm. They evaluate the patella ought to be liberated from the superimposition of all hard structure & clear representation of the patellofemoral joint space. Hwee-yee Christian Heng and Hamid Rahmatullah Canister ABD Razak et al: on their study "Radiographic grading of the patella-femoral joint is more accurate in skyline compared to lateral view" they use the total number of 63 patients (21 male & 42 female) ranging of the age 37-67-year knee osteoarthritis image. A conclusion of PFOA was made when patients gripe of front mechanical knee torment for over 2 months with radiographic proof and they were found to have articular ligament degeneration of the patellofemoral joint. Each understanding has a weight-bearing horizon radiograph of the patellofemoral joint that was taken in 30° flexion and sidelong view radiographs of the knee were taken in 30° flexion indicative knee acquired with a normalized radiographic strategy and position. Every single measurable examination was performed utilizing the Factual Bundle for the Sociologies (SPSS) Variant 20 (IBM® SPSS Measurements, Armonk, New York, USA). The alpha was set to 0.05 for your measurable examinations.

The connection between K&L reviewing of horizontal and horizon radiographs and seriousness of articular ligament degeneration was assessed utilizing Spearman's relationship. Their investigation has indicated the relationship of side effects with radiographic finding the horizon and horizontal view, usually assessing malady in the patellofemoral compartment; they have utilized the K&L evaluating scale to measure the seriousness of radiographic osteoarthritis.

They discovered the K&L evaluating scale was 0.263 (P< 0.037; 95% CL 0.017-0.479) for horizon see and 0.222 (P=0.040; 95% CL, 0.027-0.445) for horizontal radiographs. Measurable investigations of his results indicated that horizon radiographs were better than parallel radiographs as far as particularity, PPV, NPV, and exactness. The horizon radiographs were over 10% more exact than sidelong radiographs.

MATERIAL AND METHODS

Scan protocols

Project and Study Design: The study is carried out on SKYLINE PROJECTION OF KNEE JOINTS in diagnosis patients of TMU hospital healthcare. The values from each x-ray image and in every patient were to find out the normal knee.

Setting and Resources: The project setting was in TMU hospital located in an urban area of the district of Moradabad. The hospital is equipped with an 800mA x-ray machine.

Study Population: The population consisted of patients aged 20 to above years undergoing COMPUTED RADIOGRAPHY of the SKYLINE PROJECTION OF KNEE JOINTS. The sample included a random number of subjects admitted in the hospital and outpatient of the hospital that underwent osteoarthritis and pain in knee joints. Between the months of 1st October 2019 and 30th March 2020.

Sample size: In this prospective study, I used the most appropriate skyline projection of knee joints. A total of 30 patients are included in this study to carry out 20 years above patients.

Selection Criteria

Inclusion Criteria: In this study, we will take all patients having 20 years above osteoarthritis and knee pain patients referred for skyline projection of knee joints examination. Considering the patient of age-related 20-60ys in 3 groups according to x-beam tube angulation

- Group 1 (15° x-beam tube angulation.)
- Group 2 (20° x-beam tube angulation)
- Group 3 (25° x-beam tube angulation.)

Exclusion criteria

-) Unscrew of knee joint fracture,
-) Pathology of knee joints.
-) In the pregnancy.
-) Unconscious patients
-) Chronic osteoarthritis

METHOD /PROCEDURE

Explanation of the procedure/ method: All the patients are taken with fulfilling the inclusion criteria. The patient lies on the table with the supine position and the knee flexion angle 45° with the foam pad under placed the knee. The 10x12" image receptor will be positioned on the thigh and covering the knee. The central ray will be angulated in different angles 15°, 20° 25°, shooting inferior-superior towards the front outskirts of the patella and tibial tuberosity. In the same patient, we are taking images from three different angles. And the IR read to the reader and image displayed and the evaluation will be made by blinding the radiologist and the score for the different projection will be recorded. The Final score will be tabulated according to the evaluation given by the radiologist.

RESULTS

In this study, we found that out of a total of 29 participants, 44.8% (13) were males and 55.2% (16) were females. In the current investigation, 31% (09) patients were in the age bunch (20-30) yrs., 31% (09) were in the age bunch (31-40) yrs., 20.7% (06) were in the age bunch (41-50) yrs., 13.8% (04) were in the age bunch (51-60) yrs. and 01 (3.4%) were in the age bunch (61-70) yrs. The mean age of the members was 39.21 ± 12.49 years. 20 yr. was the min. and 63 yr. was the max.

We found that in most of the patients 62.1% (18), the irregularity was distinguished with the x-beam tube angulation of 25° cranially with knee flexion of 45° followed by in 31% (09) patients with 20° angulations and in 6.9% (02) with 15° angulations individually. This examination proposed that the radiograph taken at 25° x-beam tube angulation cranially with 45° knee flexion was the progressively susceptible free perception of the Patello-femoral joint space. Amongst males, the representation of the patellofemoral joint space with x-beam tube angulation of 15° in 7.7% (01) patients, with 20° angulations in 30.8% (04) patients and with x-beam tube angulation of 25° cranially at 45° flexion in 61.5% (08) patients.

Correspondingly, amongst females, imagined the patellofemoral joint space with x-beam tube angulation of 15° in 6.25% (01) patients, with 20° angulations in 31.3% (05) patients and with x-beam tube angulation of 25° cranially at 45° flexion in 62.5% (10) patients. Present discoveries proposed that radiograph taken at 15° x-beam tube angulation cranially with 45° flexion was least delicate while radiograph taken at 25° x-beam tube angulations cranially with 45° knee flexion was unmistakably representation of Patello-femoral joint space in both male and female separately. Current findings showed that in the age gathering (20-30) yrs., (41-50) yrs., (51-60) yrs. What's more, (61-70) yrs., in the x-beam tube angulation of 25° cranially at 45° knee flexion was discovered the more successful in distinguishing the variations from the norm in joint space. Patella isn't covering with the femoral condyle and both the articular edge are seen independently the joint, femoral intercondylar indent are plainly observed the patellofemoral joint space while in the age bunch 31-40 years, x-beam tube angulation of 20° cranially at 45° flexion was discovered increasingly powerful in the perception of the patellofemoral joint space.

DISCUSSION

In this prospective clinical study, we use the many parameters for establishing the joint space of the patella-femoral done by the measurement of various x-ray tube angles. The widest percentage used of x-ray tube angulation is 25° x-ray tube angulation with 45° knee flexion in the supine position. Ahamad et al, in their clinical study they have taken the image by using skyline views. In the skyline technique, they use the 60° knee flexion and x-ray tube angulation was 19° cranially in the supine position. They have found the axial image of the patella was more accurate in skyline view. In the current study, we have taken the three x-ray tube angulations at the same knee with the 45° knee flexion in supine position. We aimed to evaluate the Better Visualization of patellofemoral joint space by using different x-ray tube angulation in the inferior –superior projection of the knee. Based on the results of our study we found by blind observation of the radiographic image to the radiologist. They have taken no measurement to the patellar region, they evaluate on the basis of anatomy of the patella, all margin of the patella. The higher percentage of the 25° x-ray tube angulation with the 45° knee flexion in the supine position the patella is not overlapping with the femoral condyle and both the articular margin are seen separately to the joint. The femoral intercondylar notch is clearly visualizing. In this current study we have taken four table

-)] According to the gender and x-ray tube angulation
-)] According frequency and x-ray tube angulation
-)] According frequency and age group wise
-)] According different x-ray tube & different age groups

In some cases, 15° x-beam tube angulation was better to visualize the patellofemoral joint space and in some cases 20° x-beam tube angulation and in some cases 25° x-ray tube angulation. But a higher percentage in 25° x-ray tube angulation is used in which better visualize the patellofemoral joint space. All margin of the patella is clearly and separated by the medial and lateral femoral condylar. Certainly it was observed that the tuberosity of the tibial bone overlapped the joint space between the patella and femur which sometimes is observed in patients with narrow joint space. In the present study, 31% (09) patients were within the age brackets of (20-30) yrs., 31% (09) were within the age brackets of (31-40) yrs., 20.7% (06) were within the age brackets of (41-50) yrs., 13.8% (04) were within the age brackets of (51-60) yrs. and 01 (3.4%) were within the age brackets (61-70) yrs. The mean age of the participants was 39.21 ± 12.49 years. And according to the higher frequency and percentage the age group is 2-30 years and (31-40) years. 20 years was min. age and 63 yr. was the max. In current study visualization the patellofemoral joint space According with different angulations in the male and female. According to the gender-wise, the 25° x-ray tube angulation leads by percentage of 62.50% female and 61.50% in males.

In line with the X-ray tube, keeping the frequency of the patient in hand. We found that in the majority of patients 62.1% (18), the abnormality was detected with the x-ray tube angulation of 25° cranially with knee flexion of 45° followed by in 31% (09) patients with 20° angulations and in 6.9% (02) with 15° angulations respectively. This study suggested that the radiograph taken at 25° x-ray tube angulation cranially with 45° knee flexion was more susceptible in the clear

visualization of Patello-femoral joint space. According to the table number 4 in the age group (20-30) yrs., (41-50) yrs., (51-60) yrs. And (61-70) yrs., the x-ray tube angulation of 25° cranially at 45° knee flexion was found the patella is not overlapping with the femoral condyle and both the articular margin are seen separately the joint, femoral intercondylar notch are clearly visualizing the patellofemoral joint space while in the age group 31-40 years, x-ray tube angulation of 20° cranially at 45° flexion was found more effective in the detection of the patellofemoral joint space.

Conclusion

This prospective clinical study confirmed that the foremost projection of in the patellofemoral joint space with skyline-view imaging approach, which uses the 25° x-ray tube angulation with the 45° knee flexion in the supine position. That delivers the most precise axial images from the patella.

REFERENCES

- St. Louis: Mosby, Merrill V. Atlas of Roentgenographic positions; 1999. 10th edition, volume 1, 333-334
2. Ross and Wilson Anatomy and physiology: 10th edition 2008 41-413
- Method G. Patrick; B, Thomas, Jr, DC, DACBR Basic Radiographic Procedures T
- A Stewart Whitley, Charles Sloane, Graham Hoadley, Adrian D Moore, Chrissie W. Alsop Clark's positioning in radiography, 12th edition ,22-23
- PR Ashalatha, G Deepa, foreword Mary Sham Bhat Anatomy & Physiology for nurses, third edition.
- Koike M, Nose H, Takagi S, Akimoto A, Kaji T. A skyline-view imaging technique for axial projection of the patella: a clinical study. Radiological physics and technology. 2015 Jul 1;8(2):174
- Davies AP, Bayer J, Owen-Johnson S, Shepstone L, Darrah C, Glasgow MM, Donell ST. The optimum knee flexion angle for skyline radiography is thirty degrees. Clinical Orthopedics and Related Research®. 2004 Jun 1; 423:166-71.
- Heng HY, Razak HR, Mitra AK. Radiographic grading of the patellofemoral joint is more accurate in the skyline compared to lateral views. Annals of translational medicine. 2015 Oct;3(18).
- Dr. Ayush Goel and Andrew murphy et al: on their study "knee (skyline laurin view)
- Satish K. Bhargava, Sumeet Bhargava fifth edition ,151; textbook of Radiology for residents & technicians
