



ISSN: 0975-833X

Available online at <http://www.journalcra.com>

INTERNATIONAL JOURNAL  
OF CURRENT RESEARCH

International Journal of Current Research  
Vol. 13, Issue, 09, pp.18920-18922, September, 2021

DOI: <https://doi.org/10.24941/ijcr.42218.09.2021>

## RESEARCH ARTICLE

# BILATERAL BUTTON CELL BATTERIES IN NOSE IN A TODDLER: A CASE REPORT

<sup>1</sup>Anshika Anand, <sup>2,\*</sup>Rupender Kumar Ranga and <sup>3</sup>Yadav, S.P.S

<sup>1</sup>Resident, JNMC, KLE Academy of Higher Education and Research, Belgaum, Karnataka,

<sup>2</sup>MS. ENT, Director, Bharat ENT & Endoscopy Hospital, Rohtak Gate- Bhiwani-127021, Haryana India

<sup>3</sup>MS. ENT, Senior Professor, Department of Otorhinolaryngology, Pt.BD Sharma Medical University- Rohtak  
124001, Haryana India

### ARTICLE INFO

#### Article History:

Received 29<sup>th</sup> June, 2021

Received in revised form

24<sup>th</sup> July, 2021

Accepted 19<sup>th</sup> August, 2021

Published online 30<sup>th</sup> September, 2021

#### Key Words:

Button cell battery,  
Nasal Endoscopy, Foreign Body

\*Corresponding author:  
Rupender Kumar Ranga

### ABSTRACT

**Background:** Foreign body in bilateral nostril is very uncommon more so the button cell battery which can lead on to septal perforation because of necrosis on both sides of septum. Authors report neglected button cell batteries in both nostrils in a toddler, which was initially tried for spontaneous expulsion by parents. **Method:** A two-year-old child presented with pain, bilateral nasal obstruction and thick discharge in the nose. After radiological investigation diagnosis was made and one button cell battery from each nostril was removed by pediatric rigid endoscopy without any complications. **Result:** The removed foreign bodies were button cells. The mucosa of septum and turbinate was ulcerated. After removal bilateral nasal cavity was irrigated with saline fortified with amikacin antibiotics. **Conclusion:** Button cells batteries should be removed cautiously to prevent slippage in nasopharynx and further in aerodigestive tract to avoid the more serious consequences down there.

Copyright © 2021. Anshika Anand et al. This is an open access article distributed under the Creative Commons Attribution License, which permits unrestricted use, distribution, and reproduction in any medium, provided the original work is properly cited.

Citation: Anshika Anand, Rupender Kumar Ranga and Yadav, S.P.S. "Bilateral Button Cell Batteries in Nose in a Toddler: A case Report", 2021. International Journal of Current Research, 13, (09), 18920-18922.

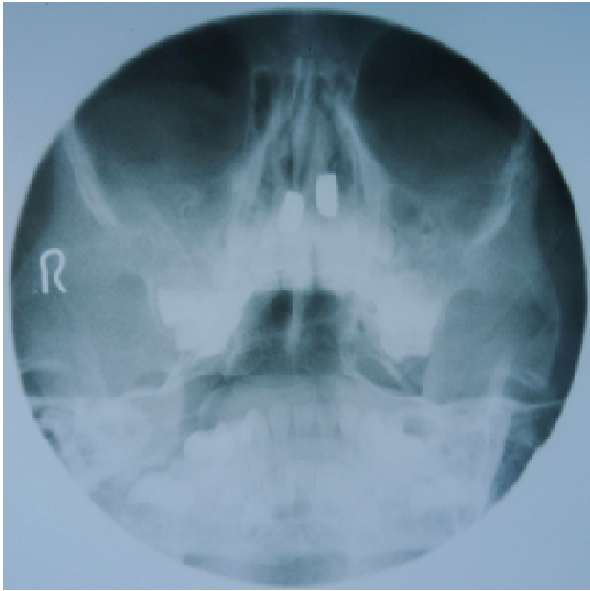
## INTRODUCTION

A button cell battery as a foreign body in unilateral nostril is not an uncommon clinical entity these days, however, such foreign bodies in bilateral nostrils are very rare and no such case has been reported in literature. Button cells have become an increasingly popular source of energy for many electronic devices like electronic games, toys, calculators, watches, cameras, hearing aids, laser pointers and so forth<sup>1</sup>. These button cells are very attractive to children who have tendency of putting them in mouth, nose and ear. Foreign body in nose, gastrointestinal tract and ear pose a great hazard to the patients and need immediate medical attention. A cell can results in extensive tissue damage by its chemical, electrical effects and by its mass effect. The long term complication of button cell in nose is necrosis, scaring, septal perforation and cosmetic deformities, which are great challenge in the management<sup>2</sup>. The incidence of such foreign body in the nostril is increasing in the last few decades especially in computer era due to increased demand of button cell in different electronic items.

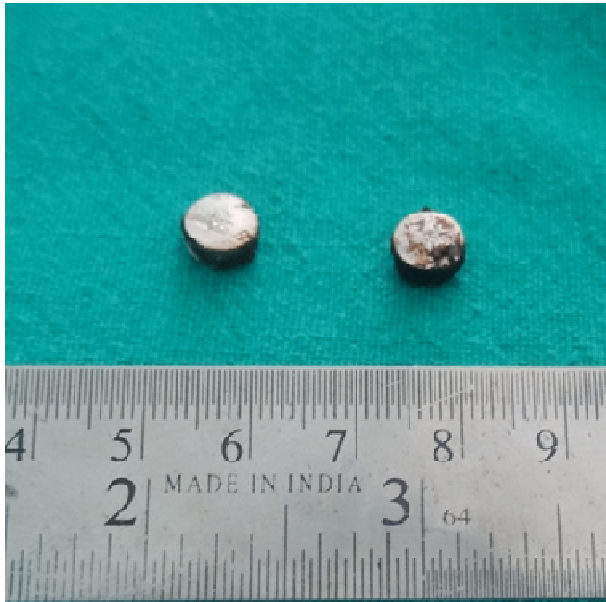We report a case of neglected button cells impacted in both nostrils diagnosed radiologically and managed endoscopically.

## CASE REPORT

A two years old male child presented with bilateral nasal obstruction, pain and thick discharge of one week duration. Clinical interrogation of the mother revealed that there was suspicion of putting something in his nostril, however, she didn't directly notice the same. An apprehensive mother performed a shot of snuff to precipitate sneezing and spontaneous expulsion of the foreign body, but in vain. Nasal obstruction and thick foul smelling discharge was the reason enough to seek ENT consultation. Anterior rhinoscopy revealed bilateral mucopurulent thick nasal discharge with mucosal edema without any noticeable nasal patency. The throat examination also showed thick discharge on posterior pharyngeal wall and small pharyngeal granules. Both tympanic membranes were congested. Systemic examination was unremarkable.



**Fig-1. X-ray PNS- Occipitomental view showing Button cells in both nasal cavity**



**Fig. 2. The foreign bodies (Button cells) after removal**

X-ray of paranasal sinuses occipito-mental view was done which revealed radiopaque shadow on both sides of nasal septum in nasal cavity. (Fig. 1). The diagnosis of metallic nasal foreign body was made and the consent for nasal endoscopy under general anesthesia was taken. The child was taken up for emergency nasal endoscopy using rigid nasal pediatric endoscope under general anesthesia. The endoscopy revealed mucopurulent discharge along with dirty brown slough which was sucked out and metallic foreign was visualized which was entrapped between the septum and inferior turbinate and removed with the help of hook and the same was repeated on other side. The removed foreign bodies were button cells (Fig-2). The mucosa of septum and turbinate was ulcerated and slough was present which was also sucked out. After removal of foreign bodies bilateral nasal cavity was irrigated with saline fortified with amikacin antibiotics. The child was put on I.V. amoxiclav for 24 hours and was discharged on oral amoxiclav and normal saline nasal drops. The child made an uneventful recovery.

## DISCUSSION

Foreign bodies in the nasal cavity of children most commonly found in the right side and most common type of foreign bodies are food, such as beans or seeds, insects or worms, grapes, pieces of sponge, erasers, small toys or pieces of toys, beads or coins, rocks or pebbles, nuts, button batteries or magnets and buttons<sup>1-3</sup>. They may be inert, hydrophilic or corrosive. Many cases of button cells in digestive tract, external auditory canal and nose are reported<sup>4</sup>. However, bilateral button cell in the nasal cavity is not reported in the literature<sup>1-3</sup>. The peak incidence is at 1-2 years that leads on to devastating tissue damage and even septal perforation in a short period of time more likely in the present case because of bilaterality of button cells. Early symptoms are nasal obstruction, rhinorrhea, pain and local injury which may cause fever, mucopurulent blood tinged discharge and facial swelling<sup>5</sup>.

Button cell size varies in diameter from 7.9-23 mm and in weight from 1-10 grams<sup>6</sup>. The diameter of cell is less than 15mm in 97% of cases. The most frequent sizes are 11.16mm in 63% and 7.9 in 30% of cases. The button cell consists of anode (+) which is made of zinc and cathode (-) made up of mercury oxide and it is separated by alkaline solution of 45% potassium hydroxide or sodium hydroxide. The leakage of electrolytes is prevented by a plastic seal, which separate the positive and negative poles. The seal is often the site of leakage. The mechanism of tissue injury by this battery may be due to spontaneous electrolyte leakage that causes liquefaction necrosis and cumulative tissue damage<sup>7</sup>. Mercury oxide after leakage causes corrosive effect on tissue. The generation of residual electric current causes electric burn. In the presence of an electrolyte solution the current produces chlorine gas and sodium hydroxide which results in formation of precipitate. The impacted foreign body like button cell causes pressure necrosis also. The clinical course of button cell foreign body in the form of nasal mucosal injuries and tissue destruction depends on several factors like the location, duration of mucosal exposure, remaining voltage in the battery, and chemical composition of the battery<sup>7</sup>. Button cell if removed early leaves less damage. The longer stay in the nasal cavity causes necrosis of nasal mucosa, scarring, septal perforation, nasal synechiae, facial cellulitis and nasal stenosis<sup>1</sup>. The differential diagnosis includes choanal atresia, polyps, sinonasal tumours, sinusitis, foreign body and rarely nasal diphtheria. In our case bilateral nasal obstruction with thick mucopurulent discharge was present due to close contact of cell on mucosa of longer duration i.e. 7 days. However, on removal no perforation of the septum was observed except erosion and edema in inferior turbinate and septal mucosa. It was caused by chemical content of battery and defused power of the cell. It is still unknown on how much time of stay is necessary for the battery to cause septal perforation. However, septal perforation may occur after a short period of 8 - 48 hours if there is sufficiently charged battery i.e. new cell which act as a primary factor for septal perforation<sup>8</sup>. Immediate removal of button cells foreign body in the nasal cavity is necessary for prevention of severe local tissue injury and it is important to assess the degree of injury<sup>9</sup>. Further, nasal drops shouldn't be instilled as it enhances tissue damage because of its facilitating effect as passage of the current. The removal of battery cell in the nasal cavity is carried out under local or general anesthesia and it is important not to cause any damage to nasal mucosa.

Further, it is important that the button cell doesn't slip in the nasopharynx, where it can go to oesophagus and cause damage. After removal of foreign body from the nasal cavity sufficient irrigation with sterile saline fortified with antibiotic solution was done to minimize secondary infection and to prevent synechia formation. To manage such cases a prompt diagnosis and careful removal is required which prevent further complications.

### Conclusion

We stress on the role of awareness of parents and general practitioner may play an important role in early detection and referral to prevent complications. Education based prevention is ideal, with increased education of parents on age appropriate food and household objects and strict industry standard for toy part size and safe containers.

**Conflict of interest-** All authors declare that they have no conflict of interest.

**Source of funding-** No

### REFERENCES

1. Lee HM, Kim DH, Kim JM, Hwang SJ, Lee H. 2001. Nasal septal perforation due to battery. *J Rhinol.*, 8: 69-72.
2. Kalan A, Tariq M. 2000. Foreign bodies in the nasal cavities: a comprehensive review of the aetiology, diagnostic pointers and therapeutic measure. *Postgrad Med J.*, 76: 484-7.
3. Tong MC, Ying SY, van Hasselt CA. 1996. Nasal foreign bodies in children. *Int J Pediatr Otorhinolaryngol.*, 35: 207-11.
4. Sri Herawati JPB. 2004. Impacted button battery in the nasal cavity. *Folia Media Indonesia.*, 40: 139-42.
5. Gomes CC, Sakano E, Lucchelzi MC, Patro PR. 1994. Button battery as foreign body in the nasal cavities, special aspects. *Rhinology.* 32: 98-100.
6. Shinner DW, Chui P. 1980. The hazard of button-sized batteries as foreign bodies in nose and ear. *J Laryngol Otol.*, 100:1315-8.
7. Kavanagh KT, Litovitz T. 1986. Miniature battery foreign body in auditory and nasal cavity. *J Am Med Assoc.*, 255: 1470-2.
8. Hong D, Chu YF, Tong KM, Hsiao CJ. 1987. Button batteries as foreign bodies in the nasal cavities. *Int J Pediatr Otorhinolaryngol.*, 14: 15-9.
9. Bhatia J, Singhal SK, Dass A. 2010. Button cell causing septal perforation in a child. *ClinRhinol: An Int J.*, 3: 161-3.

\*\*\*\*\*