



ISSN: 0975-833X

Available online at <http://www.journalcra.com>

INTERNATIONAL JOURNAL
OF CURRENT RESEARCH

International Journal of Current Research
Vol. 14, Issue, 01, pp.20554-20555, January, 2022

DOI: <https://doi.org/10.24941/ijcr.43025.01.2022>

RESEARCH ARTICLE

VEIN OF GALEN ANEURYSMAL MALFORMATION (VGAM)- ANAESTHETIC MANAGEMENT IN AN INFANT FOR EMBOLIZATION

*Dr. Rashmi Gujuran, Dr. Vidhya Deshmukh, Dr. Aarti Kolte and Dr. Hemant Mehta

Sir HN Reliance Foundation Hospital and Research Centre, Girgaon, Mumbai

ARTICLE INFO

Article History:

Received 14th October, 2021
Received in revised form
29th November, 2021
Accepted 18th December, 2021
Published online 31st January, 2022

Keywords:

Vein of Galen Malformation,
VGAM, Embolization.

*Corresponding author:

Dr. Rashmi Gujuran

ABSTRACT

Vein of Galen aneurysmal malformation (VGAM) is a rare congenital anomaly of intracranial circulation that occurs before birth. It's a malformation where blood drains from cerebral arteries to a dilated vein of Galen. It commonly results in high-output congestive heart failure. It may also present with neurological symptoms like seizures, hydrocephalus and developmental delay. Early staged embolization of feeding vessels to shut off the shunt can improve survival rates in these patients. We present the case of a three months old boy with vein of Galen malformation for embolization.

Copyright © 2022. Rashmi Gujuran et al. This is an open access article distributed under the Creative Commons Attribution License, which permits unrestricted use, distribution, and reproduction in any medium, provided the original work is properly cited.

Citation: Dr. Rashmi Gujuran, Dr. Vidhya Deshmukh, Dr. Aarti Kolte and Dr. Hemant Mehta. "Vein of Galen Aneurysmal Malformation (VGAM)- Anaesthetic management in an infant for embolization.", 2022. *International Journal of Current Research*, 14, (01), 20554-20555.

INTRODUCTION

Vein of Galen aneurysmal malformation (VGAM) is a rare congenital anomaly of intracranial circulation wherein blood drains from cerebral arteries to a dilated vein of Galen. It commonly results in high-output congestive heart failure. Early staged embolization of feeding vessels to shut off the shunt can improve survival rates in these patients.¹

CASE REPORT

A three months old, 4.3 kilograms male child, diagnosed with VGAM, was posted for cerebral digital subtraction angiography (DSA) and embolization. Antenatally diagnosed with VGAM, baby was treated in neonatal intensive care unit (NICU) for increased pulmonary pressures and congestive cardiac failure with milrinone, sildenafil, digoxin, furosemide and oxygen supplementation. Conservative management was planned till four months of age and then embolization. Due to increase in cardiac size with respiratory distress at 6 weeks follow up, early embolization was decided. Echocardiography showed patent foramen ovale (PFO) and tiny patent ductus arteriosus (PDA) with left to right shunt, dilated left atrium and left ventricle, with normal ventricular function. Patient was continued on furosemide, digoxin and sildenafil.

Baby was hemodynamically stable with baseline saturation of 96% on room air. His hemoglobin was 11.2g/dl with normal creatinine and serum electrolytes. Routine general anaesthesia with intubation was performed, ultrasound guided right IJV was cannulated. For maintenance, propofol infusion, vecuronium boluses and 0.8 MAC sevoflurane were used. During two and a half hours procedure, total intake included 45 ml of 1.25% Dextrose RL, 30ml dye with 50 ml urine after furosemide bolus and 15ml blood loss. Body temperature was monitored throughout the procedure and maintained with warm air blowers and padding of the limbs. Three feeders were embolized, Venous outflow was kept open. (Figure 1). Post-procedure baby was shifted to ICU on mechanical ventilation, extubated three hours later, shifted to the ward next day and discharged after two days. Patient underwent three more embolization procedures till 22 months age.

DISCUSSION

At birth, when placenta separates, up to 70% of cardiac output is directed to VGAM's low resistance arteriovenous shunt. This results in large flow venous return to right heart eventually causing pulmonary hypertension and right ventricle failure. There may be other associated congenital cardiac

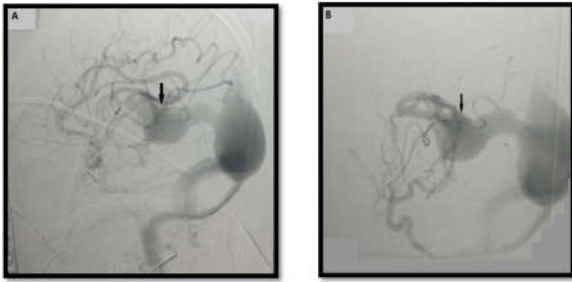


Figure 1. FLUOROSCOPIC IMAGE OF VGAM BEFORE EMBOLISATION (A) AND AFTER EMBOLISATION (B) The arrow mark points towards VGAM

anomalies. VGAM can cause raised venous sinus pressure leading to edematous brain parenchyma with reduced oxygen supply, cerebral ischemic changes, subependymal atrophy and melting brain syndrome. Increased venous pressure can also reduce CSF outflow causing hydrocephalus. Neurological impairment may also result from mass effects of malformation. Hemorrhage is rare. Systemic hypoperfusion can cause renal and hepatic dysfunction. Anemia, resulting from poor intake and vomiting due to hydrocephalus, further reduces oxygen supply to the brain and adds to the hyperdynamic circulation.² Transcatheter embolization is the procedure of choice to occlude VGAM. It is less invasive with a higher survival rate. Initial management of VGAM is usually conservative with medical management of cardiac failure upto five months of age as earlier embolization in neonates carries high risk and is technically more difficult. However, worsening of symptoms like cardiac failure, seizures may need early embolization. Surgery for shunt closure carries high mortality and morbidity and has little role.³ The main concern with anaesthetic management of these patients is the risk of complications such as congestive cardiac failure and cerebral infarction periprocedure. Patients with hydrocephalus or macrocephaly secondary to VGAM may present with difficult airway.²

Difficult intravenous cannulation, invasive hemodynamic monitoring is seen with large shunts. Inhalational uptake is reduced in these patients due to intracardiac shunts and intracranial shunt and may have to be supplemented with intravenous anaesthetic agents. Sodium nitroprusside (SNP) can be used to manage hypertension. It also improves pulmonary circulation, reduces systemic vascular resistance and increases cardiac output. Fluid administration should be closely monitored including contrast medium and flush solutions used during the procedure. The duration of procedure may be restricted due to risk of fluid overload. Urine output may be influenced by use of diuretics, osmotic agents including contrast agents and cold environment. Hypothermia is another concern in cold radiology suite. A higher PaO₂ (100–250 mmHg) and transfusion trigger (10 g/dl) is required to ensure adequate brain and peripheral tissue oxygenation. There may be sudden transient increase in intracranial pressure with bradycardia during embolization of large shunts. Embolization procedure can lead to intracerebral hemorrhage due to venous hypertension. Therefore staging the embolization procedure may help to avoid this. If perforation of the venous sac occurs, reversal of anticoagulation usually helps. Echocardiographic evaluation with attention to the aortic arch and pulmonary veins is important as coexisting cardiac anomalies have a major effect in the management and outcome of these patients. Fatal complications such as paradoxical embolization have been reported.

An intracardiac shunt lesion associated with cerebral arteriovenous malformation can lead to a high volume of systemic venous return and a large right to left shunt.⁴ Another concern is pulmonary embolization with embolic agents due to the high flow across the intracranial shunt that drains immediately into the central venous system. Staging of endovascular transarterial embolization is usually required as total embolization of a large shunt in a single sitting can cause rapid deterioration of both cardiac and neurological status due to the sudden removal of a high flow shunt from the circulation. Therefore partial embolization to improve heart failure is usually aimed for.

For neonates in heart failure, with transcatheter embolization procedures, the mortality rate can be as high as 50% and even higher with associated pulmonary hypertension. Postembolization closure of conduits can cause hyperperfusion, cerebral edema and venous infarcts in the post-procedure phase. Hypertension should be avoided especially in first 48 hours post-procedure to prevent worsening of neurological injury. SNP infusion is preferred for hypertension. Intracranial hemorrhage, cerebral venous thrombosis and worsening of the hydrocephalus may also occur after the procedure. Closure of conduits can also increase afterload, straining the heart further. This can be managed with milrinone.²

CONCLUSION

VGAM is a rare condition and embolization procedure is done at selected well equipped centers with adequate resources and expertise. There are multiple concerns pertaining to anaesthetic management of these patients like risk of cardiac failure, pulmonary edema, neurological complications, difficult airway, paediatric age group and fluid management. Intensive monitoring with or without ventilator support is essential after the procedure as well.

REFERENCES

1. Ashley Smith. Vein of Galen Malformation and High-output Cardiac Failure. *Anesthesiology*.2016 Sep;125(3):597. doi: 10.1097/ALN.0000000000001095.
2. Hrish AP, Lionel KR. Periprocedural management of vein of Galen aneurysmal malformation patients: an 11 year experience. *anesth essays res*. 2017;11(3):630-635.
3. BhattacharyaJJ,ThammarojJ, Vein of Galen Malformations. *Journal of Neurology, Neurosurgery & Psychiatry*2003;74:i42-i44.
4. McElhinney DB, Halbach VV, Silverman NH, Dowd CF, Hanley FL. Congenital cardiac anomalies with vein of Galen malformations in infants.*Arch Dis Child*. 1998;78(6):548-551. doi:10.1136/adc.78.6.548