



ISSN: 0975-833X

Available online at <http://www.journalcra.com>

INTERNATIONAL JOURNAL
OF CURRENT RESEARCH

International Journal of Current Research
Vol. 14, Issue, 04, pp.21186-21189, April, 2022

DOI: <https://doi.org/10.24941/ijcr.43335.04.2022>

RESEARCH ARTICLE

CASE REPORT OF MANAGEMENT OF MANDIBULAR ANTERIOR WITH 2 ROOT CANALS: AN ENDODONTIC CHALLENGE

*Dr. Shreya Dadhich, Dr. Harshit Srivastava, Dr. Deepak Raisingani, Dr. Ridhima Gupta,
Dr. Vaishali Moryani

India

ARTICLE INFO

Article History:

Received 14th January, 2022

Received in revised form

06th February, 2022

Accepted 20th March, 2022

Published online 28th April, 2022

Keywords:

Tooth root, Endodontics,
Disinfection, Mandible
Incisors, Anatomical Variations.

*Corresponding author:

Dr. Shreya Dadhich

ABSTRACT

Awareness of anatomy and variations in the configuration of a root canal is essential to ensure successful endodontic treatment. Mandibular incisors generally demonstrate the presence of one root with one canal. But in some cases, they depict anatomic variation in terms of the number of root canals wherein an additional root canal might be present lingually. Appropriate diagnosis of such anatomic variation is key to success for root canal therapy. This case report describes endodontic management of a mandibular lateral incisor with 2 root canals exhibiting Vertucci Type 2 configuration. Identification of this variation was done thorough clinical examination along with the aid of multiangled radiographs, and an accurate assessment of this morphology was made with the help of cone-beam computed tomography imaging.

Copyright © 2022. Shreya Dadhich et al. This is an open access article distributed under the Creative Commons Attribution License, which permits unrestricted use, distribution, and reproduction in any medium, provided the original work is properly cited.

Citation: Dr. Shreya Dadhich, Dr. Harshit Srivastava, Dr. Deepak Raisingani, Dr. Ridhima Gupta, Dr. Vaishali Moryani. "Case report of management of mandibular anterior with 2 root canals: an endodontic challenge", 2022. *International Journal of Current Research*, 14, (04), 21186-21189.

INTRODUCTION

A thorough mechanical debridement followed by 3-D obturation with bacteria impervious seal are prerequisites for successful endodontic treatment. Missed canals are the source of remnant pulp tissue which contribute towards persistent pain and endodontic pathosis in patients leading to endodontic failure. Root canals are often left untreated due to operators' inability to identify them.¹ Earlier it was believed that permanent mandibular incisors are associated with a single root along with a single root canal. However, studies in past revealed high variation in root canal morphology of mandibular incisors due to the presence of the second canal, lateral canal and apical deltas^{2,3,4,5,6,7}. Mandibular incisors though are not frequently involved in caries but there are situations where they require endodontic treatment. Lack of identification of such anatomical variations or additional canals may lead to endodontic treatment failure. Therefore, for endodontic treatment to be successful, a dentist must have comprehensive knowledge regarding the canal configuration of the tooth and its possible variations.⁶

Case Report

A 29-year-old male patient reported to the Department of Conservative Dentistry & Endodontics of Mahatma Gandhi Dental College and Hospital, Jaipur with a Chief complaint of pain in the lower front tooth region in the past 4-5 days. The pain was continuous, severe and it lingered for several minutes even after removal of the stimulus and led to disturbed sleep. The medical history was irrelevant. On oral examination, tooth 32 was Tender on percussion and severely attrited with grade 1 mobility and teeth 31, 41 were Root Canal Treated. Radiographic examination revealed periapical radiolucency associated with 32 (Fig 1). The tooth was diagnosed with Pulp necrosis with chronic periapical abscess. Hence root canal therapy in relation to 32 was the decided treatment plan. Access cavity preparation was done under a rubber dam with an endo access bur of 32 and widened buccolingually and extended into cingulum gingivally, which revealed the presence of the lingual canal (Fig 2). The patency was checked using no. 10 k file and even working length was also using the same (Fig 3).

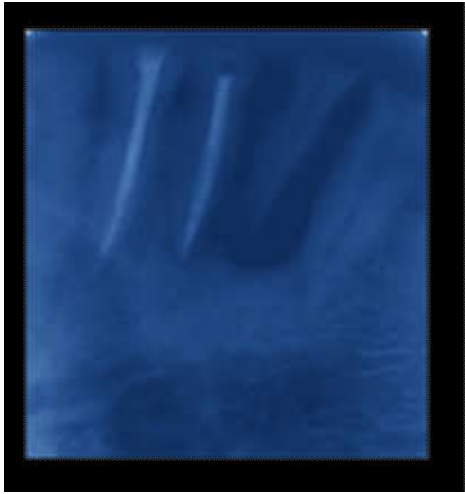


Fig 1



Fig 2

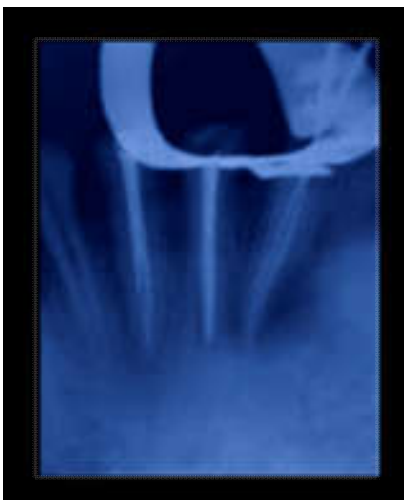

Fig 3

The presence of 2 canals was confirmed by taking radiographs using different angulations. Copious irrigation with normal saline and 17% EDTA was used between each file throughout the procedure. Biomechanical preparation was carried out using rotary instruments till 25-4% in both the canals.

After cleaning and shaping were performed an intracanal calcium hydroxide medicament was given for 1 week. During the next visit after a week, the tooth was asymptomatic and obturation was done using the lateral condensation technique (Fig 4,5).

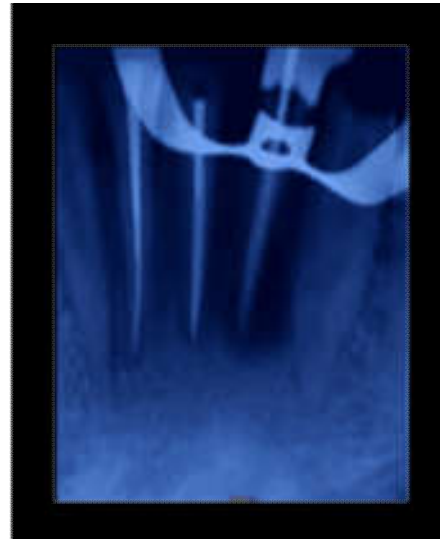

Fig 4

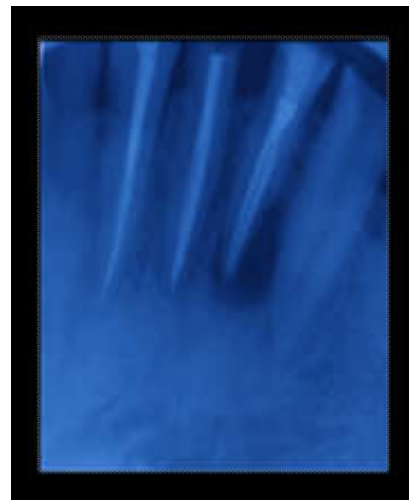

Fig 5

At a review appointment 3 and 6 months later, the patient reported no complaints and there were no clinical or radiographic signs of periapical inflammation (Fig 6,7).

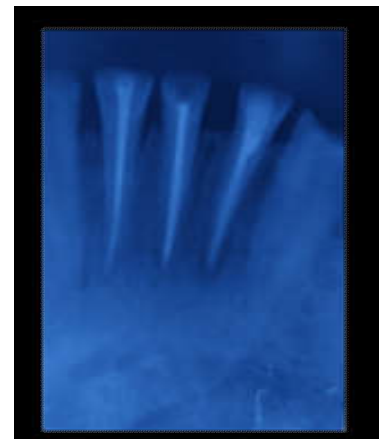

Fig 6

Incidence of 2 canals in a mandibular in cisors-A survey of available studies

Population	Author (Year)	Evaluation Method	Teeth Studied	Canal Configuration according to prevalence								
				I	II	III	IV	V	VI	VII	VIII	OTHERS
Unknown	Benjamin & Dawson (1974)	In vitro (periapical radiographs)	Mandibular central incisor	58.6	40.1	0	1.3	0	0	0	0	0
Turkish	Kartal & Yani Turkoglu (1992)	In vitro (Staining and Clearing)	Mandibular central incisor	55	16	20	4	3	0	0	0	2
Indian	Sikri&Sikri (1994)	In vitro (periapical radiographs)	Mandibular central incisor	58.3	12.5	4.16	0	20.8	0	0	0	4.16
			Mandibular lateral incisor	59.7	8	4.34	3.26	26.1	0	0	0	6.52
	Boruah&Bhuyan (2010)	In vitro (Staining and Clearing)	Mandibular Incisors	63.7	7.08	22.9	6.25	0	0	0	0	0
	Jaju <i>et al.</i> (2013)	In -vivo (CBCT)	Mandibular central incisor	54.6	6.9	38.4	0	0	0	0	0	0
			Mandibular lateral incisor	52.3	5.8	49.5	0	0	0	0	0	0
	Kamtane & Ghodke (2015)	In -vivo (CBCT)	Mandibular central incisor	64.7	23.5	8.82	2.94	0	0	0	0	0
			Mandibular lateral incisor	64.7	23.5	8.82	2.94	0	0	0	0	0
	Dhaimade <i>et al.</i> (2017)	In -vivo (CBCT)	Mandibular central incisor	57	12	24	4	0	0	0	0	3
Mandibular lateral incisor			54	15	27	2	0	0	0	0	2	
Chinese	Shu-fen <i>et al.</i> (2007)	In vitro (periapical radiographs)	Mandibular central incisor	77.7	1.96	1.43	3.27	2.61	0	0	0	0
	Ying <i>et al.</i> (2014)	In -vivo (CBCT)	Mandibular central incisor	93.3	0	5.68	0	1.02	0	0	0	0
			Mandibular lateral incisor	82.5	0	15.5	0	1.8	0	0.06	0	0

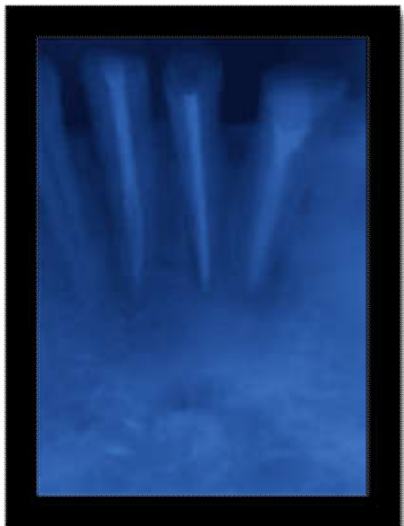

Fig 7

DISCUSSION

Mandibular incisors are generally assumed to be associated with a single root and a single canal. However, literature shows that they might exhibit complicated configurations that may further vary with ethnicity and race.¹

Clinical Significance: The main reason associated with the failed endodontic treatment of mandibular incisors is missed 2nd lingual canal due to inadequate access opening which leads to persistence of lingual shelf over lingual canal thereby preventing its treatment.¹ This case report depicted the presence of 2 canals in mandibular lateral incisors exhibiting Vertucci Type 2 Configuration. This configuration is of clinical importance as is associated with high failure rates because of the following reasons: First, since canals show merging in apical 3rd of the root, most clinicians perceive this as treating a single canal is sufficient to assure adequate apical seal.

But this is not the case as when only one canal is treated, remnant necrotic tissue of the second canal at apical 3rd can liberate noxious by-products through a lateral or accessory canal directly into the periodontal ligament space. Second, if the root canal filling in the one treated canal is short of the merging point in apical 3rd, it will provide a pathway for the second canal to communicate with periapical tissues directly via the apical foramen. ¹

Conclusion

This case report highlights that inability to detect and debride the second lingual canal in mandibular incisors could be a major reason contributing towards endodontic failure. Due to the high incidence of 2 canals in mandibular incisors, it is imperative for clinicians to always suspect and make every effort to search for 2nd canal by proper access preparation, careful interpretation of radiographs taken at different angulations, use of magnifying loupes.

REFERENCES

1. Ajinkya MP, et al. An In-Vitro Cone-Beam Computed Tomographic Evaluation of Root Canal Anatomy of Permanent Mandibular Incisor Teeth in an Indian Population. Clin Radiol Imaging J 2017, 1(2): 000108.
2. Kaffe I, Kaufman A, Littner MM, Lazarson A. Radiographic study of the root canal system of mandibular anterior teeth. Int Endod J 1985;18:253-9.
3. Benjamin KA, Dowson J. Incidence of two root canals in human mandibular incisor teeth. Oral Surg Oral Med Oral Pathol 1974;38:122-6.
4. Kartal N, Yanikoglu FC. Root canal morphology of mandibular incisors. J Endod 1992;18:562-4.

5. Rankine-Wilson RW, Henry P. The Bifurcated Root Canal in Lower Anterior Teeth. *J Am Dent Assoc* 1965;70:1162-5.
6. Rahimi S, Milani AS, Shahi S, Sergiz Y, Nezafati S, Lotfi M. Prevalence of two root canals in human mandibular anterior teeth in an Iranian population. *Indian J Dent Res* 2013;24:234- 236
7. Verma, G. R., Bhadage, C., Bhoosreddy, A. R., Vedpathak, P. R., Mehrotra, G. P., Nerkar, A. C.,Chaubey, S. 2017. *Cone Beam Computed Tomography Study of Root Canal Morphology of Permanent Mandibular Incisors in Indian Subpopulation. Polish Journal of Radiology, 82, 371–375.*
