



ISSN: 0975-833X

Available online at <http://www.journalcra.com>

INTERNATIONAL JOURNAL  
OF CURRENT RESEARCH

International Journal of Current Research  
Vol. 14, Issue, 04, pp.21334-21338, April, 2022

DOI: <https://doi.org/10.24941/ijcr.43415.04.2022>

## RESEARCH ARTICLE

# THE APPLICABILITY OF VERTUCCIS CLASSIFICATION ON PRIMARY MANDIBULAR SECOND MOLARS- A RETROSPECTIVE CBCT PILOT STUDY

<sup>1</sup>Dr. Navin Hadadi Krishnamurthy, <sup>2</sup>Dr. Arya Radhakrishnan, <sup>3</sup>Dr Umapathy Thimmegowda and <sup>4</sup>Dr Nagarathna C.

<sup>1</sup>MDS, Professor, Department of Pediatric and Preventive Dentistry, Rajarajeswari Dental College and Hospital, Bangalore, India.

<sup>2</sup>Post graduate student, Department of Pediatric and Preventive Dentistry, Rajarajeswari Dental college and Hospital, Bangalore, India.

<sup>3</sup>MDS, Professor, Department of Pediatric and Preventive Dentistry, Rajarajeswari Dental College and Hospital, Bangalore, India.

<sup>4</sup>MDS, Professor and Head of the Department of Pediatric and Preventive Dentistry, Rajarajeswari Dental College and Hospital, Bangalore, India.

### ARTICLE INFO

#### Article History:

Received 19<sup>th</sup> January, 2022

Received in revised form

16<sup>th</sup> February, 2022

Accepted 29<sup>th</sup> March, 2022

Published online 30<sup>th</sup> April, 2022

#### Key words:

Root Canal Morphology, Primary Mandibular Second Molar, Cone Beam Computed Tomography, Vertuccis Classification.

#### \*Corresponding Author:

Navin Hadadi Krishnamurthy

### ABSTRACT

**Introduction:** A detailed knowledge of root canal morphology and comprehensive understanding of different root canal configurations are needed to avoid any failures or retreatments and also to improve the success of endodontic treatments of primary teeth. Inability to identify the root canals is generally found as the major cause of failure of root canal treatment. The classification of root canal morphology of permanent teeth was given by Vertucci (1984). However, after a detailed search in the literature, very few results were obtained which classified Primary mandibular second molars using Vertuccis classification. **Aim:** To investigate the root and canal morphology of primary mandibular second molars (PMSMs) using cone beam computed tomography (CBCT) by applying Vertuccis classification in Pediatric Indian population. **Materials and Methods:** CBCT images of 15 children (30 images) belonging to the age group of 5-8 years were obtained from the institutional database. The CBCT images were reconstructed by using On-Demand software, evaluated and the data was analyzed using SPSS version for windows. **Results:** All the primary mandibular second molars had two separate roots. In the mesial root, two root canals were observed in 86.7% of the cases and a single canal was seen in 13.3% of cases, whereas in the distal root, a single root canal was seen in 76.7% of cases and two canals were seen in 23.3% of the cases. Vertuccis Type IV configuration was most common in the mesial roots followed by Type I and Vertuccis Type I configuration was most common in the distal roots followed by Type IV. **Conclusion:** Within the limitations of this study, the results of the present study showed different root canal configurations in both mesial and distal roots of primary mandibular second molars in the studied patients of the Pediatric Indian population.

Copyright©2022, Navin Hadadi Krishnamurthy et al. This is an open access article distributed under the Creative Commons Attribution License, which permits unrestricted use, distribution, and reproduction in any medium, provided the original work is properly cited.

Citation: Dr. Navin Hadadi Krishnamurthy, Dr. Arya Radhakrishnan, Dr Umapathy Thimmegowda and Dr. Nagarathna C. 2022. "The applicability of vertuccis classification on primary mandibular second molars- a retrospective cbct pilot study", *International Journal of Current Research*, 14 (04), 21334-21338

## INTRODUCTION

The maintenance of primary teeth in the dental arch is the first aim of a pediatric dentist when the pulp tissue is irreversibly inflamed or nonvital, and the common necessary procedure usually done is the root canal treatment.<sup>1</sup> Since, primary teeth show peculiar internal geometry of the root and canal system, such as connections involving furcations and horizontal anastomoses, endodontic treatment of primary teeth involving cleaning, shaping and obturation of the root canal system is considered to be highly complicated.<sup>2,3</sup>

To improve the success of endodontics in primary molars, more detailed knowledge of root and canal number and morphology is needed.<sup>1,2</sup> The primary mandibular second molars showed extensive variation and complexities in their internal anatomy. A thorough knowledge of the complexity of the root canal system is essential for understanding the principles and problems of shaping and cleaning, determining the apical limits and dimensions of canal preparations, and for performing successful endodontic procedures.<sup>4</sup> Knowledge of unfamiliar variations are important as a non-treatment of one additional root or root canal can lead to failure of root canal procedures.<sup>5</sup>

The methods most commonly used in analysing the root canal morphology are canal staining and tooth clearing, conventional radiographs, digital and contrast medium-enhanced radiographic techniques, radiographic assessment enhanced with contrast media, and more recently computed tomographic techniques.<sup>1,3,7</sup> Moreover, in recent years, Cone Beam Computed Tomography (CBCT) has become popular in clinical dental practice for diagnosis in the oral and maxillofacial region, and this technique enables more detailed evaluation by reconstruction of 3-D images.<sup>1</sup>

As an emerging technology in endodontics, CBCT has a lower radiation dose and a higher resolution than traditional computed tomography scans.<sup>2</sup> CBCT, potentially provides the clinician with the ability to observe an area in three different planes using a practical tool for non-invasive and 3-dimensional (3D) reconstruction imaging for use in endodontic applications and morphological analysis. The combination of sagittal, coronal and axial CBCT images eliminates the superimposition of anatomic structures.<sup>8</sup> Although many studies, have clearly indicated that CBCT is helpful in the evaluation of the root and canal system, CBCT cannot be routinely used in all cases of nonsurgical endodontic treatment as overexposure to radiation is a risk. Until further evidence is available, CBCT should be considered only when it has been identified that conventional radiographic techniques are yielding limited information and that further details are needed for diagnosis and planning treatment, while ensuring that the patient's radiation exposure is kept as low as possible.<sup>2</sup> Hence, the present study was undertaken to assess the variation in number and morphology of the root canals of primary mandibular second molars using CBCT and to study the applicability of Vertucci's Classification in assessing the root canal morphology.

## MATERIALS AND METHODS

This present retrospective study was carried out on thirty CBCT images of primary mandibular second molars of children aged between 5 to 8 years obtained from the institutional database of Rajarajeswari dental college, Bangalore. The particular age group was chosen because more than half the root length is formed and extensive caries exposure has been observed in primary mandibular second molars in children and is in need for endodontic treatment. So a proper knowledge of the root canal anatomy is important. The CBCT images that were taken for various valid diagnostic reasons were collected and analysed for the number of roots, number of root canals per root and root canal variations in morphology. The teeth which require endodontic treatment with or without periapical lesions, no congenital or developmental anomalies were included in the study and teeth involving multi-surface carious lesion, restored or fractured teeth and teeth with bone loss were excluded. The sample size was estimated using the formula  $N = Z^2 (1-\delta) \frac{PQ}{\delta^2}$  where  $Z (1-\delta) = 1.96$ ,  $P=0.50$ ,  $Q=1-P$ ,  $\delta$  (Margin of Error)  $=0.15/\delta^2$ . The study data was analyzed using SPSS [Statistical Package for Social Science] v.22 [IBM, Corp.,] for Windows. The level of significance was set at  $P < 0.05$ .

The ethical clearance was obtained from the institutional ethical and research committee prior to the commencement of the study.

**RADIOGRAPHIC TECHNIQUES:** The CBCT images were taken by an ON-DEMAND® 3D machine at 90 kV and 12.5 mA, with a field of view of 60 mm and a voxel size of 0.1 mm. The slice thickness was 1 mm and the exposure time was kept as 15 seconds. Scans were taken according to the manufacturer's recommended protocol and all of the images were taken with the help of a licensed radiologist, with the minimum exposure necessary for adequate image quality. The lowest possible radiation dose and field were guaranteed.

**EVALUATION OF THE IMAGE:** The coronal and axial section of 30 CBCT image were reconstructed and analyzed with the help of ON DEMAND 3D and SCANORA software. (CBCT MACHINE: SCANORA 3D, SOREDEX, FINLAND). The brightness and contrast of the images were adjusted using image processing tool of the software to ensure optimal visualization. The images were evaluated for number of root, number of canals per root in the axial section and root canal variations in the coronal section at the cemento-enamel junction. The evaluation criteria of images were based on the Vertucci's classification.

## VERTUCCI'S CLASSIFICATION

**TYPE I:** A single canal extends from the pulp chamber to the apex (1).

**TYPE II:** Two separate canals leave the pulp chamber and join short of the apex to form one canal (2-1).

**TYPE III:** One canal leaves the pulp chamber and divides into two in the root; the two then merge to exit as one canal (1-2-1).

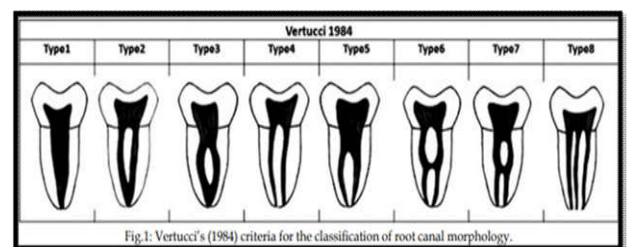
**TYPE IV:** Two separate, distinct canals extend from the pulp chamber to the apex (2).

**TYPE V:** One canal leaves the pulp chamber and divides short of the apex into two separate, distinct canals with separate apical foramina (1-2).

**TYPE VI:** Two separate canals leave the pulp chamber, merge in the body of the root, and redivide short of the apex to exit as two distinct canals (2-1-2).

**TYPE VII:** One canal leaves the pulp chamber, divides and then re-joins in the body of the root, and finally redivides into two distinct canals short of the apex (1-2-1-2).

**TYPE VIII:** Three separate, distinct canals extend from the pulp chamber to the apex (3). (Fig.1).



**Fig. 1. Vertucci's classification - Image for evaluation**  
The two Vertucci types noted in this study are: Vertucci Type I, and Type IV (Fig. 2).

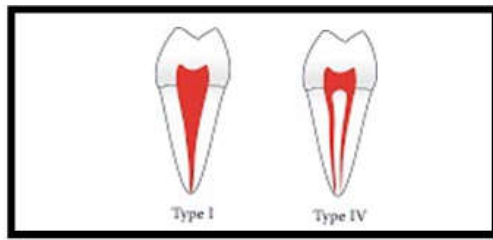


Fig. 2. Vertuccis types noted in this study

**STATISTICAL ANALYSIS:** The study data was analyzed using SPSS version 22.0 [IBM, Corp.,] for Windows. The experimental data obtained in this paper were presented as categorical variables. The frequency of the numbers of root and canals were determined and were compared by the Chi-square test, with a significance level of  $p < 0.05$ .

## RESULTS

Table 1. Age and gender distribution among study subjects

Variable	Category	N	%
Age	5 years	1	6.7%
	7 years	3	20.0%
	8 years	11	73.3%
Sex	Males	10	66.7%
	Females	5	33.3%

Table 2. Distribution of no. of root canals in primary mandibular second molars among study subjects

Variable	Category	N	%
Mesial	1 Canals	4	13.3%
	2 Canals	26	86.7%
Distal	1 Canals	23	76.7%
	2 Canals	7	23.3%

CBCT images of thirty primary mandibular second molars were examined. The age group included in the study was 5-8 years of which  $n=1$  belong to 5 years and  $n=3$  belong to 7 years and  $n=11$  belong to 8 years and also  $n=10$  were males and  $n=5$  were females. (Table I). All the primary mandibular second molars had two separate roots. In the mesial root, two root canals were observed in 86.7% of the cases and a single canal was seen in 13.3% of cases, whereas in the distal root, a single root canal was seen in 76.7% of cases and two canals were observed in 23.3% of the cases. (Table II).

The following root canal variants were seen in this study ( $N=30$ )

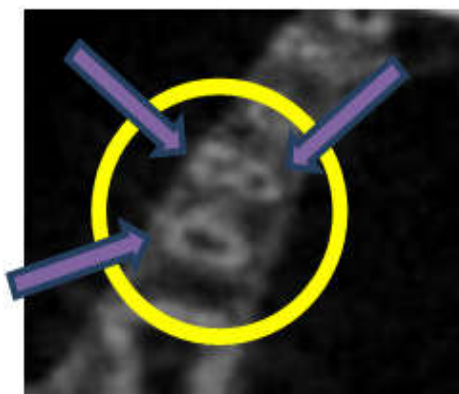


Figure 3. Two mesial canals and one distal canal ( $N=19$  (63.3%))

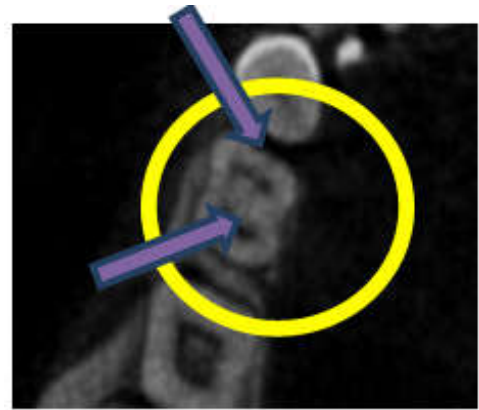


Figure 4. Single mesial and distal canal ( $N=4$  (13.3%))

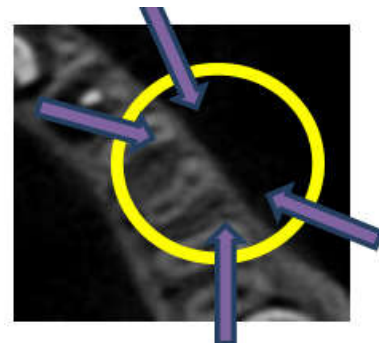


Figure 5. Two mesial canals and two distal canals ( $N=7$  (23.3%))

Table 3. Classification of root canal morphology in primary mandibular second molar using Vertuccis criteria

Variable	Category	N	%
Mesial	Type I	4	13.3%
	Type IV	26	86.7%
Distal	Type I	23	76.7%
	Type IV	7	23.3%
Total	Type I	27	45%
	Type IV	33	55%

The canal configurations of the primary mandibular second molar roots according to Vertuccis criteria have been given in Table III. Vertuccis Type IV configuration was most common in the mesial roots followed by Type I and Vertuccis Type I configuration was most common in the distal roots followed by Type IV. The most commonly observed root canal type, which was observed in 60 roots (both mesial and distal) was Type IV (55%) followed by Type I (45%).

Table IV: Comparison of Root canal Morphology based on the Mesial & Distal canals using Chi Square Test

Root Canal Morphology	Mesial		Distal		P-value
	N	%	N	%	
Type I	4	13.3%	23	76.7%	<0.001*
Type IV	26	86.7%	7	23.3%	<0.001*

\* - Statistically Significant

The gender wise distribution of primary mandibular second molar revealed that (Table V):

**In the mesial root:-** 10% of the males and 20% of the females had a single canal, whereas 90% of the males and 80% of the females had two canals.

**In the distal root:-** 90% of the males and 60% of the females had a single canal, whereas 10% of the males and 40% of the females had two canals.

**Table 5. Comparison of Root canals in Primary mandibular second molars based on gender using Chi Square Test**

Roots	Root Canals	Males		Females		c <sup>2</sup> value	P-value
		N	%	N	%		
Mesial	1 Canal	1	10.0%	1	20.0%	0.288	0.59
	2 Canals	9	90.0%	4	80.0%		
Distal	1 Canal	9	90.0%	3	60.0%	1.875	0.17
	2 Canals	1	10.0%	2	40.0%		

## DISCUSSION

Dental Caries is the most common chronic oral disease in children.<sup>2,7</sup> Primary teeth have a thinner layer of mineralized tissue when compared with the permanent teeth, which further can lead to rapid involvement of the dental pulp by advancing caries.<sup>2</sup> Spatial development of permanent teeth and arch length maintenance requires pulpectomy to conserve the primary teeth when it becomes non-vital or irreversibly inflamed.<sup>1,2,3,4</sup> The primary teeth may show bizarre internal geometry of the root and canal system such as furcations and horizontal anastomoses and thereby making the endodontic treatment highly complicated.<sup>2,3</sup> Therefore, more detailed knowledge of root canal morphology and variations are needed to improve the success of endodontics in primary molars.<sup>1,2,7</sup> The permanent teeth root canal morphology classification was given by Vertucci in 1984. A detailed search in literature found that there were very few studies done for primary mandibular second molars using Vertucci classification. In his classification, he used maxillary second premolars which was single rooted, whereas in this present study, we used primary mandibular second molars which had two roots. Hence, In these PMSMs, each root was taken individually and was studied for their root canal morphology and variations. Many techniques can be used to research about the root and canal morphology of teeth such as Computerized Tomography, Tooth staining and Clearing technique, Conventional radiography. Contrast media radiography and Operating microscopes.<sup>1,2,3,7</sup> The conventional radiographic techniques to evaluate the configurations of root canals of primary teeth has limitations as the image of the root and root canals always overlap and are 2-dimensional images.<sup>2,6</sup> In recent years, 3-D images of the oral and maxillofacial structures are obtained by CBCT on a high resolution which provides clearer and understandable images.<sup>1</sup> It has considerably low radiation dose compared to conventional CT scanning and has a resolution which is almost eight times that of CT scans.<sup>9</sup> Therefore, CBCT was suggested as a good option for the studies which evaluated root and canal morphology of teeth. Hence, using CBCT imaging technique was preferred in this present study.

In the present study, we used CBCT to evaluate the number of root and canal morphology in 30 primary mandibular second molars of 15 individuals of age 5-8 years. The sample size was limited as it is difficult to get details on primary teeth in vivo. Although several studies have been conducted to evaluate the root canal morphology of primary molars, very rarely any study has been done taking specifically PMSMs and by using Vertuccis classification. This particular age group was selected as it showed almost complete development and very minimal root resorption. So it is very important for a Pediatric dentist to have a thorough knowledge of the root canal morphology for the successful treatment so that the teeth can be maintained in the oral cavity thereby preventing space loss and further malocclusions.

In this study two separate roots were observed in all the primary mandibular second molars. In the mesial root, two root canals were observed in 86.7% (Type IV) of the cases and a single canal was seen in 13.3% (Type I) of cases, whereas in the distal root, a single root canal was seen in 76.7% (Type I) of cases and two canals were observed in 23.3% (Type IV) of the cases (Table II). The most commonly observed root canal type, which was observed in 60 roots (both mesial and distal) was Type IV (55%) followed by Type I (45%). Differences observed in the root and canal morphology of primary mandibular second molar teeth with respect to gender was not significant due to limited sample size. Two mesial canals and One distal canal (63.3%) (Figure3), Single mesial canal and a Single distal canals (13.3%) (Figure 4), and Two mesial canals and Two distal canals (23.3%) (Figure 5) were seen in this study. Vertuccis Type IV configuration was most common in the mesial roots followed by Type I and Vertuccis Type I configuration was most common in the distal roots followed by Type IV (Table III). An in-vitro CBCT study conducted by LeventDemiriz et al. on 228 primary mandibular second molars, concluded that the most commonly observed root canal type was Type IV (50%) and the most detected root canal type in the mesial roots was Type IV (65.79%), which was in accordance with our study in which the most commonly observed canal morphology was also Type IV (55%). It was followed by Type I (45%) canal configuration.<sup>1</sup> An in-vitro study was conducted by Ali Bagherian et al. on 22 PMSMs using clearing technique concluded that 95.5% of the samples had two roots (mesial and distal), which was in accordance with our study. Majority of the mesial roots showed two canals in 81.5% (Type IV) of the sample and majority of the distal roots showed a single canal in 77.8% (Type I) of the sample which was in accordance with the results of our study in which 86.7% (Type IV) of the sample had two canals in the mesial root and 76.7% (Type I) of the sample had a single canal in the distal root.<sup>7</sup> An in vitro study conducted by Dohee Sim et al. on 114 CT images of primary molars, concluded that Type 4 (2 mesial canals and 2 distal canals-88.8%) was the type observed most frequently, followed by Type 3M (2 mesial canals and 1 distal canal-9.9%), which was in contrast with our study in which 2 mesial canals and 1 distal canal (63.3%) was predominantly seen.<sup>10</sup> In another study conducted by Ran Yang et al. on 487 CBCT images of PMSMs, 73.31% had four canals, 25.26% had three canals and 0.82% had two canals and three teeth had five canals, which was in contrast with our study in which 63.3% had three canals, 23.3% had four canals and 13.3% had two canals.<sup>2</sup> The main goal of root canal therapy for deciduous teeth is to clean the root canals of infected tissues: therefore, detailed knowledge of the root and canal morphology of deciduous teeth can greatly improve the effectiveness and outcome of the treatment.<sup>7</sup> In the present study, CBCT was found to be reliable and has been shown to have excellent accuracy in determining the root canal morphology, with the potential of improving the outcome of endodontic treatment. There are several advantages associated with CBCT including 3-D imaging, image accuracy, rapid scan time, reduced image artefact and reduced radiation dosage.<sup>9</sup> But the availability, radiation and cost when prescribing CBCT imaging for children should be done with caution.<sup>11</sup>

## LIMITATION

A limitation of this study was that the sample size was less. Thus, further studies have to be conducted to identify the variations in root canal morphology which helps pediatric

dentists in improving their diagnostic and endodontic treatment skills.

## CONCLUSION

This in-vitro study showed the variations in the root and canal morphology in primary mandibular second molars in children. The knowledge of the possible number of root canals alone may not be enough to reach success in root canal treatment of primary teeth. Hence, being aware of the various root canal configurations in primary teeth, there are more chances of success for the treating Pediatric dentist. The results of the present study, different from the common findings of previous studies showed various root canal configurations in both mesial and distal roots of PMSMs.

## IMPORTANCE OF THE PRESENT STUDY

- Studies conducted on the root canal morphologies of the primary teeth using CBCT are relatively rare.
- In this study, the applicability of Vertuccis Classification on PMSMs was evaluated in which each root was taken individually.
- Failure of the detection of an extra canal is considered to be one of the reasons for the failure of pulpectomy in these teeth.
- CBCT is the best 3-D imaging technique for evaluation and identification of root canal morphology because of its low radiation exposure.

## ABBREVIATIONS

PMSMs- Primary Mandibular Second Molars

CBCT- Cone Beam Computed Tomography

CT- Computed Tomography

**FINANCIAL SUPPORT AND SPONSORSHIP:** The authors have no funding to report.

## ACKNOWLEDGEMENT

The authors would like to acknowledge the department of Oral medicine and radiology for their support in successful completion of the present study.

**CONFLICT OF INTEREST:** The authors declared no conflicts of interest.

## REFERENCES

- Demiriz L, Bodrumlu EH, Icen M. 2018. Evaluation of root canal morphology of human primary mandibular second molars by using cone beam computed tomography. *Niger J Clin Pract.*, 21(4).
- Yang R, Yang C, Liu Y, Hu Y, Zou J. 2013. Evaluate root and canal morphology of primary mandibular second molars in Chinese individuals by using cone-beam computed tomography. *J Formos Med Assoc.*, 112(7):390-5.
- Reddy NV, Daneswari V, Patil R, Meghana B, Reddy A, Niharika P. 2018. Three-dimensional assessment of root canal morphology of human deciduous molars using cone beam computed tomography: An In vitro Study. *Int J Pedod Rehabil.*, 3(1):36.
- Kurthukoti AJ, Sharma P, Swamy DF, Shashidara R, Swamy EB. 2015. Computed tomographic morphometry of the internal anatomy of mandibular second primary molars. *Int J Clin Pediatr Dent.*, 8(3):202.
- Selvakumar H, Kavitha S, Bharathan R, Varghese JS. 2014. Five canalled and three-rooted primary second mandibular molar. *Case Rep Dent.*, 2014.
- Wang YL, Chang HH, Kuo CI, Chen SK, Guo MK, Huang GF, Lin CP. 2013. A study on the root canal morphology of primary molars by high-resolution computed tomography. *J Dent Sci.*, 8(3):321-7.
- Bagherian A, Kalhori KA, Sadeghi M, Mirhosseini F, Parisay I. 2010. An in vitro study of root and canal morphology of human deciduous molars in an Iranian population. *J Oral Sci.*, 52(3):397-403.
- Ozcan G, Sekerci AE, Cantekin K, Aydinbelge M, Dogan S. 2016. Evaluation of root canal morphology of human primary molars by using CBCT and comprehensive review of the literature. *Acta Odontol Scand.* 74(4):250-8.
- Mehta V, Ahmad N. 2020. Cone beamed computed tomography in pediatric dentistry: Concepts revisited. *J Oral Bio Craniofac Res.*, (2):210.
- Sim D, Mah Y. 2019. A study of root canals morphology in primary molars using computerized tomography. *J Korean Acad Pediatr Dent.*, 46(4):400-8.
- Van Acker JW, Martens LC, Aps JK. Cone-beam computed tomography in pediatric dentistry, a retrospective observational study. *Clin Oral Invest* 2016 ;20(5):1003-10.
- Cheong J, Chiam S, King NM, Anthonappa RP. Pulp chamber analysis of primary molars using micro-computed tomography: preliminary findings. *J Clin Pediatr Dent.*, 2019;43(6):382-7.
- Katge F, Wakpanjar MM. Root canal morphology of primary molars by clearing technique: An in vitro study. *J Indian Soc Pedod Prev Dent.*, 2018 ;36(2):151.
- Datta P, Zahir S, Kundu GK, Dutta K. An in vitro study of root canal system of human primary molars by using multidetector computed tomography. *J Indian Soc PedodPrev Dent.*, 2019 ;37(2):120.
- Aminabadi NA, Farahani RM, Gajan EB. Study of root canal accessibility in human primary molars. *J Oral Sci.*, 2008;50(1):69-74.
- Nagaveni NB, Bajaj M, Shruthi AS, Poornima P. Radix paramolaris (supernumerary third root) in primary mandibular second molar: Report of two cases. *Niger J Exp Clin Biosci.*, 2014 ;2(2):134.
- Song JS, Kim SO, Choi BJ, Choi HJ, Lee JH. Incidence and relationship of an additional root in the mandibular first permanent molar and primary molars. *Oral Surg Oral Med Oral Pathol Oral Radiol Endod.* 2009; 107(1):e56-60.
- Salama FS, Anderson RW, McKnight-Hanes C, Barenie JT, Myers DR. Anatomy of primary incisor and molar root canals. *Pediatr Dent.*, 1992 ;14(2):117-8.
- Gaurav V, Srivastava N, Rana V, Adlakha VK. A study of root canal morphology of human primary incisors and molars using cone beam computerized tomography: An in vitro study. *J Indian Soc PedodPrev Dent.*, 2013 ;31(4):254.
- Joshi N, Deshpande A, Poonacha KS, Bargale S, Naik K, Mehta D. Cone Beam Computed Tomography Evaluation of Root Canal Anatomy in Primary Molars: An in vitro Study. *Int J Clin Dent Res.*, 2017 ;1(1):15-19.