



ISSN: 0975-833X

RESEARCH ARTICLE

FUNCTIONAL ECHOCARDIOGRAPHY (F ECHO) IN NICU A NEED FOR THE HOUR- A BIRD'S VIEW

***Dr. Venkatesh, H. A., Maitry Choudhary, Mrinal S. Pillai and Pankaj Kumar Mohanty**

Consultant Neonatologist, Manipal Hospital, Bangalore, India

ARTICLE INFO

Article History:

Received 29th August, 2014

Received in revised form

23rd September, 2014

Accepted 16th October, 2014

Published online 30th November, 2014

Key words:

New Born;

Functional ECHO;

Evidence Based Management

Copyright © 2014 Dr. Venkatesh, et al. This is an open access article distributed under the Creative Commons Attribution License, which permits unrestricted use, distribution, and reproduction in any medium, provided the original work is properly cited.

ABSTRACT

Tremendous improvement in the neonatal care has led to the reduction in the mortality and morbidity of babies born below 30 weeks of gestation. Evidence based management, Expertise in the newborn care and the exponential growth of equipments have led a mark able role in the survival of tinsyck babies. Most of NICUs depend upon urine output, capillary refilling time, blood gas analysis in judging baby hemodynamic ally, however sensitivity and specificity of these parameters are reasonably less. Hence longitudinal assessment of baby's physiology is very crucial for the better acute and long term outcome. In this direction functional echocardiography has been evolved as an added entity to physical examination in the care of sick babies. Hence systematic serial studies in the NICU by f ECHO by neonatologist is very crucial and need of the hour.¹

INTRODUCTION

Introduction to Functional ECHO

Longitudinal assessment of function of the heart in addition to the clinical parameters in the care of sick new born babies has become the major breakthrough in the management. Structural heart defects like TAPVC, Coarctation of Aorta and transposition of great arteries should be ruled out by a cardiologist. Of late a lot of enthusiasm amongst neonatologists in learning functional echo and applying the findings to clinical examination in their day to day neonatal rounds. Of course proper training and constant learning is very essential to meet the goal.

Brief note on cardiovascular adaptation

Neonatal heart is unique in a way it is entirely different from paediatric and adult population (picture1). Changes in the lung volume, compliance of the chest, preload and after load of right heart and left heart, intra cardiac and extra cardiac shunts, have varying effects in the post neonatal hemodynamic.²Hence it is very essential to understand the fetal, transitional and post neonatal cardio respiratory physiology before understanding functional echocardiography. Poor compliance of the chest enclosing the heart, less developed cardiac muscle mass, less contractile heart make them very much different from paediatric and adult population.

Additionally the right ventricle is less tolerant for increasing after load with increased fetal pulmonary vascular resistance. The low resistant placental circuit, a ductusarteriosus and patent foramen ovale are highly essential for the fetal physiology. Immediately after birth there is an abrupt increase in systemic after load, decrease in right ventricular preload and decrease in pulmonary vascular resistance. The fetal transition is more complicated in the preterm infant having less developed myocardium. Hence it is very crucial for every person performing and interpreting neonatal ECHO to be familiar with neonatal cardio vascular adaptation.

Brief note on ultra sound

When energy is passed through any media it produces a mechanical disturbance which is referred as sound. Every sound has got its own velocity, frequency and intensity. The audible range of sound frequency is 20HZ to 20KHZ. So sound frequency above audible range to human ear is known as Ultra sound. Velocity of sound is product of frequency and wave length, (Velocity= Frequency X wave length) and frequency and wave lengths are inversely related (Frequency=1/wavelength). This concept is well utilised in probes used for echocardiogram. The probes do contain crystals called Piezoelectric crystals (Magnesium tartarate), which convert electric energy to mechanical energy and make the image to display on cathode ray tube. The function of piezoelectric crystals is shown in the Figure 2. Low frequency probes (2.5-3.5MHZ) will increase the penetration (useful in patients with thick chest).

***Corresponding author: Dr. Venkatesh, H. A.**

Consultant Neonatologist, Manipal hospital, Bangalore, India.

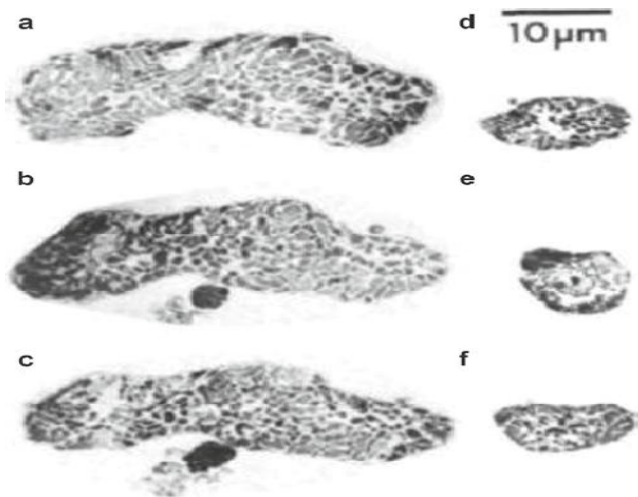


Figure 1. Cardiac myocyte –cross section
a-c Adult, d- f Neonate

The reflected scale gives information about the depth and nature of the tissue studied as depicted in the Table 1

Table 1. Structure reflectivity on ECHO

ECHO reflectivity		
Tissue	reflectivity	shade
Bone	high	white
Muscle	low	grey
Air	nil	black

Indications for Echocardiography in neonatology

Targeted neonatal echocardiography is proposed to describe the bed side use of echocardiography to longitudinally assess myocardial function, systematic and pulmonary blood flow, intracardiac and extra cardiac shunts, organ blood flow and tissue perfusion (Kluckow *et al.*, 2007). American echocardiography association targeting neonatal group classifies the problems needing echo. They are

Targeted neonatal echocardiography with standard imaging (standard TNE)

- Clinically suspected PDA in very low birth weight babies during the first 24-72 postnatal hours and beyond
- Suspected persistent pulmonary hypertension in neonates
- Assessment of infants with perinatal asphyxia
- To diagnose low systemic blood flow in neonates with hypotension
- Neonate with CDH

Targeted neonatal echocardiography with focussed imaging (Focussed TNE)

- Central line (Figure 4 and 5 demonstrates umbilical vessels canulation using echocardiogram)
- suspected pericardial effusion (Figure 6 and 7 demonstrating pericardial effusion with tamponade and normal heart after pericardiocentesis respectively). Pericardiocentesis using echocardiogram is being done and demonstrated (Picture 7).

If strong suspicion of CHD or arrhythmia is present in a new born it should be assessed by a pediatric cardiologist and comprehensive echocardiography should be performed and interpreted by a Pediatric cardiologist (Mertens *et al.*, 2005 and Sanders *et al.*, 2005)

The major indications for fECHO in neonatology is broadly classified into 2 major groups. They are standard and focussed.

Standard indications

- Clinically suspected PDA

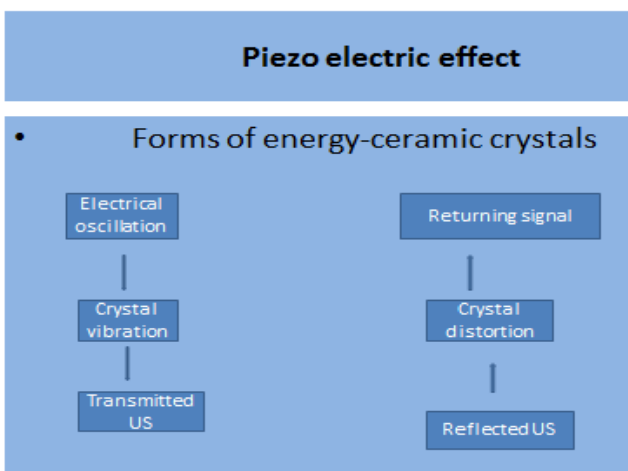


Figure 2. Function of Piezoelectric crystal

Low frequency probes (2.5-3.5MHZ) will decrease the resolution and increase the penetration (useful in big children and adults)and high frequency probes (5-10 MHZ) will increase the resolution (useful in neonates). The relationship between frequency and wavelength are well depicted in the following Figure 3.

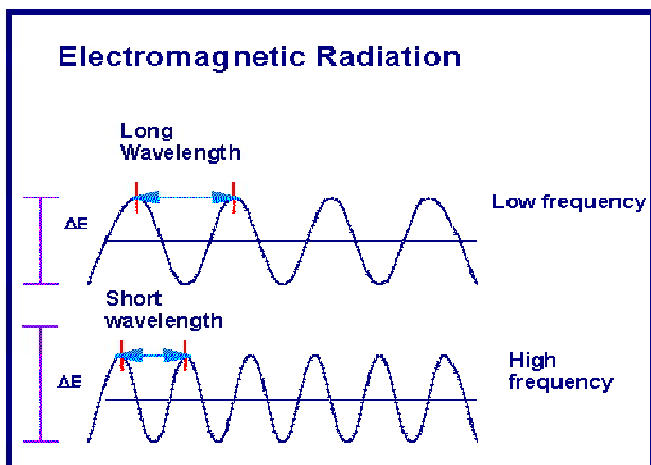


Figure 3. Frequency wave length relation

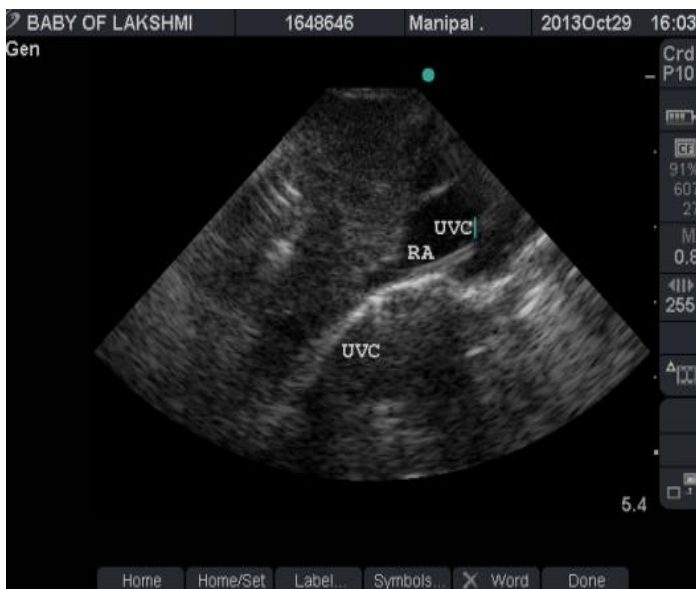

Figure 4. UVC tip in right atrium

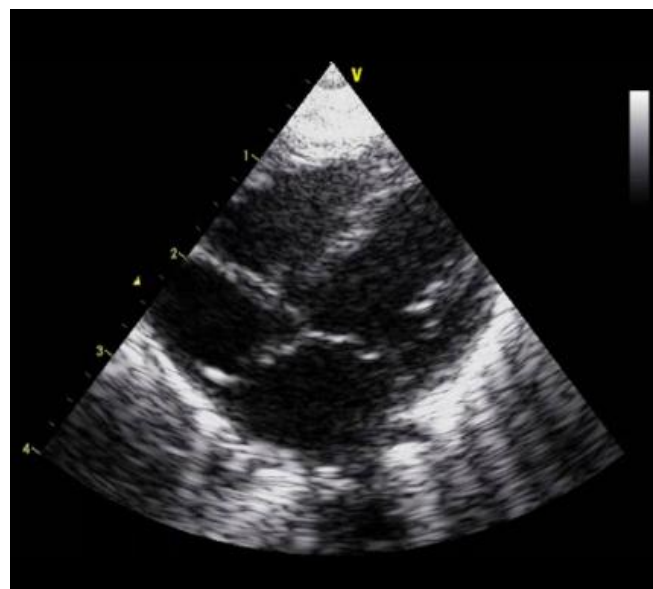

Figure 7. Post pericardiocentesis-demonstrating good contractile heart

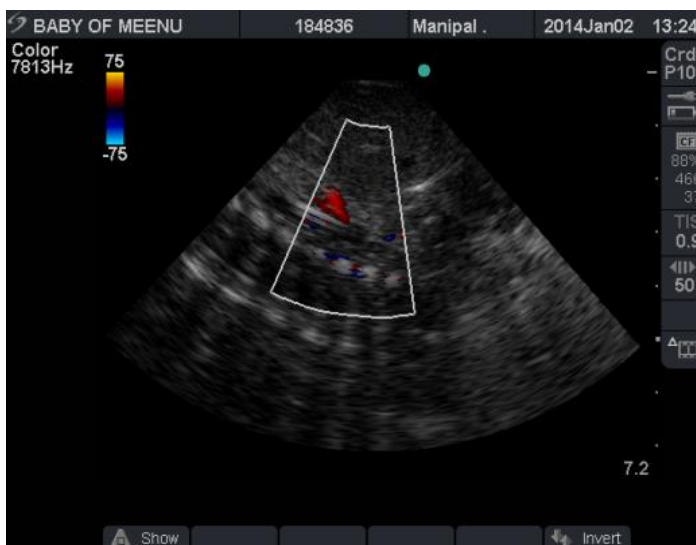


Figure 5. UAC in descending aorta with tip a above celiac artery

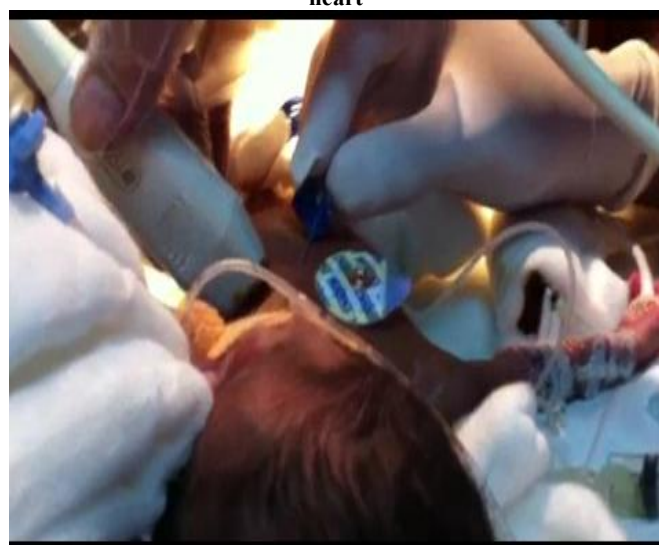

Figure 8. Pericardiocentesis procedure being done under echocardiogram

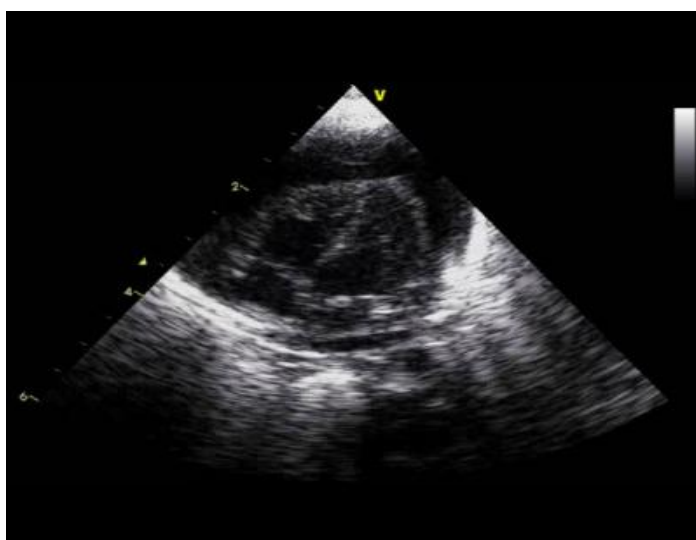

Figure 6. Pericardial effusion with tamponade demonstrating poor cardiac contractility

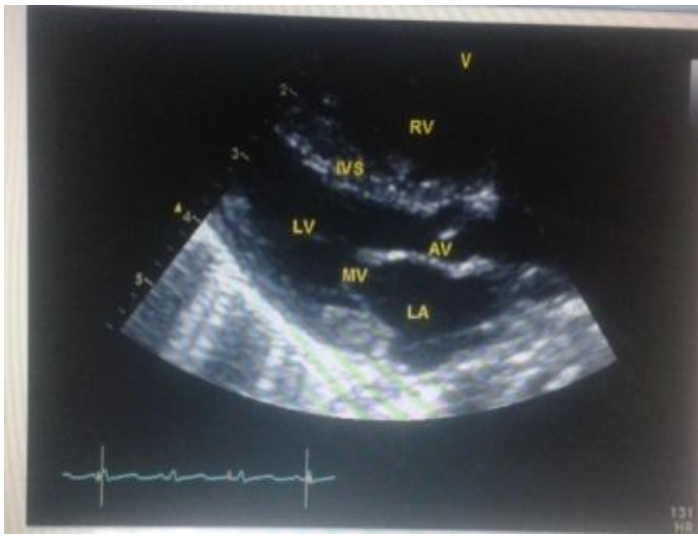
- Neonatal hypotension to diagnose systemic blood flow and superior vena cava flow as a determinant of cerebral blood flow
- Suspected persistent pulmonary hypertension
- Assessment of infants with perinatal asphyxia
- Babies born with congenital hernia to rule out PPHN

Focussed indications

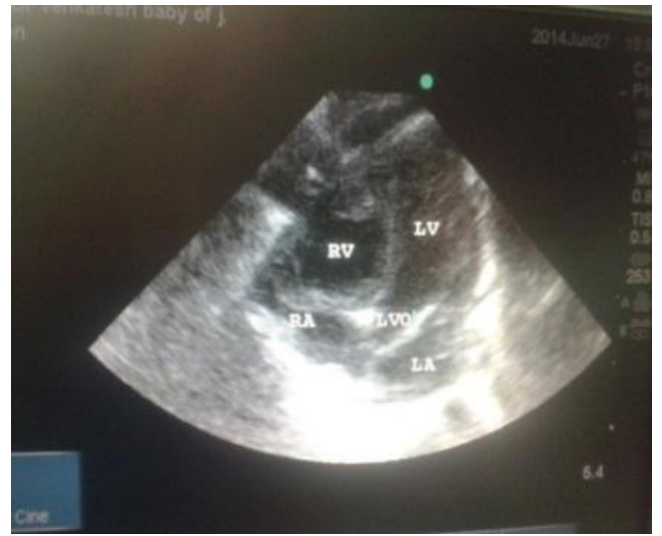- Assessment of central line insertion
- Suspected pericardial effusion

Standard ECHO views

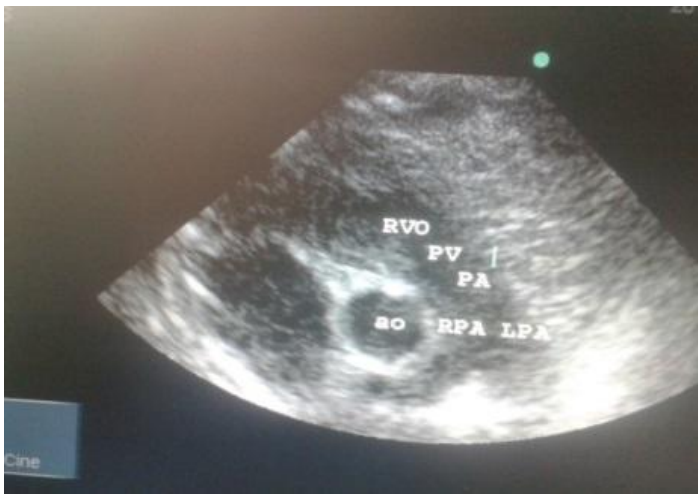Heart is looked through designated windows (through intercostal space) for proper visualisation and appreciation. There are standard views for over all information of the heart. There are standard 5 views.



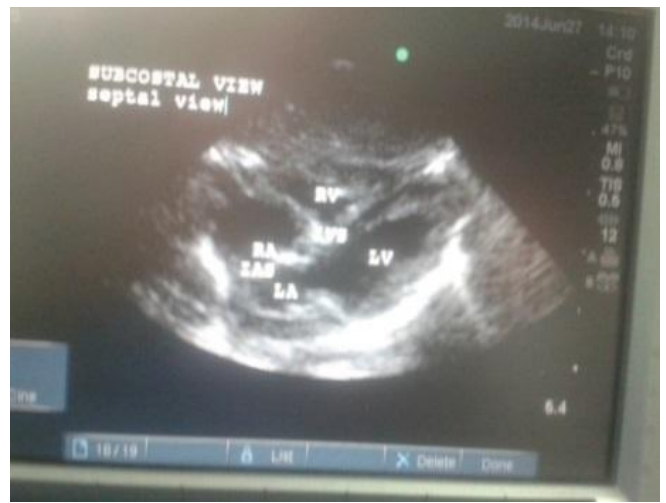Parasternal long axis view



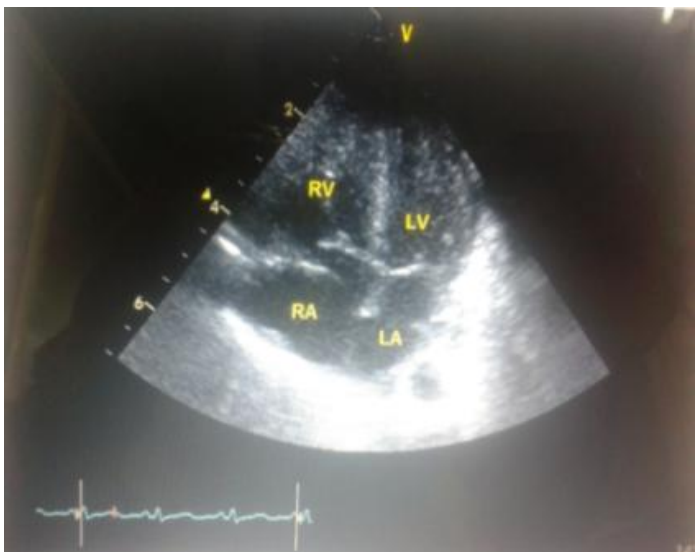
Apical -5 chamber view



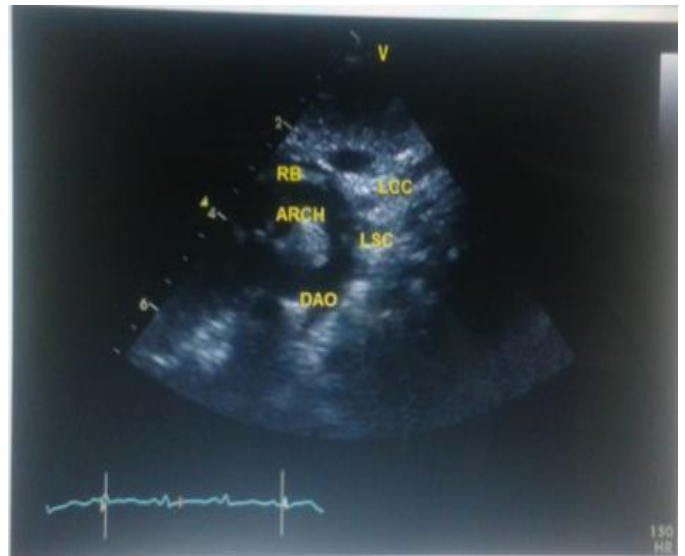Parasternal short axis view



Subcostal view-demonstrating



Apical-4 chamber view



Suprasternal- arch view 4 chambers with septae

Figure 9. Echo views demonstrated using echocardiography

Table 2. Depicting different views and its applications

Views	Probe position	Structure appreciated	Clinical relevance
PLAX	Marker of the probe(3 rd and 4 th ICS) facing right shoulder	Right ventricle, interventricular system, left ventricle, left ventricle out let (aortic valve),mitral valve and left atrium	Shape of right ventricle, LA/AO ratio calculation, left atrial enlargement, to look at any pericardial effusion To calculate ejection fraction and to look for septal hypertrophy
SAX	Marker facing left shoulder	Great vessels, mitral valve, papillary muscle, apex of the heart	PDA view
Subcostal Coronal	Subxiphoid, marker down in mid line	Inferior venacava, descending aorta, Interatrial septum and pericardial effusion	Effect of respiration on IVC,SVC flow
sagittal suprasternal	Same as above Suprasternal space pointer facing left chin	Arch of aorta, SVC flow	Coarctation of aorta
Apical 4 chamber	Apex of heart, Marker position facing left shoulder	Quantify tricuspid and mitral regurgitation	RV: trabeculated, presence of moderator band, tricuspid valve is towards apex. LV: smooth and mitral valve towards base
Apical 5 chamber		LV - out flow tract.	

All the views together are depicted (Table 2). The echo views are demonstrated in

- Sub costal view
- Parasternal long axis view (PLAX)
- Parasternal short axis view(SAX)
- Apical view
- Suprasternal view

Functional echo is also used to localise central lines and to pick up pericardial effusion. Superior vena cava assessment in determining systemic blood flow and inferior vena cava flow assessment in determining fluid responsiveness in septic ventilated patients are other critically required entities in the management in intensive care unit (Kluckow and Evans, 2000; Barbier *et al.*, 2004 and Feissel *et al.*, 2004).

Care while doing ECHO

A basic knowledge of tender care towards baby is a prime requisite before considering the ultrasound. Following are the main areas need to be critically looked into while doing Echocardiography (picture 4)

Do no harm: Echocardiography is needed if clinically warrants. Spending a lot of time and exposing the baby for a long time for the procedure when not clinically indicated harms the baby more than benefit.

Prevention of infection and maintain skin integrity: Utmost importance is given before touching the baby. Maintenance of asepsis is crucial during the procedure.

Skin of pre-term baby is very thin and delicate, caution while keeping and moving the transducer is needed to maintain the integrity of the skin.

Thermal comfort: Procedure needs to be done preferably under radiant warmer. Body temperature should be maintained between 36.5^{0C} – 37.5^{0C} Pre warmed gel should be used

Cardiorespiratory monitoring: vitals need to be monitored throughout the procedure as the performer concentrates only in getting good images and might forget to look at vitals and the baby as a whole.

REFERENCES

- Evans Echocardiography on neonatal intensive care units in Australia and Newzeland. *J. Pediatr Child Health*, 2000; 36:169-171
- Rudolph AM. Myocardial growth before and after birth. Clinical implications. *Acta Paediatr.*, 2000; 89:129-33
- Kluckow M, Seri I, Evans N. Functional echocardiography: an emerging clinical tool for the neonatologist. *J Pediatr.*, 2007; 150:125-30
- Mertens L, Helbing W, sieverdingb L, Daniels Guidelines from the association for European Paediatric Cardiology: standards for training in paediatric echocardiography. *Cardiol Young*, 2005; 81:413-22
- Sanders SP, Colan SD, cordes TM. Donofrio MT, Ensing GJ, Geva T. *et al.* ACCF/AHA/AAP recommendations for training in pediatric cardiology. Task force 2: paediatric training guidelines for non-invasive cardiac imaging endorsed by the American society of Echocardiography and the society of Paediatric Echocardiography. *J Am Collcardioll.*, 2005; 46:1384-8
- Kluckow M, Evans N. Low superior vena cava flow and intraventricular hemorrhage in preterm infants. *Arch. Dis. Child*, 2000; 82:F188-95
- Barbier C, Loubieres Y, Schmidt C, *et al.* Respiratory changes in inferior vena cava in ventilated septic patients. *Intensive Care Med.*, 2004; 30:1740-6
- Feissel M, Michard F, Faller JP, Teboul L. The respiratory variation in inferior vena cava diameter as a guide to fluid therapy. *Intensive CARE Med.*, 2004; 30:1834-7