



ISSN: 0975-833X

## CASE REPORT

### OVERLAY DENTURE- A PREVENTIVE PROSTHODONTIC TREATMENT- A CASE REPORT

**\*<sup>1</sup>Dr. Eswaran, M. A., <sup>2</sup>Dr.Rathika Rai and <sup>3</sup>Dr. Maheswari, H.**

<sup>1</sup>Department of Prosthodontics, Thai Moogambigai Dental College and Hospital, Mugappair, Chennai, India

<sup>2</sup>Specialty in Oral Medicine and Radiology, Private Practice, Anna Nagar West extn, Chennai, India

#### ARTICLE INFO

##### Article History:

Received 21<sup>st</sup> July, 2015

Received in revised form

05<sup>th</sup> August, 2015

Accepted 08<sup>th</sup> September, 2015

Published online 20<sup>th</sup> October, 2015

#### ABSTRACT

Complete denture fabrication is a challenge in case of remaining teeth present. Patient satisfaction is the ultimate goal of a dental treatment. To improve the quality of the complete denture prosthesis and comfort to the patient, preservation of the remaining structures is utmost importance. This case report deals with use of remaining natural tooth to aid in retention, stability and support of tooth supported over dentures. The treatment longevity depends on patient's oral hygiene maintenance and periodic recalls.

#### Key words:

Overlay Denture,  
Tooth Supported,  
Proprioception,  
Hybrid Denture.

Copyright © 2015 Eswaran et al. This is an open access article distributed under the Creative Commons Attribution License, which permits unrestricted use, distribution, and reproduction in any medium, provided the original work is properly cited.

**Citation:** Eswaran, M. A., Rathika Rai and Maheswari, H. 2015. "Overlay denture- a preventive prosthodontic treatment- A case report", *International Journal of Current Research*, 7, (10), 21343-21346.

## INTRODUCTION

Patient satisfaction has been the ultimate goal in any dental treatment. In patients receiving complete denture prosthesis, many factors have a combined role in achieving patient satisfaction. An efficient mastication, good esthetics, comfortable speech and function are the factors in patient satisfaction. The ultimate goal for every patient should be maintainable health of all the structures of the masticatory system. Muller DeVan (1935) stated that "the preservation of that which remains is of utmost importance and not the meticulous replacement of that which has been lost". Prolonged edentulism leads to excessive alveolar bone resorption, increased vertical dimension and poor denture fit. Conventional over denture treatment is the ultimate choice for the patient with good oral hygiene, to preserve the alveolar bone as well as supporting hard and soft tissues. This case report deals with diagnosis and treatment planning for making conventional over denture supported by remaining natural teeth to preserve the periodontium as well as alveolar bone.

### Definition

A removable partial denture or complete denture that covers and rests on one or more remaining natural teeth, the roots of

natural teeth, and/or dental implants; also called overlay denture, overlay prosthesis, hybrid dentures and superimposed prosthesis. (Glossary of prosthodontic terms, 2001)

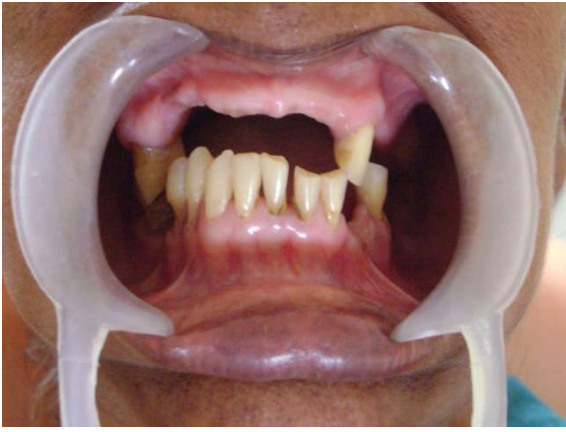### Case Report

A 55 year healthy female patient came to the department of prosthodontics and crown and bridge, Thai Moogambigai dental college and hospital with partially edentulous maxillary and mandibular arch. There was no significant medical and dental history. Extra oral and intra oral examination was done. On intra oral examination 16,23,31,32,35,41,42,43,44,45,47 teeth were present. Patient advised to retain the teeth instead of extraction to prevent resorption of alveolar bone. Treatment plan was discussed with patient and informed consent was taken. Patient advised for tooth supported over denture with right molar and left canine as abutments in maxillary arch. To increased retention in mandibular partial denture left lower premolar as abutment. Over denture option will improve the proprioception and maximum retention. (Fig. 1)

Always preferred to retain maxillary canine for over denture abutment, because of central strategic position, single long root and many nerve receptors. (Kalpana and Prasad, 2010) Abutment should be good periodontal condition, surrounded by sufficient alveolar bone at least 6mm, exhibit minimal mobility.

**\*Corresponding author: Dr. Eswaran, M.A.**

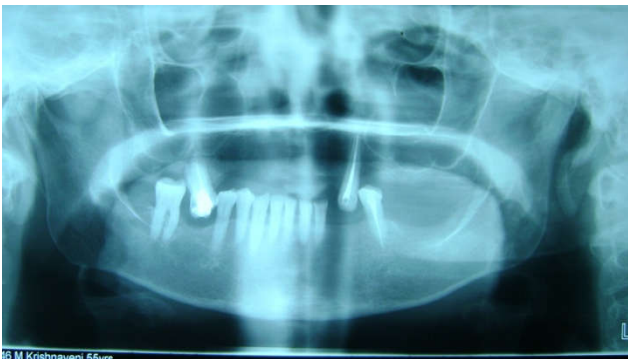
Department of Prosthodontics, Thai Moogambigai Dental College and Hospital, Mugappair, Chennai, India.



**Fig. 1. Pre Operative intra oral view**

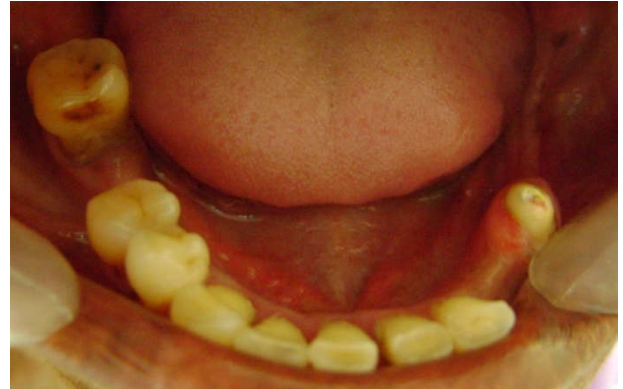### Procedures

Diagnostic impression made with irreversible hydro colloid. Intentional root canal treatment is necessary to allow for sufficient reduction and contouring in 16, 23, and 35. (Fig.2) Abutments were reduced to 2mm above the gingival margin and give dome shape with chamfer as finish line. (Fig.3) Dome shaped configuration reduces stress and provides maximum support. Sharp edges should be round, undercuts eliminated. Treatment should be accompanied with fluoride gel application and oral hygiene instructions. Final impression made using rubber base impression material with light body wash impression for better marginal record. Cast poured with type IV dental stone, cast are sewed to separate dies, wax pattern made with dome shaped, invested, burned out and short metal coping was recovered.

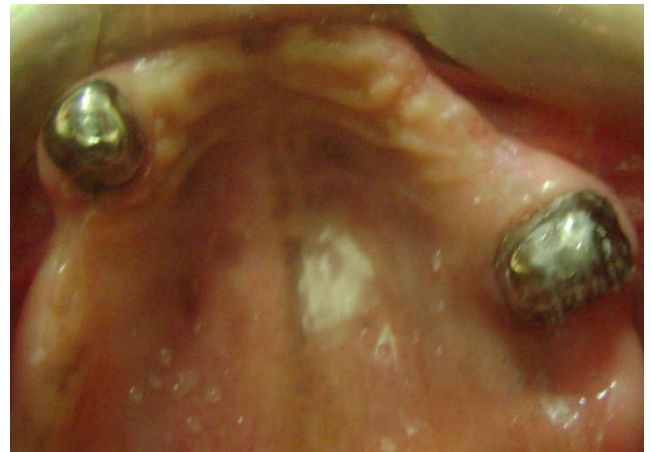

**Fig. 2. Orthopantomograph showing endodontic fillings of abutments**

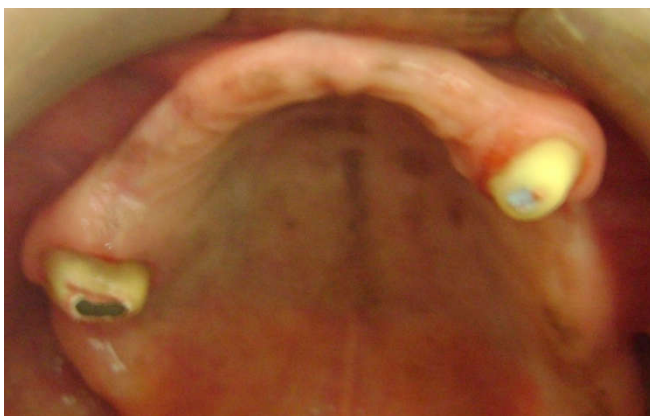
Cast metal short copings in 16, 23, and 35 with a dome shaped surface were cemented using type I GIC luting cement. (Fig.4) Conventional denture fabrication technique was used to construct the over denture. Primary impression was made, special tray fabrication, final impression with elastomeric material, (Fig.5) jaw relation record, wax try-in procedure (Fig.6) should be carried out. Denture was fabricated using conventional method and insertion done. Care should be taken on the tissue surface of the fabricated denture, the areas near the gingival margins to be trimmed in order to avoid tissue impingement. (Fig.7) Post insertion instructions given to patient, in future tissue surface of the denture lined with soft resilient liner for better adaptation. (Fig.8, 9)



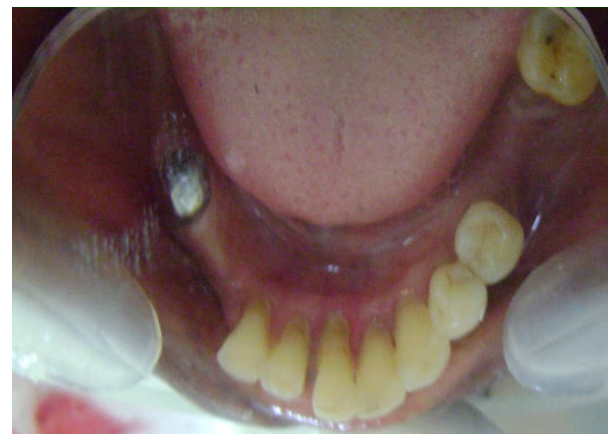**Fig. 3b. Mandibular tooth preparation for short coping**



**Fig. 4a. Cementation of metal coping in maxillary arch**



**Fig. 3a. Maxillary tooth preparation for short coping**



**Fig. 4b. Cementation of metal coping in mandibular arch**

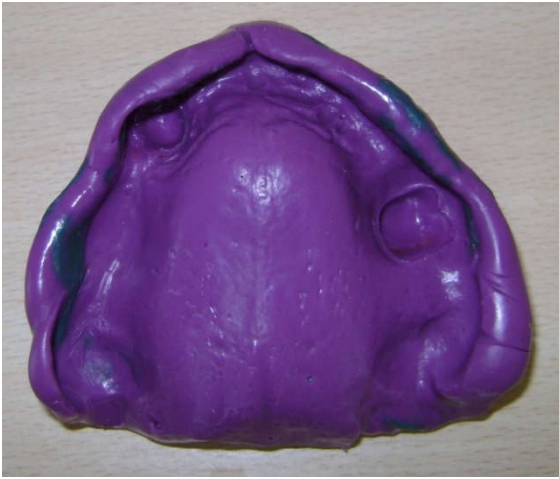

Fig. 5. Elastomeric final impression

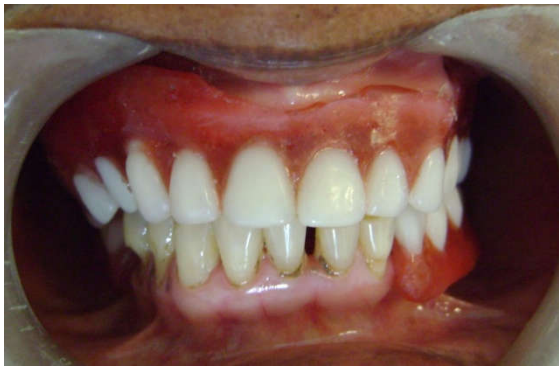

Fig. 6. Wax denture try-in

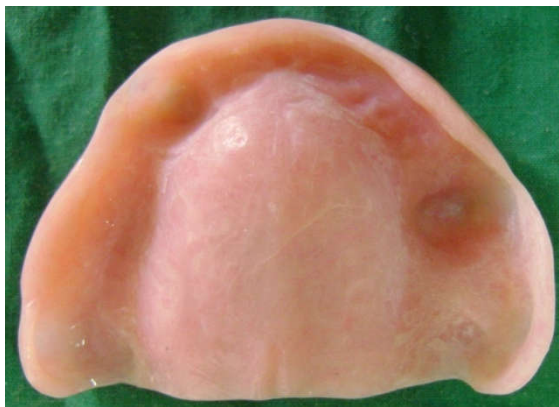

Fig. 7a. Finished maxillary denture intaglio surface

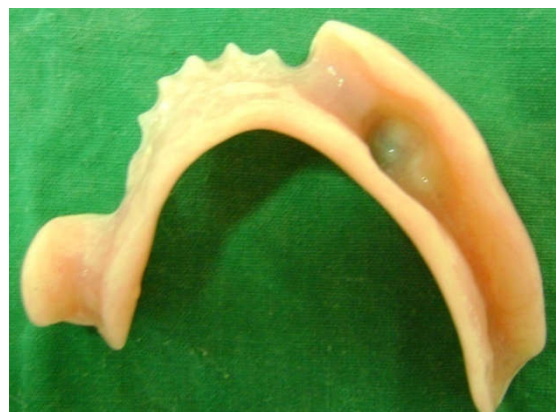

Fig. 7b. Finished mandibular denture intaglio surface

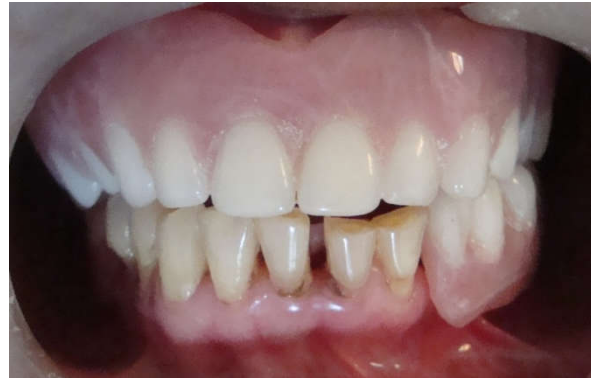

Fig. 8. Overlay final denture in situ

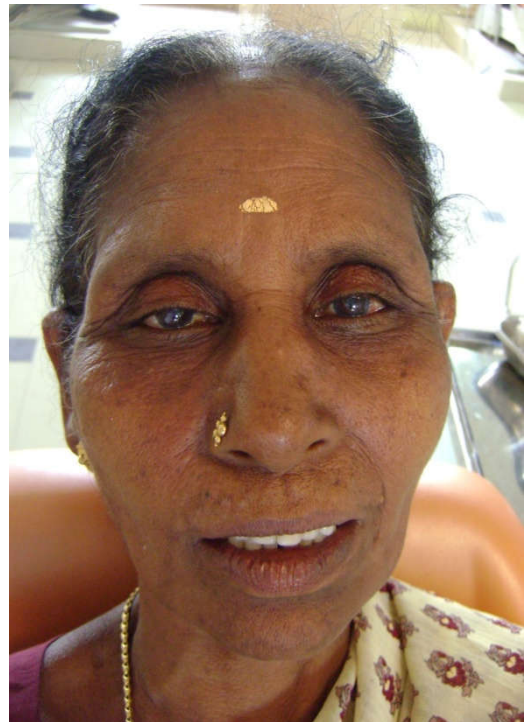

Fig. 9. Post operative extra oral view

## DISCUSSION

Various literature studies showed that the elderly people affect with their loss of tooth due to periodontal condition and dental caries. The preservation of remaining teeth at the same time preserves the residual alveolar bone around remaining roots is utmost important (Preiskel, 1996). The basic over denture concept requires preservation of residual hard and soft tissues. By reducing the trauma to the mucosal tissues, it is reasonable to expect that resorption of the alveolar process will be lessened. (Gorakhnath *et al.*, 2012)

The over denture patients had a chewing efficiency which was one-third higher than that of conventional complete denture wearers. (Rissin *et al.*, 1978) Tallgren concluded that anterior mandible height resorbed four times faster than maxillary ridge with conventional dentures. (Tallgren, 1972) It was concluded in a 5-year study that retention of mandibular canines for over dentures led to preservation of alveolar bone. (Crum and Rooney, 1978) The use of immediate denture fabrication for

temporary rehabilitation prior to definitive over dentures can provide comfort to the patient during the treatment. The root supported over denture is a better alternative for a treatment option to conventional dentures since the proprioception is maintained and improves stability and retention. (Batista *et al.*, 2014)

Reinforcement of denture base with metal is not only to prevent fracture, but also to improve functional rigidity for occlusal stability, and to distribute occlusal stress to the underlying denture-bearing areas as uniformly as possible. (Shikha Jindal *et al.*, 2013) The patient was satisfied with his dentures in terms of function and aesthetics due to fabrication and advantages of removable partial denture supported by teeth and implants with long edentulous span. (Lalit Kumar and Komal Sehgal, 2014) One of the most important requirements to the success of over dentures is the patient's awareness of their need to improve oral hygiene of the remaining roots used for support and/or retention. The patient must be instructed to correct techniques of oral hygiene to improve considerably the longevity of the oral rehabilitation as long as possible (Brkovic-Popovic *et al.*, 2008; Shrivastava *et al.*, 2012) After the overdenture treatment planned, care should be taken by the patient to maintain plaque free oral health. Also dentist should check for pocket formation around the abutments, failure leads to caries formation around the cervical region of abutment tooth. (Shrivastava *et al.*, 2012) Regular follow up visits important for the longevity of the treatment. The patient was satisfied with his dentures in terms of function and aesthetics due to preservation of hard and soft tissues as well as proprioception. Finally over denture treatment provides excellent long-term success and survival, including patient satisfaction, improved oral functions and oral health related quality of life.

### Conclusion

The over denture described are a deviation from the normal dental treatment methods. These are definitively advantageous to the patient and therefore should be undertaken whenever the clinical situations provide an opportunity. The patient was satisfied with these kind of over dentures to better occlusal function. Concluded that overlay denture provide the benefits of good esthetics, phonetics, better retention and comfort. Bone preservation leads to better enhanced nutrition resulting in improved quality of life. Dentist also plays an important role for proper case selection and periodic reviews.

### REFERENCES

- DeVan MM: An analysis of stress counteraction on the part of alveolar bone, with a view to its preservation. *Dent Cosmos*, 1935;77:109-123.
- Batista V E de Souza et al. Root supported overdentures associated with temporary immediate prostheses-A case report. *OHDM*, Vol 13:No.2:June 2014.
- Brkovic-Popovic S, Stanisic-Sinobad D, Postic SD, Djukanovic D. Radiographic changes in alveolar bone height on overdenture abutments: a longitudinal study. *Gerodontology*. 2008; 25: 118-223.
- Crum RJ, Rooney Jr GE. Alveolar bone loss in Overdentures: a 5-year study. *The Journal of Prosthetic Dentistry*, 1978; 40:610-3.
- Glossary of prosthodontic terms. *Journal of Prosthetic Dentistry*, 2001; Volume 94, Issue 1, Pages 10- 92.
- Gorakhnath B Shinde,Wadkar. Overdenture: A Way of Preventive Prosthodontics *Indian J Dent Adv.*, 2012; 4(2) 863-867
- Kalpna C, Prasad K V. Seeing the unseen: Preventive prosthodontics: use of overlay removable dental prosthetics. *Annals and Essences of Dentistry*, 2010:2:44-49.
- Lalit Kumar, KomalSehgal. Removable Partial Denture Supported by Implants with Prefabricated Telescopic Abutments - A Case Report. *Journal of Clinical and Diagnostic Research*, 2014 Jun, Vol-8(6): ZD04-ZD06.
- Rissin L, House JE, Manly R, Kapur K. Clinical comparison of masticatory performance and electromyographic activity of patients with complete dentures, overdentures, and natural teeth. *The Journal of Prosthetic Dentistry*, 1978; 39:508-11.
- Shikha Jindal, Roma Goswami, S P Singh. Metal Reinforced Mandibular Overdenture With Bar Attachment. *e-Journal of Dentistry*, Jul - Sep 2013 Vol 3 Issue 3;pg 447-450
- Shrivastava R, Awinashe V, Srivastava R. Simple Overdenture Technique, Lasting Results-A Case Report. *NJDSR* 2012; 1: 37-41.
- Tallgren A. The continuing reduction of the residual alveolar ridges in complete denture wearers: a mixed-longitudinal study covering 25 years. *The Journal of Prosthetic Dentistry*, 1972; 27:120.

\*\*\*\*\*