



CASE REPORT

OSTEOLIPOMA OF TIBIA A RARE CASE REPORT

*Dr. Saikat Sau

Department of Orthopedics, IPGMER SSKM Hospital, Kolkata West Bengal, India

ARTICLE INFO

Article History:

Received 30th January, 2016
Received in revised form
15th February, 2016
Accepted 29th March, 2016
Published online 26th April, 2016

Key words:

Osteolipoma,
Tibia,
Leg.

ABSTRACT

Introduction: Lipomas are the most common benign soft tissue tumors and appear in any part of the body. They typically consist of mature adipose tissue. Osteolipoma is an extremely rare histologic variant of lipoma that contains mature lamellar bone within the tumor and osteolipoma independent of bone tissue are very rare. We report a case of histologically confirmed osteolipoma independent of bone located in the leg.

Case presentation: A 30-year-old female presented with a progressively enlarging, painless mass which approximately 5 cm × 8 cm over the posteromedial aspect of her left leg. Plain films, Computerized Tomography, Magnetic Resonance Imaging and ultrasound guided needle biopsy were performed. Given the benign imaging characteristics and fine needle aspiration, an excisional biopsy was undertaken. No recurrence was observed after 12 months follow up.

Conclusion: Although ossifying lipomas are very rare, it is important to keep them in mind when a lesion with adipose tissue in combination with ossification is encountered.

Copyright © 2016, Dr Saikat Sau. This is an open access article distributed under the Creative Commons Attribution License, which permits unrestricted use, distribution, and reproduction in any medium, provided the original work is properly cited.

Citation: Dr Saikat Sau, 2016. "Osteolipoma of tibia a rare case report", *International Journal of Current Research*, 8, (04), 29821-29822.

INTRODUCTION

Lipomas are the most common benign soft-tissue tumors composed of only mature adipose cells without cellular atypia (Murphey *et al.*, 2004). Variants of lipoma have been named according to the type of tissue present such as fibrolipoma, myelolipoma, leiomyolipoma, chondrolipoma, osteolipoma and angioliopoma (Kransdorf *et al.*, 1991). A lipoma containing mature osseous elements is called osteolipoma. The terms ossifying lipoma, osseous lipoma and lipoma with osseous metaplasia have been used interchangeably with osteolipoma (Obermann *et al.*, 1999). Solitary lipomas are frequent, especially among adults. They can appear in any location of the body, but are usually found in the subcutaneous regions (Obermann *et al.*, 1999). Lipoma can be located in the intraosseous region or adjacent to bone and referred to as intraosseous, parosteal, or periosteal lipoma respectively. Those that are in such sites may contain osseous and or chondral components (Murphey *et al.*, 1994 Rodriguez-Peralto *et al.*, 1994). The differential diagnosis for an osseous containing mass in the soft tissue should cover heterotopic ossification, well-differentiated liposarcoma, osteochondroma, extra-osseous osteosarcoma, and soft tissue myxoid chondrosarcoma. Differentiating these lesions in all but heterotopic ossification, which has distinct imaging characteristics, can be very difficult and biopsy is often very helpful.

We present a rare case osteolipoma independent of bone tissue located in the leg.

Case presentation

A 30-year old, female present with painless swelling over left leg post- medial aspect. Clinically diffused margine 5cm-8cm mass, bony hard in concistency. No distal neovascular complication. Imaging features of osteolipoma are often pathognomonic but depend on the location of the lesion. Plain film X-rays are obtained first and yield a differential diagnosis of osteochondroma, lipoma with tumoral calcinosis, and myositis ossificans (Obermann *et al.*, 1999). However, similar findings may also be seen in calcified lipoma, ossifying fibroma, osteoma, enchondroma, as well as chondroblastoma or osteochondroma on computerized tomography.

It is important to obtain images with fat suppression to differentiate fat from other soft tissues on magnetic resonance imaging (Durmaz *et al.*, 2007). On Magnetic Resonance Imaging, a discrete, encapsulated, homogeneous fatty mass with similar signal intensity of the subcutaneous fat in all pulse sequences is most certainly a simple lipoma. The tumor consisted largely of mature adipose tissue with surrounded by a thin layer vascularized fibrous tissue. There was mature trabecular bone within the adipose tissue. We excise this mass. no recurrence after 12 months. Follow up.

*Corresponding author: Dr. Saikat Sau,
Department of Orthopedics, IPGMER SSKM Hospital, Kolkata West Bengal,
India.

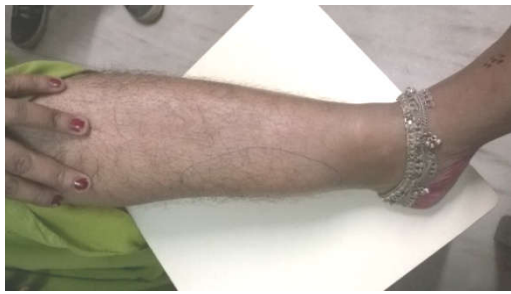

Figure 1.

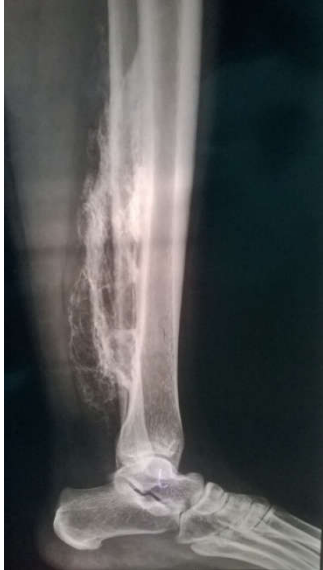

Fig. 2.

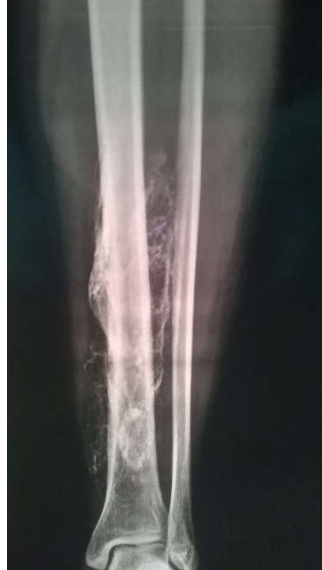

Fig. 3.

Fig. 2. and Fig. 3. Shows ossification of the postmedial mass.no cortical break

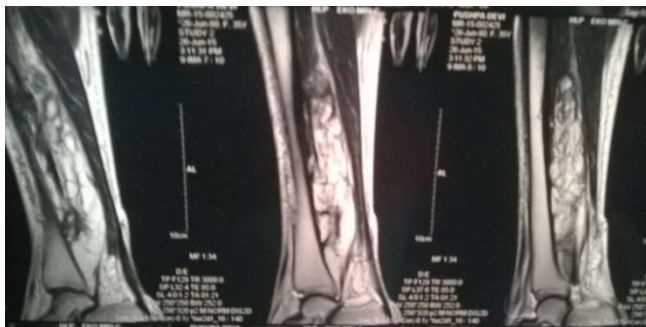

Figure 4. MRI of the leg,no cortical break,no intra medulary extention

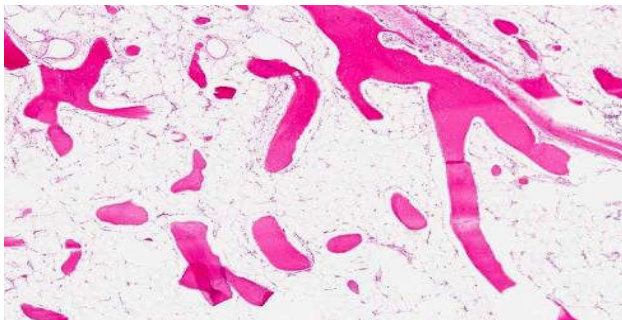


Fig. 5. Mature adipose tissue with surrounded by a thin layer vascularized fibrous tissue. There was mature trabecular bone within the adipose tissue

Conclusion

In conclusion, osteolipoma with independent bone is very rare. It has a characteristic radiological and pathological appearance. Osteolipoma is a benign condition has a same prognosis as simple lipoma and surgical excision is the recommended treatment. No recurrences have been reported.

REFERENCES

- Durmaz, A., Tosun, F., Kurt, B., Gerek, M., Birkent, H. 2007. Osteolipoma of the nasopharynx. *J Craniofac Surg.*, 18:1176-1179.
- Heffernan, E. J., Lefavre, K., Munk, P. L., Nielsen, T. O., Masri, B. A. 2008. Ossifying lipoma of the thigh. *Br J Radiology*, 81:e207-210.
- Jaiswal, A. K., Garg, A., Mahapatra, A. K. 2005. Spinal ossifying lipoma. *J Clin Neurosci.*, 12:714-717.
- Kransdorf, M. J., Moser, R. P. Jr, Meis, J. M., Meyer, C. A. 1991. Fat-containing soft tissue masses of the extremities. *Radiographics*, 1991, 11:81-106.
- Murphey, M. D., Carroll, J. F., Flemming, D. J., Pope, T. L., Gannon, F. H., Kransdorf, M. J. 2004. From the archives of the AFIP: Benign musculoskeletal lipomatous lesions. *Radiographics*, 24:1433-1466.
- Murphey, M. D., Johnson, D. L., Bhatia, P. S., Neff, J. R., Rosenthal, H. G., Walker, C. W. 1994. Parosteal lipoma: MR imaging characteristics. *AJR Am J Roentgenol*, 162:105-110.
- Obermann, E. C., Bele, S., Brawanski, A., Knuechel, R. 1999. Hofstaedter F: Ossifying lipoma. *Virchows Arch.*, 434:181-183.
- Rodriguez Peralto, J. L., Lopez-Barea, F., Gonzalez-Lopez, J., Lamas-Lorenzo, M. 1994. Case report 821: Parosteal ossifying lipoma of femur. *Skeletal Radiol.*, 23:67-69.
- Turkoz, H. K., Varnali, Y., Comunoglu, C. 2004. A case of osteolipoma of the head and neck area. *Kulak Burun Bogaz Ihtis Derg.*, 13:84-86.
- Val-Bernal, J. F., Val, D., Garijo, M. F., Vega, A., Gonzalez-Vela, M. C. 2007. Subcutaneous ossifying lipoma: Case report and review of the literature. *J Cutan Pathol.*, 34:788-792.
- Yabe, Y., Kumagai, J., Koizumi, N., Kawamura, M., Ono, S., Hatori, M. 2006. Lipoma arising adjacent to the sternoclavicular joint. A case report. *Ups J Med Sci.*, 111:257-261.
- Yang, T. H., Fong, Y. C., Hsu, H. C., Jim, Y. F., Chiang, I. P., Lin, M. J. 2008. Re: Ossifying lipoma of the hand. *J Hand Surg Eur.*, Vol., 33:82-83.
