



REVIEW ARTICLE

A NOVEL PROCEDURE TO PROCESS EXTRACTED TEETH FOR IMMEDIATE GRAFTING AS AUTOGENOUS DENTIN IN COMBINED ENDO-PERIO LESIONS- A CASE SERIES

*Dr. Cherry Chamria, Dr. Roshani Thakur and Dr. Arvind Shetty

D.Y. Patil University, School of Dentistry, India

ARTICLE INFO

Article History:

Received 07th March, 2016
Received in revised form
07th April, 2016
Accepted 28th May, 2016
Published online 15th June, 2016

Key words:

Natural Tooth,
Autogenous Bone Grafting,
Combined Endo-Perio Lesion,
Guided Tissue Regeneration.

ABSTRACT

Background: Endodontic-periodontal combined lesion is a clinical dilemma because making a differential diagnosis and deciding a prognosis are difficult. Lesions of the periodontal ligament and adjacent alveolar bone may originate from infections of the periodontium or tissues of the dental pulp. Peri-radicular bone loss secondary to endodontic pathosis is typically seen in teeth with necrotic pulps. The ultimate goal of periodontal therapy is not only to maintain the natural dentition, but also to restore lost periodontium. Combined periodontal and endodontic diseases involve the periodontal attachment apparatus. The treatment of endodontic-periodontal combined lesions requires both endodontic therapy and periodontal regenerative procedures. With advancements in new techniques and materials different treatment choices are available, providing a superior prognosis. This article includes case reports of combined endo-periolesions which were first treated with conventional endodontic therapy and then followed by periodontal surgery. This combined treatment resulted in a radio graphical evidence of alveolar bone gain. This case report demonstrates that proper diagnosis, followed by removal of etiological factors and utilizing the combined treatment modalities will restore health and function to the teeth with severe attachment loss caused by an endo-perio lesion. Extracted teeth are considered a clinical waste and therefore being discarded. It is evident that the clinical composition of dentin is similar to bone. The method for regeneration of the periodontal apparatus in the below given case series used extracted teeth from the respective patients.

Aim: To manage the endodontic periodontal lesion with Grade 2 mobility using natural tooth as bone graft.

Case description: 3 cases with combined endodontic periodontal lesion were explained. The appropriate management and outcome for each case was elaborated and justified.

Discussion: In all the 3 cases, patient presented with established chronic secondary disease. Hence all the cases were planned to complete the endodontic therapy initially and then were preceded with periodontal therapy such as open flap debridement and bone graft. For these cases, autogenous bone graft using patients natural tooth was used.

Conclusion: Treatment outcome found with 9 monthly follow-up was satisfactory. Mobility was reduced from grade 2 to almost no mobility. The radiographic changes were appreciable.

Copyright©2016, Dr. Shweta Bali et al. This is an open access article distributed under the Creative Commons Attribution License, which permits unrestricted use, distribution, and reproduction in any medium, provided the original work is properly cited.

Citation: Dr. Cherry Chamria, Dr. Roshani Thakur and Dr. Arvind Shetty, 2016. "A novel procedure to process extracted teeth for immediate grafting as autogenous dentin in combined endo-perio lesions- a case series", *International Journal of Current Research*, 8, (06), 32592-32596.

INTRODUCTION

Preservation of the natural dentition is the ultimate goal of dental therapy. In periodontics, the goal is not only to maintain the natural dentition, but also to restore lost periodontium. Lesions of the periodontal ligament and adjacent alveolar bone may originate from infections of the periodontium or tissues of dental pulp. Peri-radicular bone loss secondary to endodontic pathosis is typically seen in teeth with necrotic pulps. Combined periodontal and endodontic diseases involve the periodontal attachment apparatus. Pulpal necrosis may lead to destruction of the attachment apparatus by extension through the apical foramen or through accessory canals that may be located at different levels on the root surface.

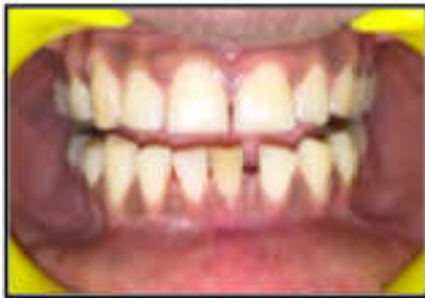An acceptable treatment results, for combined endodontic and periodontal (endo-perio), lesions may be obtained by endo-perio therapy. However, when a significant loss of the periodontal attachment apparatus and osseous structure occurs, the long-term prognosis becomes poor. Tooth extraction is one of the most widely performed procedures in dentistry and it has been historically well documented that this may induce significant dimensional changes of the alveolar ridge. In this review, Horowitz *et al.* (2012) stated that less ridge resorption is occurring when alveolar ridge preservation procedures were used versus the placement of no graft material in fresh alveolar sockets. If performed inadequately, the resulting deformity can be a considerable obstacle to the esthetic, phonetic, and functional results. In dentistry allogeneic bone and synthetic mineral materials are the main source for grating in bone.

*Corresponding author: Cherry Chamria,
D.Y. Patil University, School of Dentistry, India.

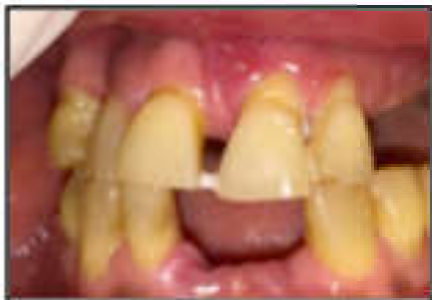However, fresh autogenous bone graft is still considered gold standard since it exhibits bioactive cell instructive matrix properties and is non-immunogenic and non – pathogenic in spite of the need for harvesting bone and possible morbidity resulting from it. It is well known that jaw bones, alveolar bone and teeth develop from cells of the neural crest and that many proteins are common to bone, dentin, and cementum (Donovan *et al.*, 1993; Qin *et al.*, 2002). It is therefore not surprising that dentin that comprise of more than 85% of tooth structure can serve as native bone grafting material. Interestingly, Schmidt-Schultz and Schultz (Schmidt-Schultz and Schultz, 2005) found that intact growth factors are conserved even in the collagenous extracellular matrix of ancient human bone and teeth. Currently, all extracted teeth are considered a clinical waste and therefore are simply discarded. This report presents a total of 3 cases with combined endo-perio lesions and chief complaint of Grade 2 mobility. It was treated first with conventional endodontic therapy and followed using combined periodontal regenerative procedure.

Case Reports

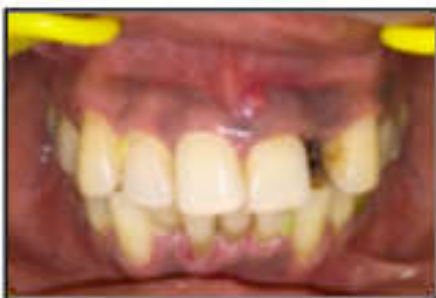Case 1:



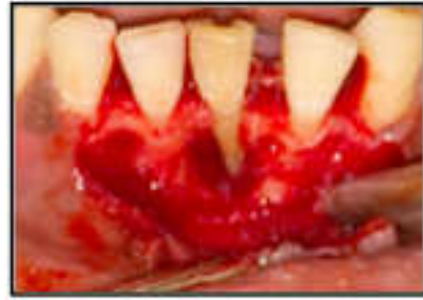Case 1. Preoperative



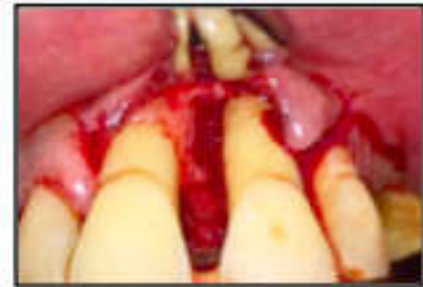Case 2. Preoperative



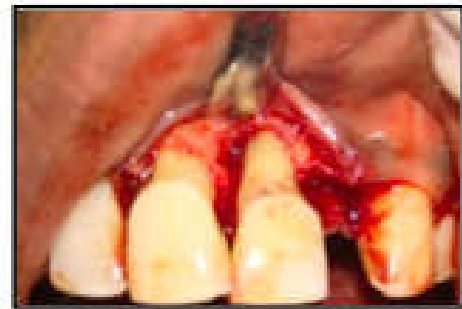Case 3. Preoperative



Case 1. Defect



Case 2. Defect

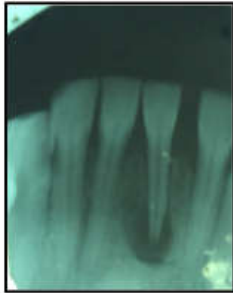


Case 3. Defect

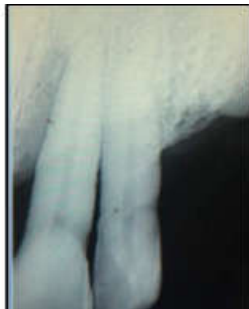A 34-year old male presented to the Dept. Of Periodontology and Implantology, D.Y Patil University, School of Dentistry, Navi Mumbai, with the chief complaint of pus discharge & mobile lower anterior tooth. The buccal gingiva showed sinus opening in relation to 41. He was systemically healthy and medical history was not contributory to this dental problem. On clinical examination, probing depth was 12mm on buccal aspect of 41 was seen. Mobility was grade II. The buccal gingiva showed slight swelling and clear signs of inflammation. The teeth did not respond to percussion and palpation tests. It neither responded to the electrical pulp test nor thermal tests. Periapical radiograph showed a deep bony defect extending to root apex of 11, 21, in addition to the periapical radiolucency. Initial diagnosis was pulp necrosis and asymptomatic apical periodontitis, and the teeth were thought to have primary endodontic involvement. However, the pattern of periodontal bone loss, with a wide base, coupled with generalized marginal periodontitis, suggested that there was also primary periodontal involvement in this case. Therefore, considering the dental history, clinical tests and radiographs, the diagnosis of this case was an endodontic-periodontal combined lesion, according to Simon classification 1972 (Simon *et al.*, 1972).

First conventional root canal treatment was done, which was followed by periodontal surgery after 1 month. After local anesthesia, a Kirkland flap was raised from distal 33 to distal of 43. After raising the flap, severe osseous destruction was observed on facial surface of 41. The buccal root surface and the apical area were root planed. After thorough root planing and apical curettage, the large osseous defect was filled in a presutured flap with autogenous natural tooth graft prepared a few minutes before surgery, chairside, covering the root surface. The flap was repositioned and interrupted suturing was done with nonresorbable 3-0 silk suture material. Antibiotics and analgesics were prescribed for 1 week. Patient was monitored on weekly schedule postoperatively, to ensure good oral hygiene in the surgerized area. Supportive periodontal maintenance at 3 months was prescribed to maintain periodontal health and to re-evaluate this area. At 9-month recall, the teeth were asymptomatic with successful healing, mobility was reduced to less than grade I and probing depth was minimal. The radiograph after 9 month follow-up, showed evidence of apparent bone fill with resolution of the osseous defect.

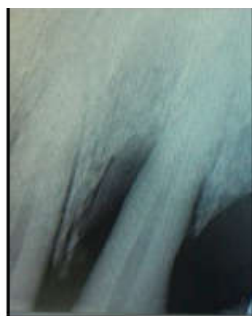Case 2



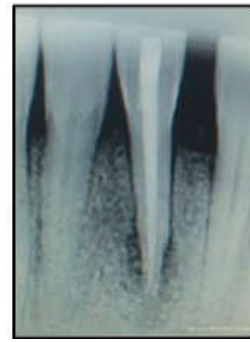
Case 1. Preoperative



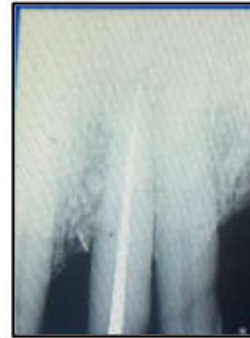Case 2. Preoperative



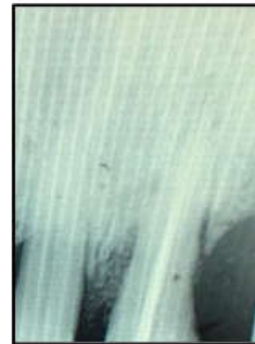
Case 3. Preoperative



Case 1.1 year recall



Case 2.1 year recall



Case 3.1 year recall

A 62 old male presented to the Dept. Of Periodontology and Implantology, D.Y Patil University, School of Dentistry, Navi Mumbai, with chief complaint of mobile upper anterior tooth. He had no contributory medical history. On clinical examination, probing depth on mesial aspect of the tooth was 11mm, mobility was grade II. The tooth did not respond to percussion and palpation tests. The tooth was non responsive to pulp vitality tests. Periapical radiograph showed radiolucency to the lateral of the root of tooth 21. Therefore, considering the dental history, clinical tests, and radiographs, the diagnosis was combined endodontic-periodontal lesion, according to Simon classification 1972 (Simon, 1972). First conventional root canal treatment was done and after 1 month periodontal surgery was performed. After local anesthesia, a full thickness mucoperiosteal flap was raised. After raising the flap, a 3-walled osseous defect was observed on distal surface of tooth 21. After thorough root planing and curettage, the defect was filled with autogenous natural tooth graft prepared a few minutes before surgery chairside covering the root surface.

The flap was repositioned and interrupted suturing was done with nonresorbable 3-0 silk suture material. Postoperative evaluation was done same as in previous case. At 1-yr recall, radiograph showed evidence of apparent bone fill with resolution of the osseous defect.

Case 3

A 42 old male presented to the Dept. Of Periodontology and Implantology, D.Y Patil University, School of Dentistry, Navi Mumbai, with chief complaint of mobile upper anterior tooth. He had no contributory medical history. On clinical examination, probing depth on mesial aspect of the tooth was 9mm, mobility was grade II. The tooth did not respond to percussion and palpation tests. The tooth was non responsive to pulp vitality tests. Periapical radiograph showed radiolucency to the lateral of the root of tooth 21. Therefore, considering the dental history, clinical tests, and radiographs, the diagnosis was combined endodontic-periodontal lesion, according to Simon classification 1972 (Simon *et al.*, 1972). First conventional root canal treatment was done and after 1 month periodontal surgery was performed. After local anesthesia, a mucoperiosteal flap was raised. After raising the flap, severe 3-wall osseous destruction was observed on distal surface of tooth 21. After thorough root planing and curettage, the defect was filled with autogenous natural tooth graft prepared a few minutes before surgery chairside covering the root surface. The flap was repositioned and interrupted suturing was done with nonresorbable 3-0 silk suture material. Postoperative evaluation was done same as in previous case. At 1-yr recall, radiograph showed evidence of apparent bone fill with resolution of the osseous defect.

DISCUSSION

Endodontic-periodontal lesion is a clinical manifestation of the pathologic/inflammatory intercommunication between pulpal and periodontal tissues via open structures such as apical foramina, lateral, accessory canals, and dentinal tubules. (5) On the basis of the pathologic origin, Simon *et al.* (1972) classified endodontic- periodontal lesions into primary endodontic lesions, primary endodontic lesions with secondary periodontic involvement, primary periodontic lesions, primary periodontic lesions with secondary endodontic involvement, or true combined lesions. Bone loss secondary to pulpal pathosis is believed to result from the spread of inflammatory irritants from the pulp to the periodontal ligament (Barkhordar and Stewart, 1990). The treatment of endodontic- periodontal combined lesions requires both endodontic therapy and periodontal regenerative procedure, as discussed in this case report. The goal of periradicular surgery is to remove all necrotic tissues from the surgical site, to completely seal the entire root canal system, and to facilitate the regeneration of hard and soft tissues including the formation of a new attachment apparatus (Karabucak and Setzer, 2009). The most common clinical/radiographic features of these endodontic-periodontal lesions reported were the periapical advanced bone loss caused by periodontal disease is usually irreversible (Law and Beaumont, 2004). The necessity of periodontal surgical therapy most likely was because the periodontal bone loss was more advanced and was less likely to resolve after non surgical root canal therapy alone.

In this case report, root canal debridement and removal of granulation tissue around the root and apex was done, without subsequent root resection and retrograde filling. However, periradicular curettage was the sole procedure for the following reasons: (a) periapical curettage is able to remove the granulation tissue without root resection (Zehnder *et al.*, 2002); (b) there is no difference in healing with curettage alone or curettage with root-end resection more dentinal tubules may remain open after root-end resection, allowing more contaminants to leak out through the tubules. More than 40 years ago, autogenous teeth were routinely transplanted into extraction sockets when possible. It is evident that transplanted teeth that are ankylosed in jaw bone undergo replacement resorption by bone, during 5-8 years (Sperling *et al.*, 1986). In addition, it is well documented that avulsed teeth that are implanted back into their sockets undergo firm reattachment by bone which is formed directly on root dentin or cementum, leading to ankylosis (Andersson *et al.*, 1989). An ankylosed root is continuously resorbed and replaced by bone, eventually resorbing the entire root, while the alveolar process is preserved during this period and later. In a recent review, Malmgren (2013) stressed that ankylosed teeth that are treated by decoronation, the alveolar ridge is maintained in the buccal/palatinal direction, while vertical height is even increased (Park *et al.*, 2007).

Our results reveal similar interaction between mineralized dentin and osteogenic cells that attach and produce mineralized bone matrix directly on the dentin graft. However, from clinical and radiographic findings, the result of this technique was quite impressive, resulting in a significant reduction of probing depth and bone fill. Selecting a defect that is amenable to regeneration is also critical for achieving success. This is also true for an endodontic defect. Some of the patient factors that might contribute to positive outcome includes the good plaque control, compliance, nonsmoking, anti-infective therapy and systemic health. Other factors that might also negatively affect the healing process include occlusal trauma, improper surgical technique (such as excessive flap tension), early mechanical disruption, and contamination during surgery. Wang and Boyapati (Wang and Boyapati, 2006) suggested 4 factors, the so-called PASS principle, that are critical for predictable bone regeneration: primary wound closure, angiogenesis as a blood supply and source of undifferentiated mesenchymal cells, space maintenance, and stability of the wound. Space maintenance involves the creation of space for periodontal tissues to grow into; which was achieved in these cases with a bone graft.

Conclusion

Although traditional nonsurgical periodontal therapy and regular endodontic therapy can be predictably used to arrest mild to moderate defects, it might be inadequate for the treatment of disease characterized by deep pockets or wide circumferential apical defects. Currently, regenerative techniques are widely available in terms of their predictability to regenerate the lost tissue/bone in all types of defects or for all situations. A careful preoperative diagnosis, appropriate case selection and knowledge of the factors that can negatively affect regeneration outcomes can help to optimize successful regenerative attempts.

Treatment strategies used in this case report suggests that combined endodontic-periodontal lesions can be successfully managed with multiple regenerative procedures. Teeth and jawbone have a high level of affinity, having similar chemical structure and composition. Therefore, we (Zehnder *et al.*, 2002; Sperling *et al.*, 1986) propose that extracted non-functional teeth or periodontally involved teeth should not be discarded anymore. Extracted teeth can become an autogenous dentin ready to be grafted within 15 minutes after extraction. It can also be stored indefinitely. We consider autogenous dentin as the gold standard graft for socket preservation, bone augmentation in sinuses or filling bone defects.

REFERENCES

- Andersson, L., Bodin, I. and Sörensen, S. 1989. Progression of root resorption following replantation of human teeth after extended extraoral storage. *Endod Dent Traumatol.*, 5: 38-47.
- Barkhordar, R.N., Stewart, G.G. 1990. The potential of periodontal pocket formation with untreated accessory root canals. *Oral Surg Oral Med Oral Pathol Oral RadiolEndod*, 70:769-72.
- Donovan MG, Dickerson NC, Hellstein JW, Hanson LJ. 1993. Autologous calvarial and iliac onlay bone grafts in miniature swine. *J Oral MaxillofacSurg.*, 51: 898-903.
- Horowitz R, Holtzclaw D, Rosen PS. 2012. A review on alveolar ridge preservation following tooth extraction. *J Evid Based Dent Pract* 12: 149-160.
- Karabucak, B. and Setzer, F.C. 2009. Conventional and surgical retreatment of complex periradicular lesions with periodontal involvement. *J Endod.*, 35:1310-5.
- Law, A.S., Beaumont, R.H. 2004. Resolution of furcation bone loss associated with vital pulp tissue after nonsurgical root canal treatment of three- rooted mandibular molars: A case report of identical twins. *J. Endod.*, 30:444-7.
- Malmgren, B. 2013. Ridge preservation/decoronation. *J Endod* 39: S67-72.
- Meng HX. 1999. Periodontic-endodontic lesions. *Ann Periodontol.*, 4:84-90.
- Park, C.H.1, Abramson, Z.R., Taba, M. Jr, Jin, Q., Chang, J. *et al.* 2007. Three- dimensional micro-computed tomographic imaging of alveolar bone in experimental bone loss or repair. *J Periodontol.*, 78: 273-281.
- Qin C, Brunn JC, Cadena E, Ridall A, Tsujigiwa H, *et al.* 2002. The expression of dentin sialophosphoprotein gene in bone. *J Dent Res.*, 81: 392-394.
- Schmidt-Schultz TH, Schultz M 2005. Intact growth factors are conserved in the extracellular matrix of ancient human bone and teeth: a storehouse for the study of human evolution in health and disease. *BiolChem.*, 386: 767-776.
- Simon JH, Glick DH, Frank AL. 1972. The relationship of endodontic- periodontic lesions. *J Periodontol.*, 43:202-8.
- Sperling, I., Itzkowitz, D., Kaufman, A. and Binderman, I. 1986. A new treatment of heterotransplanted teeth to prevent progression of root resorption. *Endod Dent Traumatol.*, 2: 117-120.
- Wang, H.L. and Boyapati, L. 2006. "PASS" principles for predictable bone regeneration. *Implant Dent*, 15:8-17.
- Zehnder, M., Gold, S.I. and Hasselgren, G. 2002. Pathologic interactions in pulp and periodontal tissues. *J Clin Periodontol.*, 29:663-71.
