



CASE STUDY

OSSIFYING FIBROMA: A RARE CASE REPORT

^{*}¹Pradkshana Vijay and ²Dr. Nilesh Pardhe

¹Department of Oral Pathology and Microbiology, Faculty of Dental Sciences, KGMU Lucknow

²Department of Oral Pathology and Microbiology, NIMS Dental College Jaipur

ARTICLE INFO

Article History:

Received 19th July, 2016
Received in revised form
25th August, 2016
Accepted 15th September, 2016
Published online 30th October, 2016

Key words:

Histology, Radiograph, Case report, Swelling.

Copyright © 2016, Pradkshana Vijay. This is an open access article distributed under the Creative Commons Attribution License, which permits unrestricted use, distribution, and reproduction in any medium, provided the original work is properly cited.

Citation: Pradkshana Vijay, 2016. "Ossifying fibroma: A rare case report", *International Journal of Current Research*, 8, (10), 40708-40710.

ABSTRACT

Ossifying fibromas (OF) form an array of fibro-osseous lesions of the jaw. These are quite rare and benign tumors which are non-odontogenic in origin. They are commonly seen in the head and neck region. Ossifying fibroma of maxilla is an uncommon entity. We present a case of ossifying fibroma in the posterior maxillary region of a 55 years old female patient with brief discussion of review of literature of the lesion.

INTRODUCTION

Ossifying fibromas is a fibro-osseous lesion arising from periodontal membrane. (Suarez *et al.*, 2013) This lesion is limited to head and neck region. (Kramer *et al.*, 1992) It is known by other names also like fibro-osteomas or osteofibroma benign fibro-osseous lesion. The term ossifying fibromas was coined by Montgomery in 1927, while the first description was made by Menzel in 1872. (Menzel, 1872) It usually presents as a slow growing, painless, expansible bony lesion. Most common site of involvement is mandible and females in the age group of 35-45 years. (Montgomery, 1972) Lesion is mostly asymptomatic, but growth leads to swelling with displacement and mobility of teeth in affected region. (Speight and Carlos, 2006) We report a rare case of ossifying fibromas in posterior maxillary region of a middle aged female patient.

Case report

A 55 years old female patient presented with chief complaint of swelling in upper left back tooth region of the jaw since 1yr. Patient noticed the swelling 1year back, when it was small in size on the side of the gingiva of left upper back tooth. Now the swelling has increased to the a considerable size causing obliteration of posterior molar teeth. Intraoral inspectory findings revealed a large, well defined, solitary, nodular growth, measuring 2x2cm with smooth and regular surface and

same colour as that of overlying mucosa involving attached gingiva irt 27, 28 region both buccally and palatally and extending anteriorly towards distal margin of 27 and posteriorly towards maxillary tuberosity region. (Fig. 1) Palpatory findings of lesion revealed a solitary swelling which was non tender, non pulsatile without any raise in temperature. Consistency of the swelling was bony hard. Lesion was non Fluctuant and non- compressible. On probing, through distal of 27, mild bleeding was present and some hard material was felt, suspected to be root stump i.r.t 28. Radiographic findings of maxillary arch using axial section of CT scan showed hyperdense shadow secondary to reactive (Dysplastic) bone formation which was measuring around 23.9mm x 13.0mm in maximum dimension. Cystic spaces with specks of calcification giving a ground glass pattern were noted. (Fig. 2) Hounsfield unit of lesion was slightly lower than normal trabecular cancellous pattern indicating that normal bone was replaced by fibrous connective tissue which was suggestive of fibro osseous lesion. On the basis of clinico-radiographic findings a provisional diagnosis of fibro-osseous lesion was made.

An incisional biopsy was performed and tissue was examined histopathologically using hematoxylin and eosin stain which revealed a fibrocellular connective tissue stroma consisting of bundles of collagen fibres, calcification in form of bony trabeculae with osteoblastic rimming, few spherules of ossifications and extravasated RBC's. (Fig. 3) The overall Histopathological features were suggestive of ossifying fibroma. Lesion was approached intraorally under local

*Corresponding author: Pradkshana Vijay,

Department of Oral Pathology and Microbiology, Faculty of Dental Sciences, KGMU Lucknow

anaesthesia. Complete lesion was excised (enucleation) surgically by raising mucoperiosteal flap with extraction of 27, 28 followed by suture closure. Patient was on regular follow up without any post operative complications.

DISCUSSION

OF of maxilla is a rare neoplasm with only 30% of involvement of cases. (Speight and Carlos, 2006) It is a well

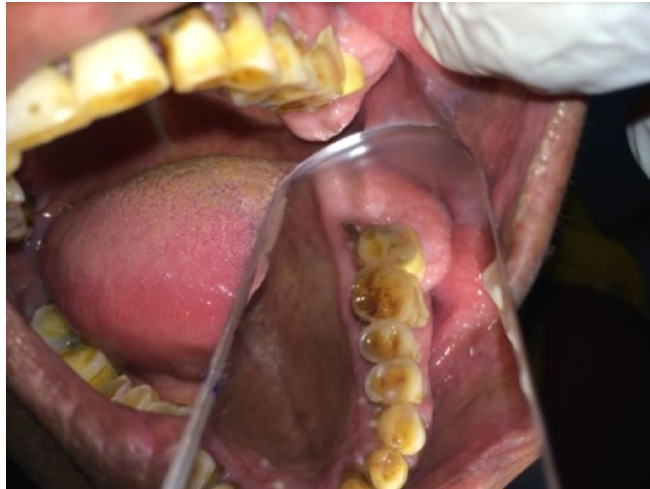

Fig. 1. Intraoral examination reveals a well defined solitary tumor mass involving the posterior left maxilla irt 27, 28

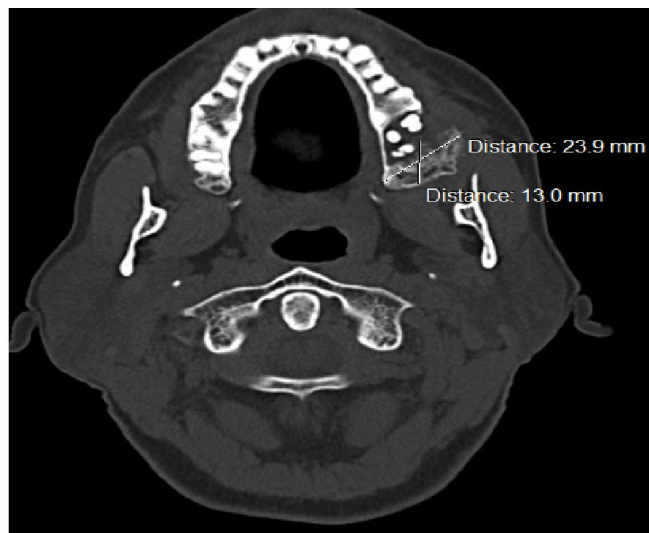

Fig. 2. CT scan shows mixed lesion involving the left posterior maxilla showing a ground glass pattern

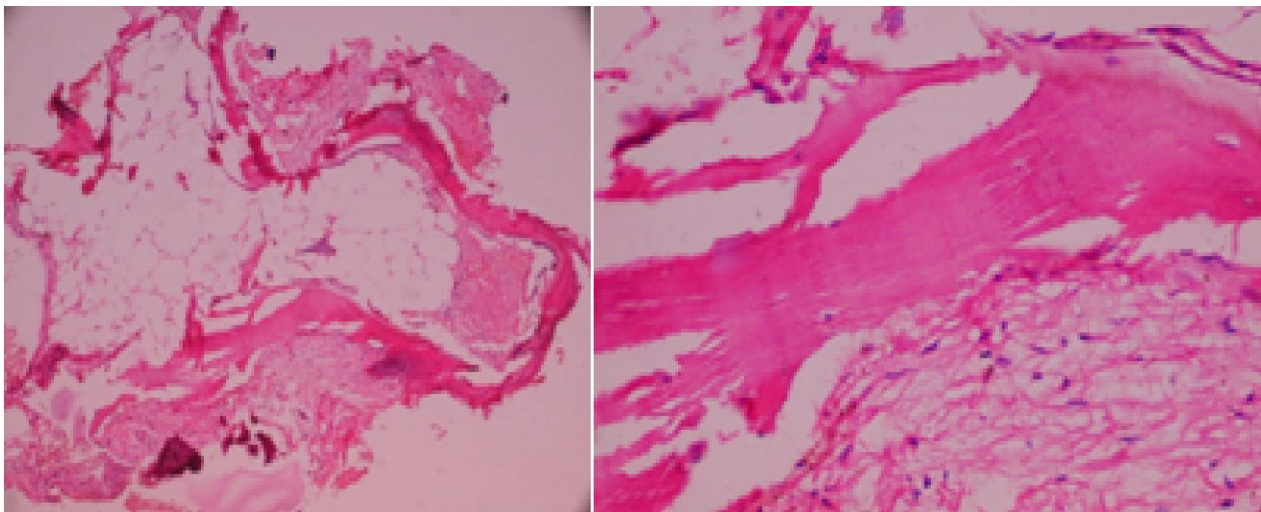


Fig. 3. Photomicrograph reveals loose fibrocellular stroma with calcification in the form of bony trabeculae lined by osteoblasts. Also normal adipose tissue and few engorged and proliferating blood vessels with endothelial lining are noted

defined tumor with clear cut margins. Maxillary lesions are large at the time of presentation, with the capacity to expand and displace the anatomical structures. (Regeizzi and Scuibba, 1999) Mostly occurs in third and fourth decade of life with female predilection. (Eversole *et al.*, 1985) The present case was reported in a 55 years old female patient involving the left posterior maxilla which is a quite rare site of involvement of this tumor. Radiographically, it presents as well-defined mixed density lesion. These lesions have well-defined borders with marginal sclerosis. Lesions in maxilla show ground glass appearance which was present in our case. (Liu *et al.*, 2010) Radiographic differential diagnosis includes fibrous dysplasia, squamous cell carcinoma, sarcoma, calcifying odontogenic cyst (COC) and pindborg's tumor. Well defined borders of OF differentiate it from sarcoma and carcinomas. Pindborg's tumor and COC pose difficulty in diagnosis and are identified histologically. Fibrous dysplasia shows a typical ground glass appearance on radiograph. (Delilbasi *et al.*, 2009) Histologically, the OF are well circumscribed, infrequently encapsulated lesion. They present a fibrocellular stroma with bony trabeculae lined with osteoblasts. The fibrocellular stroma may also show spherules of calcified material resembling cementum or bone. (Delilbasi *et al.*, 2009) Histological differential diagnosis includes fibrous dysplasia, cemento-osseous dysplasia and osteoblastoma. Fibrous dysplasia shows monotonous and curvilinear pattern of bony trabeculae without having osteoblastic rimming which is known as Chinese letter pattern. In case of cemento-osseous dysplasias, thin curvilinear bony trabeculae resembling ginger roots are seen. The cementum like particles is irregular and shows retraction from the stroma. Osteoblastoma shows plump, hyperchromatic osteoblasts which line the bony trabeculae, and multinucleated giant cells are present in the stroma. (Neville *et al.*, 2002) OF is treated mostly by complete surgical excision along with the site of involvement. Recurrence is around 28% in cases involving mandible. (Sanchis *et al.*, 2003) It can be more in maxilla due to large size of lesion and difficulty in surgical excision.

Conclusion

OF are rare benign tumors of oral cavity. These are clinically asymptomatic and are noted mostly at later stage when they

attain a larger size causing tooth displacement and mobility. Radiography plays an important role in diagnosis and management of these lesions.

REFERENCES

- Delilbasi C, Sencimen M, Okcu KM. 2009. A large mass in the maxilla: Clinical features and differential diagnosis. *J Can Dent Assoc.*, 75:269,272-3.
- Eversole LR, Leider AS, Nelson K. 1985. Ossifying fibroma: A clinicopathologic study of sixty-four cases. *Oral Surg Oral Med Oral Pathol.*, 60:505-11.
- Kramer IRH, Pindborg JJ, Shear M. 1992. Neoplasm and other lesions related to bone. In: WHO Histologic typing of odontogenic tumours. Berlin, Springer-Verlag, pp 28–31
- Liu Y, Wang H, You M, Yang Z, Miao J, Shimizutani K, *et al.* 2010. Ossifying fibromas of the jaw bone: 20 cases. *Dentomaxillofac Radiol.*, 39:57-63.
- Menzel A. 1892. A failed case of osteofibroma of the corpus mandible. *Arch Klin Chir.*, 13:212.
- Montgomery AH. 1972. Ossifying fibromas of the jaws. *Arch Surg.*, 15:30.
- Neville, B. W., D. D. Damm, C. M. Allen, and J. E. Bouquet, 2002. *Oral and Maxillofacial Pathology*, Elsevier, New York, NY, USA, 2nd edition.
- Regeizzi JA. and Scuibba JJ. 1999. Oral Pathology — Clinical Pathologic Correlations. 3rd ed. Philadelphia, PA, Saunders, p. 57-360.
- Sanchis JM, Pennarrocha M, Balaguer JM, Camacho C. 2003. Cemento-ossifying fibroma of the mandible: A presentation of two cases and a review of literature. *Med Oral.*, 9:69–73.
- Speight, P. M. and R. Carlos, 2006. "Maxillofacial fibro-osseous lesions," *Current Diagnostic Pathology*, 12(1): pp. 1–10.
- Suarez-S A, Baquero-Ruiz de la Hermosa MC, Minguez-M I, Floría-García LM, Barea-Gámiz J, Delhom-Valero J, Risueño-Mata P. 2013. Management of fibro-osseous lesions of the craniofacial area. Presentation of 19 cases and review of the literature. *Med Oral Patol Oral Cir Bucal.*, 18:e479-85.
